



Received on 11 May, 2017; received in revised form, 02 August, 2017; accepted, 11 August, 2017; published 01 February, 2018

MORPHOLOGICAL STUDY OF MIDDLE CRANIAL FOSSA AND ITS VARIATIONS

P. K. Sankaran*, Gunapriya Raghunath, Rohini Arathala, Karthikeyan, Menaka, Madhumitha, M. Yuvaraj and M. Kumaresan

Department of Anatomy, Saveetha Medical College, Thandalam, Chennai - 602105, Tamil Nadu, India.

Keywords:

Foramina-Middle cranial fossa, Foramen rotundum, Foramen lacerum, Foramen ovale, Foramen spinosum, Carotid canal, Foramen of vesalius

Correspondence to Author:

Dr. P. K. Sankaran

Associate Professor,
Department of Anatomy,
Saveetha Medical College,
Thandalam, Chennai - 602105,
Tamil Nadu, India.

E-mail: drpks@live.com

ABSTRACT: Purpose: To study the morphological details and analyse the morphometry of the various foramina in the dry human skulls of mainly Indian population. **Materials and Methods:** 64 dry skulls of unknown sex and of Indian origin were used in this study which was carried out at the Department of Anatomy and forensic department of Saveetha Medical College and Hospital in the year 2016. The parameters used were incidence, longitudinal diameter, transverse diameter, distance from midline, distance from petrous apex, and distance between right and left foramen. **Result:** The mean sizes of the foramen ovale on the right and left sides were 7.45 x 1.1 mm and 7.61 x 1.15 mm. We found that completely ossified pterygospinous ligament passed immediately inferior to the foramen ovale and also presence of bony septa within the foramen. The foramen spinosum was present bilaterally in 90% of the skulls. The mean sizes on the right and left sides were 2.54 x 0.8 mm and 1.97 x 0.7 mm. Foramen Vesalius is one of the most inconsistent foramina of the skull. In this present study this foramen was present in only 25% of the studied skulls. The measured mean longitudinal and transverse diameters optic canal were 5.21, 4.64(mm). **Conclusion:** Results shows comparison of mean and standard deviation of maximum dimensions of the right and left sided foramina of the middle cranial fossa. No statistically significant differences between both sides were observed except the carotid canal. The results of this study can be helpful for anatomists and surgeons who approach the middle cranial fossa for various procedures.

INTRODUCTION: Middle cranial fossa is the center most of the three fossae in the base of skull. It lodges the temporal lobes of the cerebral hemispheres and pituitary gland. It is formed by the body and greater wing of sphenoid bone, part of temporal bone, parts of the parietal bone. Though this fossa is structurally very complicated it is interesting to explore it.

The base of the skull has many foramina which provide communication between extra-cranial and intracranial structures through the blood vessels and nerves passing through it. The greater wing of the sphenoid has three consistent foramina. These are foramen ovale, foramen spinosum, foramen rotundum. The foramen rotundum (FR) is situated just below and behind the medial end of the superior orbital fissure and leads forwards into the pterygopalatine fossa, to which it transmits the maxillary nerve. Posterolateral to the foramen rotundum (FR) is the foramen ovale (FO) which transmits the mandibular nerve. Behind the FO is the foramen spinosum (FS), which transmits the middle meningeal artery¹.

QUICK RESPONSE CODE 	DOI: 10.13040/IJPSR.0975-8232.9(2).693-01
	Article can be accessed online on: www.ijpsr.com
DOI link: http://dx.doi.org/10.13040/IJPSR.0975-8232.9(2).693-01	

Apart from these foramina the base of the skull has various foramina like Foramen of Vesalius, Canaliculus innominatus, foramen lacerum, carotid canal, optic canal and two small canaliculi named as mastoid and tympanic canaliculi. The dimensions of the foramina and variations in the same are clinically significant in view of the delicate neurovascular structures that traverse them².

The present study focused on various foramina of the base of the skull with its dimensions and their distances from the median plane and petrous apex, and also occurrence of accessory foramina. Since these foramina act as a gateway for certain neurovascular structures study of base of the skull has an important role in view of its clinical significance. Any trauma or space-occupying lesion in this area would result in compressive forces, with the resulting clinical manifestations. Moreover, knowledge of the variations in the foramina would guide clinicians towards a correct interpretation of radiographs and would be of help in surgical approaches in this complicated region.

METHODS AND MATERIAL: In our study, 64 dry adult skulls were used which were obtained from the Anatomy department and Forensic Department of Saveetha Medical College, Thandalam, Chennai. All skulls used were of same native origin. Damaged skulls were omitted from the study. Vernier Caliper was used to measure the diameters of the foramina. Each dimension was measured thrice and the mean figure recorded. The foramina were measured by its long axis and the short axis. The distance from the midline of the skull to various foramina and from petrous apex to the various foramina was measured. Also, the distance between the right and left foramina were also measured. In case of any significance, such as the foramen being absent was also noted.

Statistical Analysis: The final result has been presented in the form of a mean and standard

deviation taking into consideration all the possibilities. The obtained data has been presented in tabular form. Comparisons have been made by measuring the various foramina on the right and left sides of the middle cranial fossa along with the distance between them in a single skull. Significance of the values was considered by taking multiple measurements, cross checking, and the large number of skulls measured. The results were compared with those of similar records in available literature. Photographs of any special variations in the foramina were taken for documentation.

RESULTS: After compiling the observations and using SPSS software, the following results were obtained, which were arranged in tabular form. Results show comparison of mean and standard deviation of maximum dimensions of right and left sided foramina of middle cranial fossa. No statistically significant differences between sides were observed except carotid canal.

Foramen Ovale: In the present study we observed foramen ovale was bilaterally present in all skulls. Its dimensions were arranged in tabular form. Most of the foramen ovale were oval in shape in 2 skulls the shape was circular and the dimensions were tabulated (**Table 1**). We also observed abnormal findings in one skull which showed the right sided foramen ovale having a thin bony septation perpendicular to the long (*i.e.* medio-lateral) axis of the foramen. A bony bar which divided it into two compartments was more clearly visible even from the base of the skull. This bony septum divided the foramen into two compartments of approximately equal size. This septation was intrinsic to the foramen and not a part of any ossified ligament (**Fig. 1**). In another skull, a completely ossified pterygospinous ligament (**Fig. 2**) passed immediately inferior to the left-sided foramen ovale, effectively leading the exocranial orifice of the foramen to be divided into two bony compartments. Other metrical data of the foramen ovale are presented in **Table 1**.

Metrical Data on the Foramina Ovale:

TABLE 1: MEAN LENGTH, WIDTH AND RANGE OF FORAMEN OVALE

Foramen ovale	Length (mm)		Width (mm)		Range (mm)	
	Right	Left	Right	Left	M-L diameter	A-P diameter
Mean diameter	7.45	7.61	3.99	4.6	3.54-9.21	3.33-10.12
Standard deviation	1.1	1.15	1.8	1.4	-	-

M-L=Medio-lateral, A-P=Antero-posterior

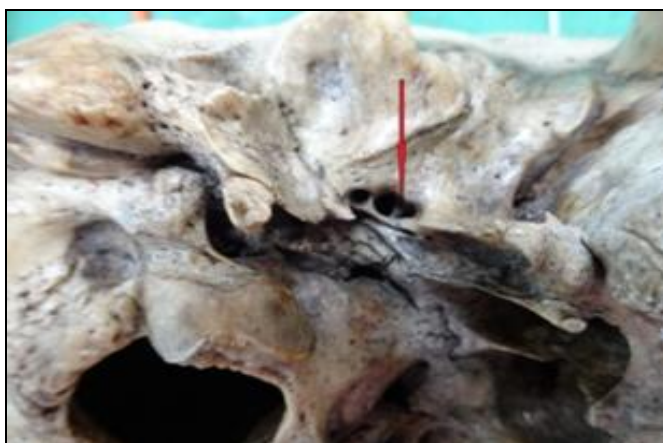


FIG. 1: THE BELOW ARROW SHOWS BONY SEPTA DIVIDING THE FORAMEN OVALE INTO TWO EQUAL PART



FIG. 2: THE ARROW POINTS TO THE OSSIFIED PTERYGOSPINOUS LIGAMENT

The Foramen Spinosum: The foramen spinosum was present bilaterally in 90% of the skulls studied. However, in one out of the 64 skulls we noticed bilateral absence of this foramen (Fig. 3) and in one

skull on its left side it was pin-holed and irregular in shape with duplication (Fig. 4) from which measurement was not taken. Measured values are tabulated (Table 2).

Metrical Data on the Foramina Spinosum:

TABLE 2: MEAN DIAMETER OF FORAMEN SPINOSUM ON RIGHT AND LEFT SIDE

Foramen spinosum	M-L axis (mm)	
	Right	Left
Mean diameter	2.54	1.97
Standard deviation	0.8	0.7

M-L = Medio-lateral.

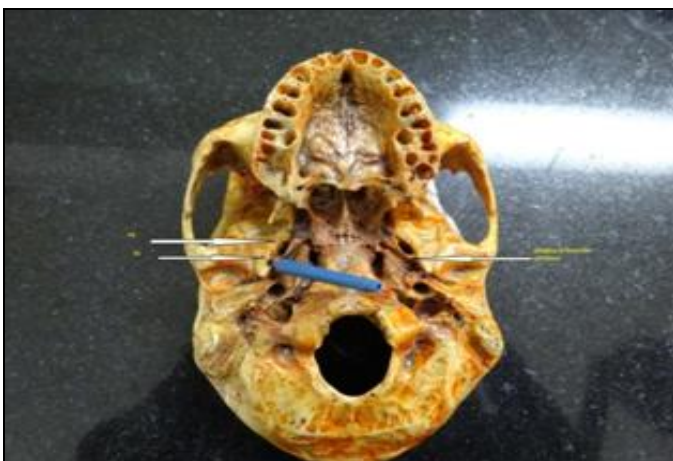


FIG. 3: THE BELOW RIGHT ARROW INDICATES THE ABSENCE OF FORAMEN SPINOSUM, PROBE INDICATES PRESENCE OF FORAMEN SPINOSUM ON THE RIGHT SIDE. (FS-FORAMEN SPINOSUM, FO- FORAMEN OVALE)

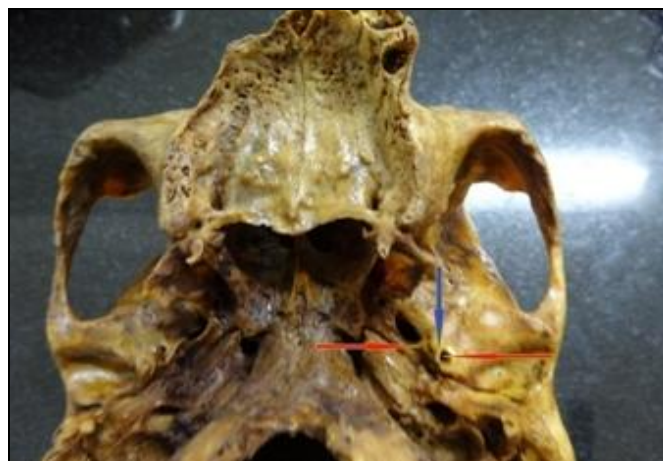

FIG. 4: BLUE ARROW INDICATES BONY SEPTUM DIVIDING THE FORAMEN SPINOSUM, RED ARROW INDICATES DUPLICATION OF FORAMEN SPINOSUM

Carotid Canal: The size and dominance (in terms of size) of the carotid canal are significant due to important contents passing through it. The dimensions of the canal in the present study were found to vary between right and left side with significant statistical significance (Table 3).

The mean dimensions of both diameters were marginally higher on the right side but length of the carotid canal was slightly higher in left side than the right side (Direct bone method). Metrical data on the carotid canal are shown in Table 3.

Metrical Data on the Carotid Canal:

TABLE 3: MEAN DIAMETER, LENGTH AND RANGE OF CAROTID CANAL ON RIGHT AND LEFT SIDES

Carotid canal	M-L axis (mm)		A-P axis (mm)		Length		Range (mm)	
	Right	Left	Right	Left	Right	Left	M-L diameter	A-P axis diameter
Mean diameter	7.3	5.9	6.08	5.36	20.3	21.03	4.92-9.21	3.24-7.89
Standard deviation	1.3	1.5	1.0	1.4	2.8	2.09	-	-

M-L = Medio-lateral, A-P = Antero-posterior

Foramen Rotundum: In this study we observed various parameters of foramen rotundum and the finding showed that distance from the midline on the right side was less than the left side (**Table 4**).

Metrical data on the Foramina Rotundum:

TABLE 4: MEAN DIAMETER AND DISTANCE FROM MIDLINE AND PETROUS APEX TO FORAMEN ROTUNDUM

Parameters	Right (mm)	Left (mm)
Longitudinal diameter	4.01	4.56
Transverse diameter	3.74	3.96
Distance from midline	16.67	18.53
Distance from petrous apex	19.01	17.02

Foramen of Vesalius: Foramen Vesalius is one of the inconsistent foramen of the skull. In this present study this foramen was present in 10 (25%) among 40 skulls observed (**Fig. 5**). Among the 10 skulls 1 showed asymmetrical duplicated foramen. The foramen of vesalius was present bilaterally in 7 skulls and unilaterally in 3 skulls with the mean diameter about 1.34mm on right side and 1.98mm on left side.

Optic Canal: The measured mean longitudinal and transverse diameters optic canal were 5.21mm, 4.64mm.

Foramen Lacerum: Present study observed bilateral presence of this foramen in all the 64 skulls (**Table 5**).

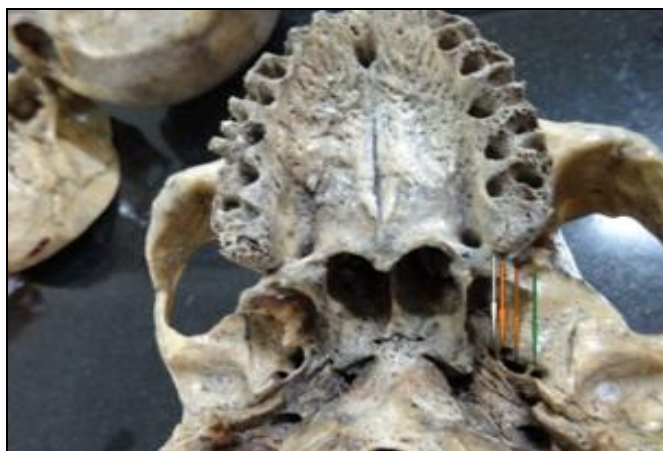

FIG. 5: WHITE ARROW INDICATES UNILATERAL PRESENCE OF LEFT FORAMEN VESALIUS LOCATED MEDIAL TO THE DUPLICATED FORAMEN OVALE ORANGE ARROW GREEN ARROW INDICATES FORAMEN SPINOSUM

Metrical Data on the Foramina Lacerum:

TABLE 5: MEAN DIAMETER AND RANGE OF FORAMEN LACERUM ON RIGHT AND LEFT SIDE

Foramen lacerum	M-L axis (mm)		A-P axis (mm)		Range (mm)	
	Right	Left	Right	Left	M-L diameter	A-P axis diameter
Mean diameter	5.21	4.9	9.73	9.1	3.2-14.9	4.2-12.82

Other parameters observed in this study were mentioned in the **Table 6 - 9**.

Distance from Mid Sagittal Plane to Various Foramina:

TABLE 6: DISTANCE FROM MIDLINE TO FORAMEN OVALE, SPINOSUM AND CAROTID CANAL

Foramen	Right (mm)	Left (mm)
Ovale	22.02	21.88
Spinosum	27.8	26.92
Carotid canal	24.04	24.52

Distance from Petrous Apex to Various Foramina:**TABLE 7: DISTANCE FROM PETROUS APEX TO FORAMEN OVALE, SPINOSUM AND CAROTID CANAL**

Foramen	Right (mm)	Left (mm)
Ovale	8.4	9.4
Spinosum	9.7	11.6
Carotid canal	15.75	15.17

Distance between Right and Left Foramina:**TABLE 8: DISTANCE BETWEEN VARIOUS RIGHT AND LEFT FORAMINA**

Foramen	Distance between right and left foramina (mm)
Ovale	44.29
Spinosum	54.56
Carotid canal	48.54

Percentage of Various Foramina:**TABLE 9: VARIATIONS OF VARIOUS FORAMINA / CANAL**

Foramen / Canal	Unilateral	Bilateral	Absence
Pterygoid canal	-	60 (4 broken)	-
Canaliculus innominatus	4 (6.25%)	27 (42.18%)	33 (51.56%)
Mastoid canaliculus	-	64	-
Tympanic canaliculus	-	64	-

DISCUSSION: Information regarding normal variations in their shapes, sizes and situation of foramina in the skull gives insight into associations between neurovascular anatomy and the cranial morphology. The sphenoid bone, due to its complex structure and intricate embryological origin, it should be studied in different anatomical aspects, including its normal and abnormal variation. As foramen ovale is one of the important foramina that lie between intracranial and extracranial structures, it is used for diagnostic and therapeutic invasive approaches^{3, 4, 5}, such as electroencephalographic analysis of seizure for patients undergoing selective amygdalohippocampectomy, microvascular decompression by percutaneous trigeminal rhizotomy for trigeminal neuralgia and percutaneous biopsy of cavernous sinus tumors⁶ etc. For this reason, the knowledge of morphologic and topographic features of foramen ovale is important.

In our present study we observed the presence of this foramen bilaterally in all the skulls. The mean length of the foramen on right side was 7.45 + 1.1 (with the range from 3.54 - 9.21mm) and left side was 7.61 + 1.15 (with the range from 3.33 - 10.12mm, **Table 10**). Just as in earlier studies there was no statistical significance ($P > 0.05$) between the two sides^{3, 5}. In this study, the mean width of the FO was 3.99 mm on right side and 4.6mm on

left side, According to previous studies, average width of FO in adult skulls was 3.7 mm⁷, whereas it was 3.21 ± 0.02 mm and 3.29 ± 0.85 mm on right side and left sides respectively³.

There are different results in the literature which evaluate the diameters of foramen ovale in different races. The average maximal length of FO was reported as 7.48mm in a developmental study performed in 220 specimens of Japanese race⁵, 7.2mm in a German study⁹ and 7.46mm in a study performed in Nepal³, 7.05mm in Indian population¹⁰.

In this present study an average distance of foramen to the midline was similar on both sides (22.02mm on the right side, 21.88mm on the left side). We observed asymmetry in shape (round versus oval) in 21.5% of skulls. To our knowledge, complete absence of the foramen ovale has not been described.

We also observed abnormal findings in one skull which showed the right sided foramen ovale having a thin bony septation perpendicular to the long (*i.e.* medio-lateral) axis of the foramen which was intrinsically dividing the foramen into two compartments of approximately equal size this bony obstructions could interfere with transcutaneous needle placement into the foramen ovale or distort anatomic relationships during approaches to the

cranial base³⁰ similarly, Ray *et al.*,³. In their study on anatomic variations of foramen ovale also reported a spine on the margin of the oval foramen in 3 cases, (2 left, 1 right) and 2 sides (1 left, 1 right) sides they found a bridge like bony spur dividing the foramen ovale into two compartments. In the present study we found that the presence of completely ossified pterygospinous ligament may form a foramen, through which the branches of mandibular nerve may pass. Presence of such

anomalies may compress upon the branches of the mandibular nerve and chorda tympani nerve. Increase in the width and flattening of the lateral pterygoid plate may leave little space, causing difficulty while performing surgery on the pterygoid region. Anomalies involving the pterygospinous ligament may not only be of academic interest but also be beneficial for maxillofacial and dental surgeons and anesthetists⁷.

Comparison of Measurements of Foramen Ovale with Previous Studies:

TABLE 10: FORAMEN OVALE: COMPARISON OF DATA FROM THE PRESENT STUDY WITH THE PREVIOUS STUDIES

Authors	Length	Width	Distance from mid sagittal line		Distance from apex of petrous	
			Right	left	right	Left
Lindblom 1936	7	4	-	-	-	-
Lang (1983)	7.26	3.65	-	-	-	-
Ray <i>et al.</i> ,	7.46	-	-	-	-	--
Landl MK, (2005)	6.6	-	-	-	-	-
	6.77					
Berge and Bergman (2001)	7.11	3.60	-	-	-	-
Osunwoke E.A <i>et al.</i> , (2005)	Max-9.5mm	Max-5	-	-	-	-
	Min-5.0mm	Min-2				
Namita A. Sharma <i>et al.</i> , (2011)	7.05	3.99	22.13	21.71	-	-
M.S. Somesh <i>et al.</i> , (2011)	7.6	5.12	-	--	-	-
Unver Dogan, N. <i>et al.</i> , (2014)	Rt-7.18	7.29	22.58	22.15	9.22	9.91
	Lt-7.29	4.06				
Present study	Rt-7.45	3.99	22.02	21.88	8.21	8.96
	Lt-7.61	4.6				

The foramen spinosum is situated postero-lateral to foramen ovale (90% in this study), along the posteromedial aspect of the greater wing of the sphenoid bone. Foramen spinosum of the 40 dry human skulls studied were of varying shapes. Some were either oval or circular. In the present study foramen spinosum was absent in 2% of skull (Tables 2). It is unilaterally absent in 0.4 – 1% of cases¹²⁻¹⁵ rarely absent on both sides¹⁶, and can be duplicated¹⁷⁻¹⁹.

These variations may be important for the vascular supply of the dura as the middle meningeal artery in these cases may enter through the foramen ovale, or through the superior orbital fissure as a branch of the sphenomaxillary portion of the maxillary artery²⁰. The middle meningeal artery can also arise from the ophthalmic artery, lacrimal artery, or from the petrous (stapedial origin), cavernous, or supraclinoid portion of the internal carotid artery^{20,16}. An additional explanation for the absence of a

foramen spinosum in the case of an aberrant middle meningeal artery may be when it arises from the stapedial branch of the internal carotid artery or the ophthalmic artery²¹.

Duplication can be explained by early division of the middle meningeal artery into a posterior and anterior division resulting in a duplicate FS^{21,4,22}. But there was no explanation on the course of the meningeal branch of the mandibular nerve in the absence or duplication of a FS. The external diameters of FS varied from side to side but did not usually exceed 3mm (Table 2). According to Sondheimer²², in the instance of the diameter exceeding 5mm; the patient should be immediately evaluated for middle meningeal artery abnormality. This study has revealed that the mean M-L diameter of foramen spinosum was 2.54 + 0.8 on right side, 1.97 + 0.7 on left side, these findings were compared with the previous studies and values are mentioned in the Table 11.

Comparison of Measurements of Carotid Canal with Previous Studies:

TABLE 11: COMPARISON OF MEASUREMENTS OF CAROTID CANAL WITH PREVIOUS STUDIES

Diameter	Berge and Bergman (2001)	Namita A. Sharma et al., (2011)	Vidya et al., (2015)	Present study
Average size (mm)	7.13x5.29	7.01x5.42	Rt- 8.12±0.99 6.31±0.64 Lt-8.15±1.00 6.19±0.80	Rt-7.3±1.3 5.9±1.5 Lt-6.08±1.0 5.36±1.4
Max.size (mm)	12x5	8.7x8.14	-	9.21x7.81
Min. size(mm)	5.5x0.64	7.14x3.20	-	4.9x3.2
Distance from mid-sagittal plane	-	25.312 (right) 24.88 (left)	-	24.04 (right) 24.52 (left)
Distance from petrous apex	-	-	-	15.75 (right) 15.17 (left)

The foramen venosum (Vesalius) is regarded as a small opening in the medial aspect of the greater wing of the sphenoid bone antero-medial to FO. It is interesting to note that the foramen of Vesalius is an exclusive feature of the human skull and is not present in any other primate²³.

We observed presence of single and duplication of this foramen. This foramen was present bilaterally in 17.5% skulls however unilaterally in 7.5% of skulls. In the absence of the FV, the respective emissary vein leaves the skull through the FO (Henderson). In addition, Lang⁹ et al., described a small nerve, the nervulus sphenoidalis lateralis, which may also pass through the FV into the cavernous sinus. The external diameter was found to be 1.34mm on right side and 1.98mm on left side. Which was compared with the values recorded in earlier studies?

Ozer and Govsa²⁴ explained that the FV presenting with a diameter of less than 0.5mm are most reliable and safe during percutaneous practice as apertures of greater than 0.5mm has a major risk on the adjacent foramen ovale. Surgical importance of foramen vesalius in the fact that during percutaneous trigeminal rhizotomy, needle insertion through the FV the cavernous sinus puncture may occur and has been described in eight cases with temporal lobe hematoma³.

Therefore, the knowledge about the symmetry and incidence of FV is not only important from the anatomical point of view but is also essential for the operating surgeon. In view of carotid canal contents the dimensions of the carotid canal were important. In the present study values were compared with the previous studies (**Table 11**).

The position, dimensions and extensions of the carotid canal are of vital importance in cases of skull base surgery as in the identification and isolation of the internal carotid artery throughout its petrous course²⁶. However, the variations in the size of the foramen were more divergent in the study conducted by Berge and Bergman¹².

In another study conducted by Namitha A, noticed bilateral absence of the carotid canal. The canal will fail to develop in the case of agenesis of the ICA, or if the vessel takes an aberrant path²⁶. The foramen rotundum is situated along the medial root of the greater wing of the sphenoid bone, just lateral to the inferior aspect of the superior orbital fissure and separated from it by a thin bar of bone.

A more common variant of the FR is known as "lateral rotundal canal" with average diameter about 1 to 3mm in the floor of this foramen, which opens in to the infratemporal fossa or in to the space between the pterygoid plates. In anatomic dissections, Sondheimer detected these openings in five of 50 skulls and speculated that they transmitted emissary veins²⁷. Kocaogullar²⁸ reported that the average diameter of this foramen was 3.11 in cadaver specimens, 3.44 in 52 skulls. Unver dogan, N. et al., found that there wasn't statistical significance ($P > 0.05$) between both sides in the average longitudinal diameters (4.48 ± 1.15 mm in the right, 4.36 ± 0.66 mm in the left) and average transverse diameters.

This investigation also took up the optic canal also to measure its diameter. The Mean longitudinal and transverse diameters were 5.21, 4.64 (in mm). Duplication and absence of canal was not found in this study.

This canal is an important channel between orbital and intracranial fossa¹⁷. And it is the narrowest path which leads optic nerve to the brain along with ophthalmic artery. Anatomy of the optic canal is important for the surgeons while performing optic nerve decompression surgery¹⁹. Duplications of optic canals have been reported earlier by Warwick, Choudhary *et al.*, and Mandavi Singh. The artery and nerve are separated by a layer of dense connective tissue which may occasionally be ossified to result in the duplication of the optic canal. Probably because it does not transmit any major structure, the foramen lacerum has not been much studied by previous researchers.

In the present study its dimensions were seen to vary between rights and left the values are mentioned in the **Table 5**. The canaliculus innominatus (also known as the canal of Arnold) is a very small canal situated medially between the foramen ovale and the foramen spinosum^{22, 29}.

When present, this canal transmits the lesser superficial petrosal nerve, a tiny nerve originating from the tympanic branch of the glossopharyngeal nerve but also containing several fibers from the facial nerve²⁹.

In the present investigation it was found to be present unilaterally in 4 (6.25%) skulls, bilaterally in 27 (42.18%) skulls and absent in 31 skulls 33 (51.56%). To our knowledge we observed presence or absence of pterygoid canal, tympanic and mastoid canaliculi in all the skulls included in the study.

Anatomical variations in appearance of shape, diameter and distance from mid - sagittal plane, petrous apex to various foramina like foramen ovale, foramen spinosum, foramen vasalius, are of great surgical importance. Knowledge about structures passing through the various foramina of the skull will help in distinguishing normal from potentially abnormal foramina during radiological investigation.

CONCLUSION: The information provided in with this study can help the anatomist to increase the knowledge about anatomy of middle cranial fossa and also help the medical practitioners, in cases of trigeminal neuralgia and in diagnostic detection of

tumors and abnormal bony outgrowths that may lead to ischemia, necrosis .

ACKNOWLEDGEMENT: We thank to Saveetha Medical College and Hospital for providing resource material for this study and we also like to thank Dr. Gunapriya Raghunath for constant support and motivation.

CONFLICT OF INTEREST: There are no conflicts of interest between the authors.

REFERENCES:

1. Standring SM: Gray's Anatomy. 39th ed. New York, Elsevier Churchill Livingstone 2005; 462-6.
2. Sharma NA and Garud RS: Morphometric evaluation and a report on the aberrations of the foramina in the intermediate region of the human cranial base: A study of an Indian population. *Eur. J. Anat* 2011; 15(3): 140-9.
3. Ray B, Gupta N and Ghose S: Anatomic variations of foramen ovale. *Kathmandu Univ. Med. J. (KUMJ)* 2005; 3(1): 64-8.
4. Reymond J, Charuta A and Wysocki J: The morphology and morphometry of the foramina of the greater wing of the human sphenoid bone. *Folia Morphol. (Warsz)* 2005; 64(3): 188-93.
5. Yanagi S: Developmental studies on the foramen rotundum, foramen ovale and foramen spinosum of the human sphenoid bone. *The Hokkaido Journal of Medical Science* 1987; 62(3): 485-496.
6. Somesh MS, Sridevi HB *et al.*: A Morphometric Study of Foramen Ovale. *JTN*. DOI: 10.5137/1019-5149.JTN.3927-10.
7. Kavitha KB, Vasantha K *et al.*: Anatomical Study of Pterygospinous and Pterygoalar Bar in Human Skulls with their Phylogeny and Clinical Significance *J Clin Diagn Res* 2014; 8(9): 10-13.
8. Berry AC and Berry RJ: Epigenetic variation in human cranium. *J Anat.* 1967; 101: 361-379.
9. Lang J, Maier R and Schafhauser O: Postnatal enlargement of the foramina rotundum, ovale, spinosum and their topographical changes. *Anat. Anz* 1984; 5: 351-87.
10. Sharma NA and Garud RS: Morphometric evaluation and a report on the aberrations of the foramina in the intermediate region of the human cranial base: A study of an Indian population. *Eur. J. Anat* 2011; 15(3): 140-9.
11. Tubbs R Shane MS, Pa C *et al.*: Ossification of ligaments near the foramen ovale: An anatomic study with potential clinical significance regarding transcutaneous approaches to the skull base neurosurgery 2009; 65: 60-64.
12. Berge JK and Bergman RA: Variations in size and in symmetry of foramina of the human skull. *Clin Anat* 2001; 14: 406-413.
13. Berlis A, Putz R and Schumacher M: Direct and CT measurements of canals and foramina of the skull base. *Br. J. Radiol* 1992; 65(776): 653-61.
14. Greig DM: Congenital anomalies of the foramen spinosum. *Edinb Med J* 1929; 363-371.
15. McLennan JE, Rosenbaum AE, Haughton VM: Internal carotid origins of the middle meningeal artery. *Neuroradiology* 1974; 7: 265-275.

16. Royle G and Motson R: Anomalous origin of the middle meningeal artery. *J Neurol Neurosurg Psychiatry* 1973; 36: 874-876.
17. Choudhry R, Choudhry S and Anand C: Duplication of optic canals in human skulls. *J Anat* 1988; 159: 113-116.
18. Curtin HD, Williams R and Johnson J: CT of perineural tumor extension: pterygopalatine fossa. *AJNR Am. J. Roentgenol* 1985; 144(1): 163-9.
19. He Z, Li Q, Yuan J, Zhang X, Gao R, Han Y, Yang W, Shi X and Lan Z: Evaluation of transcranial surgical decompression of the optic canal as a treatment option for traumatic optic neuropathy. *Clin Neurol Neurosurg* 2015; 134: 130-135.
20. Manjunath KY: Anomalous origin of the middle meningeal artery - A review. *J Anat Soc India* 2001; 50: 179-183
21. Lindblom K: A roentgenographic study of the vascular channels of the skull. *Acta Radiol (Suppl)* 1936; 30.
22. Sondheimer FK: Basal foramina and canals. In: Newton TH, Potts DG, eds. *Radiology of the skull and brain: the skull* Book 1. St. Louis: Mosby 1971; 1: 287-347.
23. Wood-Jones F: The non-metrical morphological characters of the skull as criteria for racial diagnosis. Part I. General discussion of the morphological characters employed in racial diagnosis. *J Anat.* 65: 179-195.
24. Ozer MA and Govsa F: Measurement accuracy of foramen of vesalius for safe percutaneous techniques using computer assisted three-dimensional landmarks. *Surg. Radiol. Anat* 2014; 36(2): 147-54.
25. Vidya C and Shamasundar N: Study of Morphometry of Carotid Canal in Skulls of South Indian origin. *Journal of Clinical Diagnostic Research* 2015; 9(2): 10497-5590.
26. Toth M, Medvegy T, Moser G and Patonay L: Development of the protympanum. *Ann Anat*, 2006; 188: 267- 273.
27. Ginsberg LE, Pruett SW, Chen MY and Elster AD: Skull-base foramina of the middle cranial fossa: reassessment of normal variation with high-resolution CT. *Am J Neuroradiol.* 1994; 15: 283-2917
28. Kocaogullar YAE, Fossett D and Caputy A: The extradural subtemporal keyhole approach to the sphenocavernous region: anatomic considerations. *Minim. Invasive Neurosurg.*, 2003; 46(2): 100-5.
29. Williams PL, Warwick R and Dyson M: *Bannister –H Gray's anatomy of the human body.* 37th ed. New York: Churchill Livingstone 1989, 362-377.

How to cite this article:

Sankaran PK, Raghunath G, Arathala R, Karthikeyan, Menaka, Madhumitha, Yuvaraj M and Kumaresan M: Morphological study of middle cranial fossa and its variations. *Int J Pharm Sci & Res* 2018; 9(2): 693-01. doi: 10.13040/IJPSR.0975-8232.9(2).693-01.

All © 2013 are reserved by International Journal of Pharmaceutical Sciences and Research. This Journal licensed under a Creative Commons Attribution-NonCommercial-ShareAlike 3.0 Unported License.

This article can be downloaded to **ANDROID OS** based mobile. Scan QR Code using Code/Bar Scanner from your mobile. (Scanners are available on Google Playstore)