



Received on 17 March, 2017; received in revised form, 23 May, 2017; accepted, 27 May, 2017; published 01 November, 2017

## ASSESSMENT OF HEPATOPROTECTIVE ACTIVITY BY *LYCOPERSICON ESCULENTUM*

Ankur Choubey <sup>\*1,3</sup>, Shashi Alok <sup>2</sup>, Santosh Singh <sup>3</sup> and Ritu M. Gilhotra <sup>3</sup>

Faculty of Pharmacy <sup>1</sup>, VNS Group of Institutions, Bhopal - 462044, Madhya Pradesh, India.

Institute of Pharmacy <sup>2</sup>, Bundelkhand University, Jhansi - 284128, Uttar Pradesh, India.

School of Pharmacy <sup>3</sup>, Suresh Gyan Vihar University, Jaipur - 302025, Rajasthan, India.

### Keywords:

*Lycopersicon esculentum*,  
Hepatoprotective activity,  
Biochemical analysis, Serum analysis

### Correspondence to Author:

**Ankur Choubey**

Faculty of Pharmacy,  
VNS Group of Institutions,  
Bhopal - 462044, Madhya Pradesh,  
India.


**E-mail:** [chaubey.ankur03@gmail.com](mailto:chaubey.ankur03@gmail.com)

**ABSTRACT:** Liver manage different critical metabolic functions. The point of this review is to think about hepatoprotective movement of lycopene and non lycopene containing part of tomato concentrate to investigate the likelihood that a few constituents other than lycopene may be in charge of hepatoprotective action. Writing uncovered that plant containing Carotenoids, Lycopene, Carotene, Xanthophylls, Xanthophylls Ester mixes were in charge of hepatoprotective action and they chose plant additionally having these constituent so it was conjectured that it might likewise have the capacity to ensure the liver. Keeping this view exhibit study is meant to arrange the work for the impact of hepatoprotective action of *Lycopersicon esculentum*. Paracetamol-initiated liver rot was repressed essentially by methanolic-I extricate (Non-lycopene fractionate) of *Lycopersicon esculentum*. The outcomes reasoned that the Methanolic-I (Non-lycopene division) was more compelling than the Methanolic-II (Non-lycopene part) extricate. The CCl<sub>4</sub>-III (Lycopene division) was observed to be not powerful in the treatment of the hepatotoxicity. In this manner it can be derived from this examination that *Lycopersicon esculentum* showed hepatoprotective action and this might be because of its rich substance of flavonoids. Hepatoprotective movement of flavonoids is very much recorded before. At long last, it is inferred that, the plant *Lycopersicon esculentum* might be investigated as a strong hepatoprotective because of nearness of Flavonoid.

**INTRODUCTION:** The Indian customary solutions can be categorized into two gatherings. In first gathering are the restorative arrangements which are for the most part of plants, minerals, or creature birthplace or blends of a few of them and have well set down system for their arrangements. While the people meds have a place with the second gathering, which are home grown house hold cures and have no precise approach for preparing crude materials and are generally utilized as family conventions <sup>1,2</sup>.

The WHO shows that around 80% of the total populace living in the creating nations depends only on customary prescription for the essential medicinal services needs <sup>4</sup>. The therapeutic plants assume a noteworthy part and the constituent the foundation of the conventional solution. India materia medica incorporates around 2000 medications of common birthplace all of which are gotten from various conventional framework and fables rehearses.

The accentuation of advancement of new organically dynamic particles has been slowly supplanted by utilization of aggregate herbs as medication and nourishment supplement now natural based items have great present and future prospects in International market <sup>3,5</sup>. Liver manage different essential metabolic capacities.

QUICK RESPONSE CODE	DOI: 10.13040/IJPSR.0975-8232.8(11).4694-03
	Article can be accessed online on: <a href="http://www.ijpsr.com">www.ijpsr.com</a>
DOI link: <a href="http://dx.doi.org/10.13040/IJPSR.0975-8232.8(11).4694-03">http://dx.doi.org/10.13040/IJPSR.0975-8232.8(11).4694-03</a>	

It assumes a noteworthy part in detoxification and discharge of numerous endogenous and exogenous mixes, and damage to it or weakness of its capacities may prompt to numerous ramifications on one's wellbeing. Liver channels unsafe substances from the blood, directs hormones and in addition vitamins and sugar. Regardless of the gigantic advances made in allopathic drugs, no successful hepatoprotective solution is accessible. Phytoconstituents are known to assume key part in the administration of liver sickness<sup>6,7</sup>.

The point of this review is to look at hepatoprotective movement of lycopene and non lycopene containing segment of tomato concentrate to investigate the likelihood that a few constituents other than lycopene may be in charge of hepatoprotective action. Writing uncovered that plant containing Carotenoids, Lycopene, Carotene, Xanthophylls, Xanthophylls Ester mixes were in charge of hepatoprotective action and plant likewise having these constituent so it was theorized that it might likewise have the capacity to ensure the liver. Keeping this view exhibit study is expected to arrange the work for the impact of hepatoprotective action of *Lycopersicon esculentum*.

#### **Experimental:**

**Plant Material:** Plants materials *Lycopersicon esculentum* were collected from the local market of Bhopal, (M.P.) during the month of May –July, 2014. The specimens were identified and authenticated by Dr. Zia ul Hassan, Assistant professor, Department of Botany, Saifia College of Science and Education, Bhopal and their herbarium was deposited. These collected specimens were chosen for the extraction process and assessment of hepatoprotective activity.

**Extraction:** Canned tomato glue, 50g, in a 3L wide mouthed jug is got dried out by including 65mL methanol. The blend is instantly shaken overwhelmingly to keep the arrangement of hard knots. A little example of the suspension is tried by hands; on the off chance that it has glutinous consistency; more methanol is added to the principle segment to keep away from the conceivable stopping up of channels. The blend is permit remaining for 1-2 hr and is then shaken energetically. The thick suspension is sifted on a

Buchner channel (distance across 20-25cm). The yellow filterate is disposed of the dim red cake is come back to the container and shaken with a blend of 65mL methanol and 65mL carbon tetra chloride. The plug of a container must fit well and ought to be lifted for a minute after the blending, to discharge any development weight. Brief shaking took after by opening of the container is rehashed until not any more abundance weight is taken note. The suspension is shaken for 10-15 min and isolated by filtration on a huge Buchner channel. The filterate comprises of a lower, exceptionally dull red, CCl<sub>4</sub> stage, and an orange watery methanolic layer<sup>8-10</sup>.

**Phytochemical Analysis:** Screening was carried out on all the extracts of Fruit of *Lycopersicon esculentum* to determine the active principles or secondary plant constituents. The screening was carried out in the Pharmacognosy lab of the V.N.S Institute of Pharmacy, Bhopal (M. P.). Different substance tests keeping in mind the end goal to decide the optional plant constituent's exhibits by utilizing the utilization of different strategies as takes after<sup>11-12</sup>. With a specific end goal to identify the different constituents introduce in the distinctive concentrates of *Lycopersicon esculentum* these were subjected to the tests according to strategies depicted by Ansari, and khandelwal.

#### **In vivo Experimental Design:**

**Animals for Experiment:** Swiss albino rats were obtained from animal house VNS institute of Pharmacy with due permission from Institutional animal ethical committee (Registration Number. 778/03/c/cpsa). Acute toxicity studies were conducted by using albino mice of either sex weighing between 20 and 25gms and healthy adult male albino rats weighing between 150 and 200 gms were selected for the Hepatoprotective screening. The animals were acclimatized to standard laboratory conditions (temperature: 25 ± 20 °C) and maintained on 12-hr light: 12-dark cycle. They were provided with regular rat chow (Lipton India Ltd., Mumbai, India) and drinking water *ad libitum*.

**Acute Toxicity:** A safe oral dose was determined through the acute oral toxic test in rats as described by the Organization of Economic Co-Operation and

Development (OECD) as per 423 guidelines (OECD Guidelines for the Testing of Chemicals, 2010). The extract, at different doses up to 3000 mg/kg, was prepared by dissolving the extract in distilled water and the concentration was adjusted in such a way that it did not exceed 1mL/100g of the rat. The extract was then administered (p.o.) and animals were observed for behavioural changes, any toxicity and mortality up to 48 hr. Doses (1/10 or 1/5 mg/kg, p.o) of extract were later chosen for this study based on the acute toxicity testing<sup>13-14</sup>.

**Preparation of Extract:** Dosage form was prepared in the Tween 80. 1g of extract were taken in the mortar and pestle and triturated with 10ml Tween 80 continuously to get homogenous suspension being concentration of 100mg/ml of drug in each case. Suspensions were stored in airtight bottles in a cool place. Silymarin suspension (silybon) was also take-up for study.

**Preparation of Toxin Solution:** 3g of paracetamol suspended in to 100mL of distilled water and administered orally<sup>40</sup>.

### Pharmacological Screening:

**Biological Activity:** Assurance of hepatoprotective action in (corrective perspective). Paracetamol initiated hepatotoxicity<sup>15</sup>. At the point when taken in ordinary helpful measurements, paracetamol has been appeared to be sheltered. Taking after remedial measurements, it is for the most part changed over to nontoxic metabolites by means of Phase II digestion by conjugation with sulfate and glucuronide, with a little segment being oxidized through the cytochrome P450 compound framework. Cytochrome P450 2E1 and 3A4 change over around 5% of paracetamol to a very receptive delegate metabolite, N-acetyl-p-benzoquinone-imine (NAPQI). Under ordinary conditions, NAPQI is detoxified by conjugation with glutathione to form cystine and mercapturic corrosive conjugates<sup>16-18</sup>.

In instances of paracetamol overdose, the sulfate and glucuronide pathways get to be distinctly immersed, and more paracetamol is shunted to the cytochrome P450 framework to deliver NAPQI. Accordingly, hepatocellular supplies of glutathione get to be distinctly drained, as the interest for

glutathione is higher than its recovery. NAPQI subsequently stays in its poisonous frame in the liver and responds with cell layer atoms, bringing about across the board hepatocytodamage and demise, prompting to intense hepatic putrefaction. In creature ponders, hepatic glutathione must be exhausted to under 70% of ordinary levels before hepatotoxicity happens<sup>19-20</sup>.

### Paracetamol Toxicity:

**Experimental Procedure:** Hepatoprotective study will carry out as described by Ashish et al., 2010. Swiss albino mice of either sex (20-50g) select and divide into 6 groups of six animals each. The animals treat with paracetamol (500mg/kg) for seven days except normal control group which will treat with vehicle. In order to assess hepatoprotective action of *Lycopersicon esculentum* extract in albino rats, the rats were divided into the following groups each containing 4 mice (n = 3-6)<sup>47</sup>.

**Group 1:** Control mice: which were fed normal diet and water (*ad-libitum* condition).

**Group 2:** Paracetamol treated mice: paracetamol 300mg/kg body weight p.o. on daily basis for 7 days.

**Group 3:** Reference rats: treated with Silymarin 100mg/kg and paracetamol 300mg/kg body weight p.o. on daily basis for 7 days.

**Group 4:** Extract treated rats: received Methanolic-I extract of *Lycopersicon esculentum* on daily basis for 7 days.

**Group 5:** Extract treated rats: treated with Methanolic-II extract of *Lycopersicon esculentum*.

**Group 6:** Extract treated rats: treated with CCl<sub>4</sub> extract of *Lycopersicon esculentum*.

**Biochemical Assays:** Serum marker enzymes of liver function: Serum will separate by centrifugation at 3000 rpm at 4 °C for 10 min and used for measurement of various biochemical markers like SGOT, Total bilirubin, AST, alkaline phosphatase (ALP) activity.

### Serum Analysis:

#### Aspartate Aminotransferase (AST):

**Method:** 2, 4-DNPH (Retiman and Frankel Method).

**Assay Principle:** Aspartate aminotransferase (AST) catalyses the transamination of L-Aspartate and  $\alpha$ -Ketoglutarate to form oxaloacetate and L-Glutamate. Oxaloacetate so formed is coupled with 2, 4-dinitrophenyl hydrazine (2, 4-DNPH) to form a corresponding hydrazone, a brown colored complex in alkaline medium and this can be measured calorimetrically<sup>21-23</sup>.

**TABLE 1: PROCEDURE OF ASPARTATE AMINOTRANSFERASES (AST)**

Pipette into tube marked	Blank	Standard	Test	Control
	Volume in mL			
Reagent 1	0.25	0.25	0.25	0.25
Serum	-	-	0.05	-
Standard	-	0.05	-	-
Mixed well and Incubate at 37 °C for 60 minute				
Reagent 2	0.25	0.25	0.25	0.25
Deionised water	0.05	-	-	-
Serum	-	-	-	0.05
Mix well and allow to stand for 20 minutes at room temperature (15-30 °C)				
Solution I	2.5	2.5	2.5	2.5

Mix well and read the OD against water in a colorimeter using green filter or on photometer at 505 nm, within 15 minutes.

**Calculation:**

$$\text{AST (GOT) Activity} = \frac{\text{Abs. of Test} - \text{Abs. of Control}}{\text{Abs. of Standard} - \text{Abs. of Blank}} \times \text{Conc. Of Standard}$$

**Alanine aminotransferases (ALT) / (GPT):**

**Method:** 2, 4 DNPH (Retiman and Frankal method)

**Assay Principle:** Alanine aminotransferases (ALT) catalyses the transamination of L-Alanine and  $\alpha$ -Ketoglutarate to form pyruvate and L- glutamate. Pyruvate so formed is coupled with 2, 4-dinitrophenylhydrazine (2, 4 DNPH) to form a corresponding hydrazone, a brown colour complex in alkaline medium and this can be measured calorimetrically<sup>21-23</sup>.

$\alpha$ -KG + L-Alanine = pyruvate + L-glutamate  
pyruvate + 2,4- DNPH = corresponding hydrazone (brown colour).

**TABLE 2: PROCEDURE OF ALANINE AMINOTRANSFERASES (ALT)/ (SGPT)**

Pipette into tube marked	Blank	Standard	Test	Control
	Volume in mL			
Reagent 1	0.25	0.25	0.25	0.25
Serum	-	-	0.05	-
Standard	-	0.05	-	-
Mixed well and Incubate at 37 °C for 30 minute				
Reagent 2	0.25	0.25	0.25	0.25
Deionised water	0.05	-	-	-
Serum	-	-	-	0.05
Mix well and allow to stand for 20 minutes at room temperature(15-30 °C)				
Solution I	2.5	2.5	2.5	2.5

Mix well and read the O.D. against Purified water in a colorimeter using green filter or on photometer at 505 nm, within 15 minutes.

**Alkaline Phosphate (ALP):**

**Method:** Kind and King's Method.

**Principle:** Alkaline phosphatase from serum converts phenyl phosphate to inorganic phosphate and phenol at pH 10.0. Phenyl so formed reacts in

alkaline medium with 4-aminoantipyrine I presence of the oxidizing agent Potassium ferricyanide and forms an orange red colored complex, which can be measured calorimetrically. The colour intensity is proportional to the enzyme activity<sup>24-25</sup>.

**Calculation:**

$$\text{ALP Activity} = \frac{\text{Abs. of Test} - \text{Abs. of Control}}{\text{Abs. of Standard} - \text{Abs. of Blank}} \times 10$$

**TABLE 3: PROCEDURE OF ALKALINE PHOSPHATE (ALP)**

Pipette into tube marked	Blank	Standard	Test	Control
		Volume in mL		
Working Buffer	0.5	0.5	0.5	0.5
Deionised water	1.5	1.5	1.5	1.5
	Mixed well and incubate at 37 °C for 30 minutes			
Serum	-	-	0.05	-
Reagent 3	-	0.05	-	-
	Mixed well and incubated at 37 °C for 15 minutes			
Reagent 2	1.0	1.0	1.0	1.0
Serum	-	-	-	0.05

Mixed well after addition of each reagent and measure the Abs. of the Blank (B), Standard (S), Control (C), and Test (T) against purified water using green filter at 510 nm.

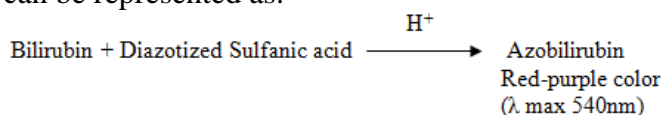
### Bilirubin:

**Method:** Melloy and Evelyn method.

### Principle:

**Direct (Conjugated):** Bilirubin couples with diazotized sulfanilic acid, forming Azobilirubin, a red-purple colored product in acidic medium.

**Indirect (Unconjugated):** Bilirubin is diazotized only in the presence of its dissolving solvent (Methanol). Thus the red-purple colored azobilirubin produced in the presence of methanol originates from both Direct and indirect fractions and thus represents Total Bilirubin concentration. The difference of Total and Direct Bilirubin gives Indirect Bilirubin. The intensity of red-purple color so developed above is measured colorimetrically and it is proportional to the concentration of the appropriate fraction of bilirubin<sup>25-32</sup>. The reaction can be represented as:

**TABLE 4: PROCEDURE OF BILIRUBIN**

For UV	T1	T2	D1	D2
	Volume in mL			
Serum/Plasma	0.1	0.1	0.1	0.1
Distilled water	0.9	0.9	0.9	0.9
Reagent 3: Diazo	-	0.25	-	0.25
Blank				
Distilled water	-	-	1.25	1.25
Reagent 4 Methanol	1.25	1.25	-	-

**Histopathological Studies:** After collecting blood samples, the animals from all groups were sacrificed by cervical dislocation and liver was

removed liver was then cut into small pieces and fixed in 10% neutral formalin solution for 2 days, followed by dehydration through graded alcohol and xylene. The portions were then embedded in paraffin wax following the standard micro technique. Section were made at multiple levels and stained routinely with hematoxylin and eosin. Mounted slides were examined for Histopathological changes in liver and their micrographs were taken.

**Histopathological Analysis:** In rats of control group, the liver architecture was normal and the cells were arranged radially (**Fig. 2**). The liver dissected from Paracetamol treated rats with dose of 500mg/kg body weight p.o., showed vacuole formation and fatty degeneration. Some of the cells found to have damaged cell walls (**Fig. 3**). The normal texture and cell arrangement were observed in the liver section of rats treated with Silymarin with dose of 100mg/kg body weight p.o. (**Fig. 4**). In rats treated with dose of Methanolic- I extract *i.e.* 500mg/kg body weight p.o., the liver appeared normal. Similar texture and cell arrangement were observed in the liver section of rats treated with Silymarin (**Fig. 5**).

In mice treated with the dose of Methanolic- II extract *i.e.* 500mg/kg body weight p.o. along with paracetamol, the damage was less marked and vacuole formation was observed. The liver cells were observed to be well organized around the central vein along with fat depositions (**Fig. 6**). In mice treated with the dose of CCl<sub>4</sub>-III extract *i.e.* 500mg/kg found to have damaged cell walls (**Fig. 7**). These changes in the liver architecture were coincided with the corresponding changes in the enzyme levels and hence hepatoprotective effect of *Lycopersicon esculentum* was confirmed.

**Statistical Analysis:** Statistical evaluation of the data was done by Student's *t* test. (Graph PAD

Instat software, Kyplot). A value of  $p < 0.05$  was considered to be significant.

**Observations:**

**TABLE 5: EFFECT OF METHANOLIC-I (NON-LYCOPENE FRACTIONATE) EXTRACT OF *LYCOPERSICON ESCULENTUM* ON BIOCHEMICAL PARAMETERS (ON 8<sup>TH</sup> DAY)**

Group	Mean ± SEM			
	SGOT	SGPT	ALP	Total Bilirubin
Normal control	24.74±0.21	95.93±0.14	102.95±0.2	0.35±0.012
PCM control(500mg/kg)	138.527±0.208 <sup>a</sup>	172.56±0.29 <sup>a</sup>	155.73±0.20 <sup>a</sup>	8.256±0.117 <sup>a</sup>
PCM+ Silymarin(100mg/kg)	89.032±0.32*	121.02±0.27*	94.93±0.091*	0.977±0.0213*
PCM+Methanolic-I (Non-Lycopene Fractionate)	96.31±0.34*	136.29±0.34*	114.15±0.27*	1.136±0.018**

N = 6 Swiss albino mice per group, tabular value represents mean ± SEM.

\* $p < 0.05$  (Comparison of Group II with I)

\*\* $p < 0.05$ : (Comparison of group III and IV with II)

**TABLE 6: EFFECT OF METHANOLIC-II (NON-LYCOPENE FRACTIONATE) EXTRACT OF *LYCOPERSICON ESCULENTUM* ON BIOCHEMICAL PARAMETERS (ON 8<sup>TH</sup> DAY)**

Group	Mean ± SEM			
	SGOT	SGPT	ALP	Total Bilirubin
Normal control	24.74±0.21	95.93±0.14	102.95±0.2	0.35±0.012
PCM control(500mg/kg)	138.527±0.20 <sup>a</sup>	172.56±0.29 <sup>a</sup>	155.73±0.203 <sup>a</sup>	8.256±0.117 <sup>a</sup>
PCM+ Silymarin(100mg/kg)	89.032±0.32*	121.023±0.27*	94.93±0.091*	0.977±0.0213*
PCM+Methanolic-II (Non-Lycopene Fractionate)	107.016±0.16*	150.81±0.147*	129.91±0.158*	1.29±0.0125*

N = 6 Swiss albino mice per group, tabular value represents mean ± SEM.

\* $p < 0.05$  (Comparison of Group II with I)

\*\* $p < 0.05$ : (Comparison of group III and IV with II)

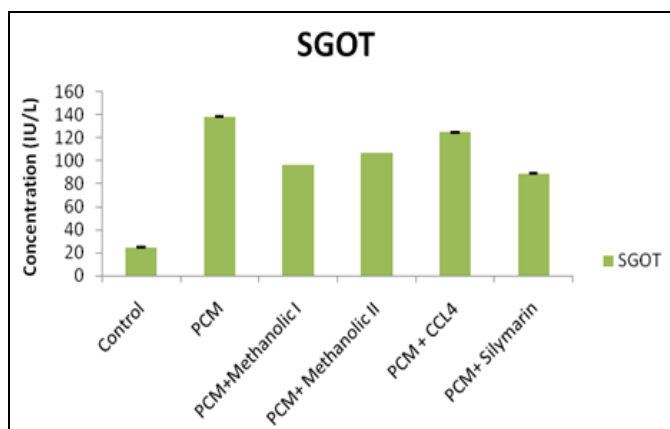
**TABLE 7: EFFECT OF CCL<sub>4</sub>-III (LYCOPENE FRACTIONATE) EXTRACT OF *LYCOPERSICON ESCULENTUM* ON BIOCHEMICAL PARAMETERS (ON 8<sup>TH</sup> DAY)**

Group	Mean ± SEM			
	SGOT	SGPT	ALP	Total Bilirubin
Normal control	24.74±0.21	95.93±0.14	102.95±0.2	0.35±0.012
PCM control (500mg/kg)	138.527±0.20 <sup>a</sup>	172.56±0.29 <sup>a</sup>	155.73±0.203 <sup>a</sup>	8.256±0.117 <sup>a</sup>
PCM+ Silymarin (100mg/kg)	89.032±0.32*	121.023±0.27*	94.93±0.091*	0.977±0.021*
PCM+CCL <sub>4</sub> -III (Lycopene Fractionate)	124.73±0.20*	165.99±0.161*	155.67±0.151*	8.75±0.421*

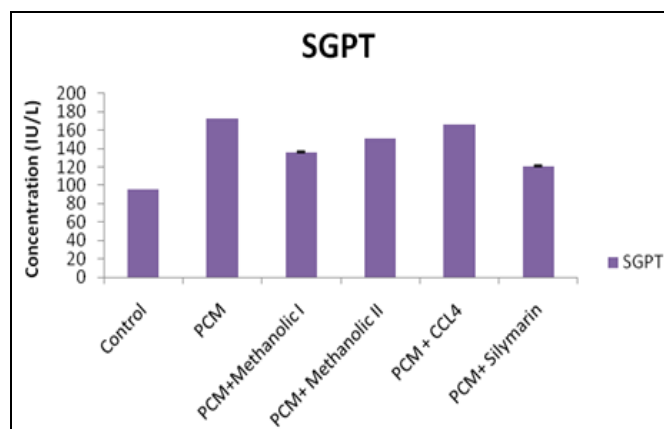
N = 6 Swiss albino mice per group, tabular value represents mean ± SEM.

\* $p < 0.05$  (Comparison of Group II with I)

\*\* $p < 0.05$ : (Comparison of group III and IV with II)



**FIG. 1: SREUM SGOT (SERUM GLUTAMIC OXALOACETIC TRANSAMINASE) PARAMETERS OF DIFFERENT GROUP**



**FIG. 2: SREUM SGPT (SERUM GLUTAMIC PYRUVATE TRANSAMINASE) PARAMETERS OF DIFFERENT GROUP**

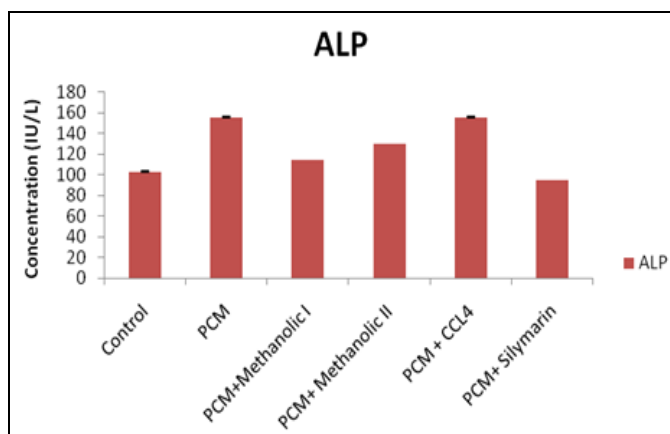


FIG. 3: SREUM ALP (ALANINE TRANSAPYRUVATE) PARAMETERS OF DIFFERENT GROUP

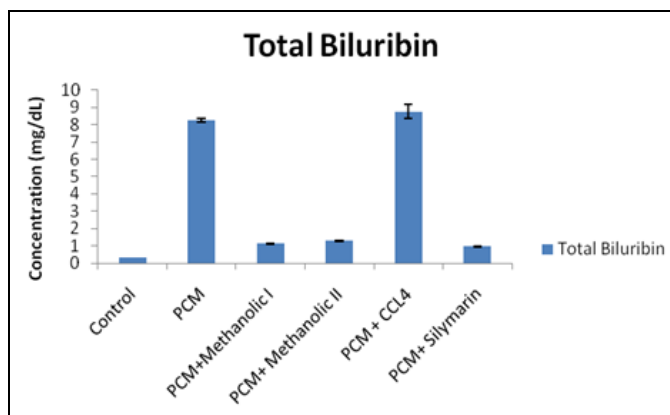


FIG. 4: SERUM TBIL (TOTAL BILIRUBIN) PARAMETERS OF DIFFERENT GROUP

**RESULTS AND DISCUSSION:** Fruit of *Lycopersicon esculentum* was selected for the assessment of the hepatoprotective activity and is used as culinary and medicinal purpose and is most popular in indigenous system of medicine. The tomato contains higher amount of lycopene, carotene, flavonoids, Carotenoids, Xanthophylls.

**Effect of Paracetamol on Liver Function Tests Parameters and Histopathological Changes in Mice:** Administration of Paracetamol to mice caused severe damage to liver, as evident by both significantly ( $p < 0.01$ ) altered serum biochemical parameters and changes in the hepatic tissues observed during histopathology examination. There was a significant (approx 2-5) times increase in the average levels of SGOT, SGPT, ALP and Total bilirubin from 162, 204, 188 and 13.13 resp. in paracetamol treated animals (group II), reflecting severe hepatic injury (Table 4, Fig. 4).

Histopathological examination of liver section in Paracetamol treated control (Group II) revealed the

area of hydropic changes and degeneration of hepatocytes and congestion of the sinusoids, necrosis of central veins (Fig. 4), which were absent in the section from untreated normal control group (I). Section from normal untreated control group showed healthy liver structure with normal central vein and sinusoids as well as healthy hepatocytes exhibiting regular under surface without any evidence of necrosis.

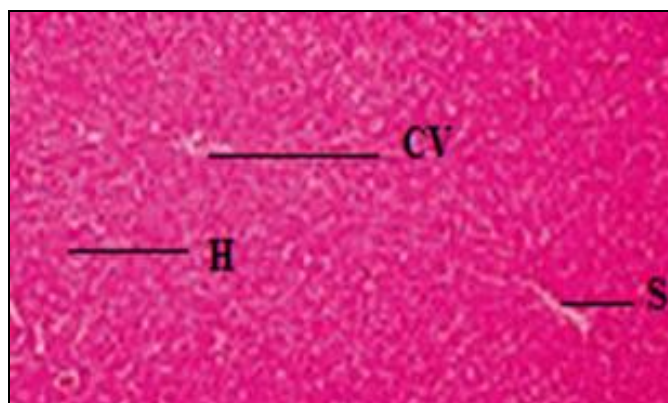


FIG. 5: PHOTOMICROGRAPH OF LIVER SECTION OF CONTROL GROUP OF MICE STAINED WITH HAEMOTAXYLENE AND EOSIN

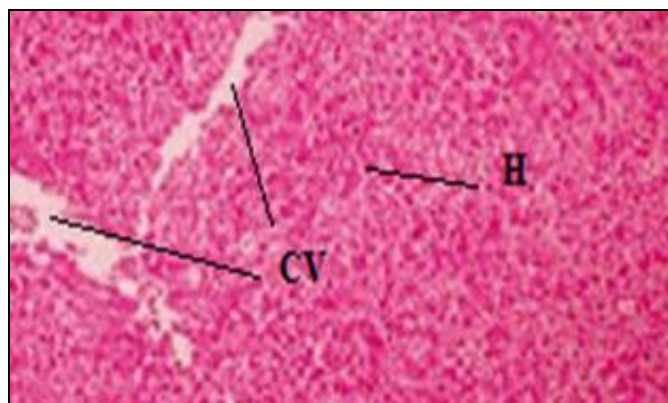
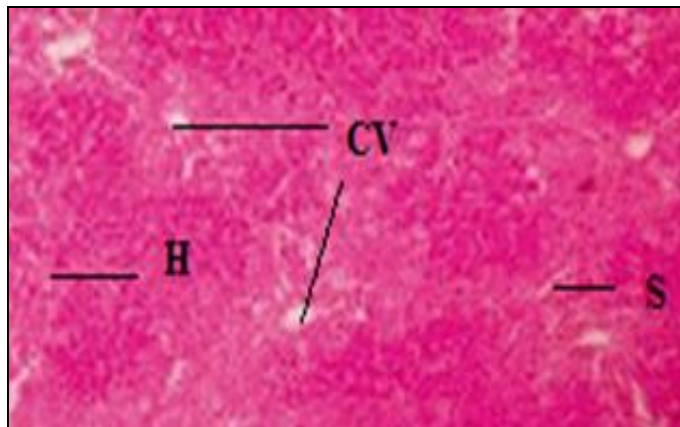



FIG. 6: PHOTOMICROGRAPH OF LIVER SECTION OF PARACETAMOL GROUP OF MICE SHOWING AREA OF HYDROPIC CHANGES AND DEGENERATION OF HEPATOCYTES AND CONGESTION OF THE SINUSOIDS, NECROSIS OF CENTRAL VEIN. SECTION WAS STAINED WITH HEAMOTAXYLENE AND EOSIN

**Effect of Silymarin Liver Function Tests Parameters and Histopathological Changes in Mice:** The administration of Silymarin to mice studies on Paracetamol group showed significant ( $p < 0.01$ ) increase in liver enzyme parameter as compared to control animal (group I). Comparison of group II with silymarin treated mice (Group III) reveals that there was significant decreased in liver enzyme paracetamol from 87.28, 122.6, 96.82, 0.98

respectively as a result of Silymarin treatment. Histopathological examination of liver section in Silymarin treated control (Group III) revealed the recovery of hepatocytes cell and reduced necrosis identified cells as compare to Paracetamol treated group.



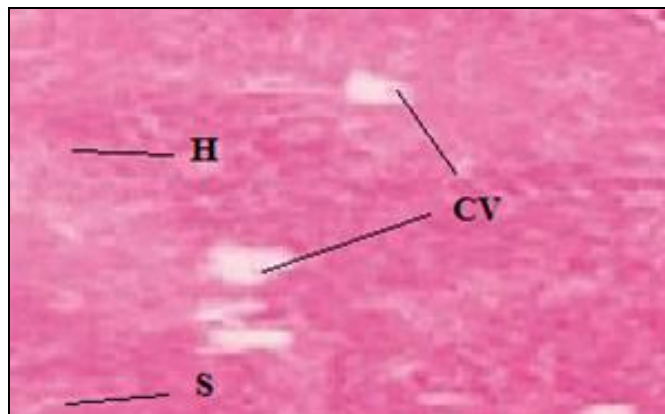
**FIG. 7: PHOTOMICROGRAPHS OF LIVER SECTION OF STANDARD GROUP OF MICE TREATED WITH SILYMARIN SHOWING RECOVERY OF HEPATOCYTES, REDUCED NECROSIS. SECTION WAS STAINED WITH HEAMOTAXYLINE AND EOSIN**



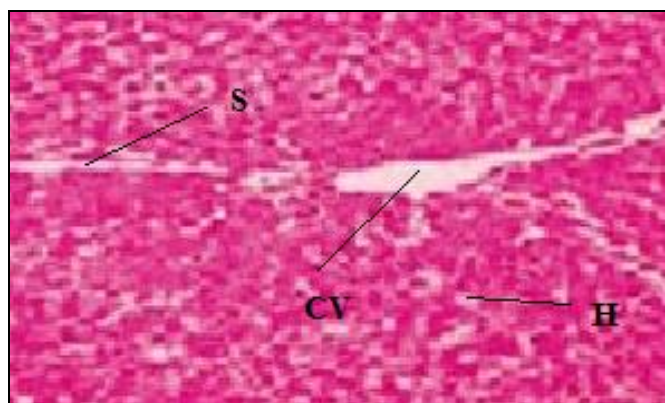
**FIG. 8: PHOTOMICROGRAPHS OF LIVER SECTION OF METHANOLIC-I (NON-LYCOPENE FRACTIONATE) OF MICE SHOWING RECOVERY OF HEPATOCYTES, REDUCED NECROSIS. SECTION WAS STAINED WITH HEAMOTAXYLINE AND EOSIN**

**Effect of Methanolic-I Extract on Liver Function Tests Parameters and Histopathological Changes in Mice:** Organization of concentrate of CCl<sub>4</sub>-III to mice brought about extreme harm to liver, as clear by both altogether ( $p < 0.01$ ) adjusted serum biochemical parameters and changes in the hepatic tissues saw amid histopathology examination. There was a huge increment in the normal levels of SGOT, SGPT,

ALP and Total bilirubin from 167.01, 202.23, 186.37, and 11.13 resp. in CCl<sub>4</sub>-III treated creatures (aggregate VI), reflecting serious hepatic harm. Histopathological examination of liver area of this gathering uncovered the degeneration of hepatocytes, blockage of sinusoids and putrefaction of focal veins.



**FIG. 9: PHOTOMICROGRAPHS OF LIVER SECTION OF METHANOLIC-II (NON-LYCOPENE FRACTIONATE) GROUP OF MICE SHOWING CONSIDERABLE RECOVERY OF HEPATOCYTES, SOME AREA ARE SHOWING RECOVERY NECROSIS. SECTION WAS STAINED WITH HEAMOTAXYLINE AND EOSIN**



**FIG. 10: PHOTOMICROGRAPHS OF LIVER SECTION OF CCl<sub>4</sub>-III EXTRACT (LYCOPENE FRACTIONATE) OF MICE SHOWING AN AREA OF HYDROPIC CHANGES AND DEGENERATION OF HEPATOCYTES, CONGESTION OF THE SINUSOIDS, CENTRAL VEINS AND INFLAMMATORY CELLS**

Abbreviations: H= hepatocytes, S= sinusoids and CV= central vein.

The hepatotoxicity incited by Paracetamol overdose because of its sulfate and glucuronide pathways gets to be distinctly soaked, and more paracetamol is shunted to the cytochrome P<sub>450</sub> framework to create NAPQI. Thus, hepatocellular supplies of glutathione get to be distinctly exhausted, as the interest for glutathione is higher



than its recovery. NAPQI consequently stays in its dangerous frame in the liver and responds with cell layer particles, bringing about across the board hepatocyte damage and passing, prompting to intense hepatic corruption. In creature examines, hepatic glutathione must be drained to under 70% of ordinary levels before hepatotoxicity happens. SGOT, SGPT, ALP, TBIL have been accounted for to be touchy markers of liver damage and decrease level of these compounds related with hepatotoxicity is an unequivocal sign of hepatoprotective activity of the medication.

No lethal impacts for the concentrate utilized as a part of the treatment were seen in the present review. The outcomes inferred that the Methanolic-I (Non-lycopene division) was more successful than the Methanolic-II (Non-lycopene part) extricate. The CCl<sub>4</sub>-III (Lycopene division) was observed to be not compelling in the treatment of the hepatotoxicity. The recuperation of the liver capacities from paracetamol instigated hepatotoxicity may be because of the nearness of Phenolic mixes and flavonoids in non-lycopene portion of methanolic-I and methanolic-II separate.

**Approval:** This study is approved by VNS institute of pharmacy for study and publication. Institutional animal ethical committee (Registration Number. 778/03/c/cpsa).

**ACKNOWLEDGEMENT:** I am thankful to my research institute VNS institute of Pharmacy, Bhopal for research Project.

**CONFLICTS OF INTEREST:** Nil.

## REFERENCES:

- Wallis TE: "Text Book of Pharmacognosy", Ed. 5<sup>th</sup>, CBS Publishers and Distributors, New Delhi 1997; 104-105, 269-272.
- WHO: Quality Control Methods for medicinal plant materials, Geneva 1998; 41-43.
- Nadkarni's KM: Indian Materia Medica 1: 557.
- Handa SS and Kapoor VK: "Textbook of Pharmacognosy" II edition, Vallabh Prakashan, New Delhi 1989; 447-449.
- Trease and Evans: "Textbook of Pharmacognosy," published by Elsevier, New Delhi 285-286.
- Kritikar and Basu: Indian medicinal plant 2<sup>nd</sup> Edition, Published by Bishen sing Deharadun 1: 340.
- Goodman and Gilman's: The Pharmacological Basic of Therapeutics ninth edition published by Mc Graw Hill 1996; 901-903.
- Kokate CK, Purohit AP and Gokhale SB: "Textbook of Pharmacognosy", Nirali Prakashan 422-425.

- Ross and Wilson: "Anatomy, Physiology and Health Education", 9<sup>th</sup> edition 306-330.
- Tripathi KD: Essential of Medical Pharmacology, Jypee Brothers Medical publishers (p) L.T.D, 6<sup>th</sup> Edition 2008; 627.
- International symposium on Hepatotoxicity, Jerusalem, Israel 1973; 122-123.
- Patel T, Roberts LR, Jones BA and Gores GJ: "Dysregulation of Apoptosis as a mechanism of Liver Disease: an overview". Semin. Liver dis. 1998; 18(2): 105-114.
- Ahmed B, Alam T, Varshney M and Khan SA: "Hepatoprotective Activity of two Plants belonging to the Apiceae and the Euphorbiaceae Family", Journal of Ethanopharmacology 2002; (3): 313-316.
- Jaiprakash B, Hukkeri VI, Lavlahe MS and Kuppast: Comparative study of leaves and bark of *Ailanthus excels roxb* for Hepatoprotective activity, Indian Drugs 2003; 40(6): 355-357.
- Kamath JV and Rana AC: Pharmacological activities of ethanol extract of *Calotropis procera* roots. Indian Drugs 2003; 40: 292-295.
- Jain SK, Sinha BK and Saklani A: "Medicinal plants known among tribal societies of India. Ethnobotany" 1: 92.
- Allen TF: Handbook of Materia Medica and Homeopathic Therapeutics. Jain Publishers (P) Ltd., New Delhi 1994; 251.
- The Ayurvedic Pharmacopoeia of India, 1<sup>st</sup> edition, Government of India, Ministry of Health and Family Welfare, New Delhi 2003; 4(1): 132- 133.
- Vogel HG: Drug Discovery and Evaluation, Pharmacological Assays, 2<sup>nd</sup> ed. Springer-Verlag Berlin Heidelberg, New York 2002; 435.
- Turner RA: "Screening Methods in Pharmacology" Academic Press, New York 1965; 70, 75, 78, 164.
- Mehta RS, Shankar MB, Geetha M and Saluja AK: "Hepatoprotective Effect of *Cyperus rotundus* on Paracetamol induced enzyme activity". Indian journal of Natural Product 2004; 20(3), 12-16.
- Jose JK and Kultan R: "Hepatoprotective activity of *Embelia officinalis* and chavaprash" Journal of Ethanopharmacology 2000; (72)1: 135.
- Sunita S and Nares C: "Effect of *Astercantha longifolia* nees. Against CCl<sub>4</sub> induced liver dysfunction in rats." Indian Journal of Experimental Biology 2005; 43: 68-75.
- Mukherjee PK: "Quality Control of Herbal Drugs", Ed. 1<sup>st</sup>. Business Horizons Pharmaceuticals Publishers, New Delhi 2002; 1-5: 13-14.
- Sunitha S, Nagaraj M and Varalakshmi P: Department of Medical Biochemistry, Chennai revised, Fitoterapia 2001; 72: 516-213.
- Mulla WA, Vijay R and Bhise S: "Hepatoprotective activity of Hydroalcoholic extract leaves of *Asocasia indica*" Govt college of Pharmacy, Vidyanagar, Karad, Revised, 22<sup>nd</sup> jun 2009, Indian Journal of Experimental Biology 2009; 47: 816-821.
- Manjunathan BK: "Hepatoprotective activity of *Pterocarpus Santalinus*., an endangered medicinal plant, S. R. N. M. N. college of Science, Shimoga, Karnataka 2005.
- Srivaidya AR, Sameer V and Dhanapal SP: "In vitro and in vivo evaluation of Hepatoprotective activity of *Gymnema sylvestre*", International journal of pharmaceutical science and nanotechnology 2010; 2(4).
- Vogel HG: Drug Discovery and Evaluation, Pharmacological Assays, 2<sup>nd</sup> ed. Springer-Verlag Berlin Heidelberg, New York 2002; 435.

30. The Ayurvedic Pharmacopoeia of India, 1<sup>st</sup> ed, Part – 1, Government of India, Ministry of Health and Family Welfare, New Delhi 2003; 4: 132-133.
31. Summary of safety studies concluded with synthetic Lycopene Regulatory Toxicological Pharmacological 2003; 37(2): 274-85.
32. Effect of Lycopene beadlets or tomato-powder feeding on CCl<sub>4</sub>-induced hepatoprotective in rats, Phytomedicine 2004; 11: 152-156.

**How to cite this article:**

Choubey A, Yadav R and Alok S: Assessment of hepatoprotective activity by *Lycopersicon esculentum*. Int J Pharm Sci Res 2017; 8(11): 4694-03.doi: 10.13040/IJPSR.0975-8232.8(11).4694-03.

All © 2013 are reserved by International Journal of Pharmaceutical Sciences and Research. This Journal licensed under a Creative Commons Attribution-NonCommercial-ShareAlike 3.0 Unported License.

This article can be downloaded to **ANDROID OS** based mobile. Scan QR Code using Code/Bar Scanner from your mobile. (Scanners are available on Google Playstore)