



Received on 12 October, 2014; received in revised form, 15 December, 2014; accepted, 08 February, 2015; published 01 June, 2015

## PROTECTIVE ROLE OF *TRIBULUS TERRESTRIS* ON ALUMINIUM CHLORIDE - INDUCED REPRODUCTIVE TOXICITY IN THE MALE LABORATORY MOUSE

Praveen Kumar and Poonam Singh\*

Department of Zoology, MMV, Banaras Hindu University, Varanasi, U.P., 221005, India

### Keywords:

Aluminium chloride,  
*Tribulus terrestris*, Testosterone,  
Antioxidant enzymes, Fertility

### Correspondence to Author:

**Dr. Poonam Singh**

Associate Professor  
Department of Zoology, MMV,  
Banaras Hindu University, Varanasi,  
U.P., 221005, India.


**E-mail:** poonom@gmail.com

**ABSTRACT:** The present study deals with the efficacy of *Tribulus terrestris* (TT) on aluminium chloride ( $AlCl_3$ ) - induced alterations in the reproductive organs and fertility of the male laboratory mouse. Thirty adult male mice were divided into six groups of five each. Group I served as control while that of II, III and IV received various doses of  $AlCl_3$  (25, 50, 100 mg/kgBW/day, respectively), for 30 days. The mice of groups V and VI were administered with TT (100mg/kgBW/day) only and  $AlCl_3$  (100mg/kgBW/day) along with TT (100mg/kgBW/day) respectively, for the same duration. Only high dose of  $AlCl_3$  (100mg/kgBW/day) - treated mice showed significant reductions in the body weight, sex organs relative weight, sperm count, motility, viability, epididymal sialic acid, seminal vesicular fructose, serum testosterone, antioxidant enzymes (SOD, Catalase, GPx), mating ability and fertility. However percentage of abnormal spermatozoa in the epididymis and level of testicular cholesterol and MDA were significantly increased. Dose-dependent regressive histological changes in the seminiferous tubules and the Leydig cells were also noticed. Supplementation with TT in high dose of  $AlCl_3$  - treated mice resulted in noticeable restorations in all the studied parameters as compared with only  $AlCl_3$  - treated mice. The results thus indicated the protective role of TT against  $AlCl_3$ -induced adverse effects on the male reproductive organs and the fertility.

**INTRODUCTION:** Herbal extracts are extensively used for the treatment of various diseases as these are natural and relatively safe with minimum or no side-effects. Therefore, intense research is growing for the analysis of plant products which are beneficial for human health. Recently, Abirami and Rajendran<sup>1</sup> have reported the occurrence of more than 35,000 plant species, being used for medicinal purpose. *Tribulus terrestris*, a perennial ground spreading herb of family Zygophyllaceae, is widely distributed in many tropical and moderate areas of the world, including U.S. and Mexico, the Mediterranean region, and throughout Asia.

It is one of the well-known traditional medicinal plant with multiple beneficial effects such as liver tonic, aphrodisiac, analgesic, astringent, stomachic, anti-hypertensive, diuretic, lithon-triptic and urinary anti-infectives<sup>2</sup>. The fruit extract of TT contains saponins, glycosides, flavonoids, alkaloids, resins, tannin, sugars, steroid and essential oils<sup>3</sup>. TT improves the sexual functions due to presence of protodioscin, a steroidal saponin<sup>4</sup>. Protodioscin is suggested to be effective in treatment of low libido, erectile dysfunction and low seminological indices by elevating the level of testosterone, dihydrotestosterone, dehydroepiandrosterone and dehydroepiandrosterone sulphate<sup>5</sup>.

The flavonoid, another active constituent of the TT, bears antioxidative properties<sup>6</sup>. Bashir *et al.*<sup>7</sup> have reported the stimulating effects of TT on the germinative and endocrine function of the testis producing its precocious development in rat. Efficacy of TT has also been reported under

<p><b>QUICK RESPONSE CODE</b></p> 	<p><b>DOI:</b> 10.13040/IJPSR.0975-8232.6(6).2395-05</p>
<p>Article can be accessed online on: <a href="http://www.ijpsr.com">www.ijpsr.com</a></p>	
<p>DOI link: <a href="http://dx.doi.org/10.13040/IJPSR.0975-8232.6(6).2395-05">http://dx.doi.org/10.13040/IJPSR.0975-8232.6(6).2395-05</a></p>	

various experimental conditions. It protects the testicular injuries in rat caused by cadmium<sup>8</sup> and cypermethrin<sup>9</sup>. The extract of this plant also prevents the cadmium<sup>6</sup>-induced hepatic injury and oxalate – induced renal injury<sup>10</sup> in rat.

Aluminium, a widely distributed metal in the environment, constitutes 8% of the earth's crust<sup>11</sup> and is extensively used in manufacture of cosmetics, cookware, utensils, food additives, toothpaste<sup>12</sup> etc. It is also used in medicines and added to the drinking water for purification purposes<sup>13</sup>.

It is released to the environment by natural process and from various anthropogenic sources. ATSDR<sup>14</sup> reports the distribution of aluminium mainly in bone, liver, brain, kidney and testis. It may impair the fertility in males directly by inhibiting the sperm or testicular function or indirectly by impairing the hypothalamic-pituitary-testicular axis resulting in poor semen quality. Aluminium ingestion in excessive amount leads to accumulation in target organs that damages the testicular tissue in human and animals both<sup>15</sup>. High concentration of aluminium in human testis, seminal plasma, blood and urine is associated with impaired sperm quality and viability<sup>16</sup>. Guo *et al.*<sup>17, 18</sup> have reported aluminium accumulation in the testis leading to necrosis of spermatocytes / spermatids and significant decrease in fertility of the mice. AlCl<sub>3</sub>-induced oxidative stress has also been reported as a contributing factor in testicular injuries<sup>19, 20</sup>.

Efficacy of several synthetic agents such as ascorbic acid<sup>20</sup>, Vit-E<sup>21</sup>, a natural product of honey bee i.e. propolis<sup>15</sup> and certain plant extracts such as of grape seeds<sup>22</sup>, ginger<sup>23</sup> and onion<sup>24</sup> has been reported in minimizing the AlCl<sub>3</sub>- induced reproductive toxicity in the rat. As far known till now, there is no report indicating the protective efficacy of TT against AlCl<sub>3</sub>-induced male reproductive impairments as majority of the populations are in continuous exposure to this metal through various sources. In this background, the present study has been designed to explore the effects of *Tribulus terrestris* on the aluminium chloride – induced reproductive toxicity in the adult male mice.

## MATERIALS AND METHODS:

### Plant and Extract preparation:

The fruits of *Tribulus terrestris* were collected from local market of Varanasi and identified morphologically by Department of Botany, BHU, Varanasi. Coarse powder of shade dried fruits of TT were extracted with 70% ethanol (1:10) in a Soxhlet apparatus and evaporated the extract in water bath at 60°C until a consistent solid material was formed. The extract was stored at 4°C in air tight bag and dissolved in distilled water for the treatment.

### Animals:

Thirty healthy adult (12 weeks old) male mice weighing 20-30g were used in this study. They were maintained in an animal house as per the recommendation from Central Animal Ethical Committee of the University (CAECU) for the care and use of the laboratory animals. The mice were kept under 12h L/ 12h D cycle and ambient temperature. Standard pelleted food and tap water were provided *ad libitum*.

After recording the initial body weights all the animals were randomly divided into six groups of five each. Animals of group I served as control, administered with distilled water while that of groups II, III and IV were administered with aqueous solution of AlCl<sub>3</sub> at the doses of 25, 50 and 100mg/kg BW/day respectively, for 30 consecutive days. The mice of groups V and VI were administered with TT (100mg/kgBW/day) only and AlCl<sub>3</sub> (100mg/kgBW/day) along with TT (100mg/kgBW/day), respectively, for the same duration. Twenty four hours after the last treatment, final body weights of the animals were recorded followed by sacrificing them by cervical dislocation. Testis, epididymis and seminal vesicle of both sides were dissected out, washed in normal saline and processed for the following studies:

### Organs weight:

Wet weights of the testis, epididymis and the seminal vesicle of the left side were recorded to calculate the gonado-somatic index (GSI) by using the following formula:

$$\text{Gonadal weight/total body weight} \times 100$$

**Epididymal sperm assessment:**

Cauda epididymides of five mice from each group were minced thoroughly in the physiological normal saline at 37°C and used for the assessment of motility, viability and count according to the WHO Laboratory Manual<sup>25</sup>. Morphology of the spermatozoa was assessed in the same slide as used for the sperm viability. Sperm abnormality was evaluated by the criteria of Wyrobeck and Bruce<sup>26</sup> and Zaneveld and Polakoski<sup>27</sup>.

**Histological Studies:**

Bouin's fixed testis and seminal vesicle were dehydrated in graded series of ethanol, cleared in xylene and embedded in paraffin wax. Sections of 5µm thickness were cut and stained with Periodic-Acid-Schiff (PAS) reagent followed by counterstaining with Harris Haematoxylin. The stained sections were observed under light microscope.

**Biochemical Studies:**

The concentrations of sialic acid in the epididymis and fructose in the seminal vesicle were estimated by using the methods of Aminoff<sup>28</sup> and Linder and Mann<sup>29</sup>, respectively.

**Antioxidant enzymes analysis:**

Lipid peroxidation (LPO) was measured by thiobarbituric acid (TBA) method<sup>30</sup> that determines aldehyde formed by degradation of hydroperoxide including malondialdehyde (MDA). The antioxidant enzymes e.g. superoxide dismutase, catalase and glutathione peroxidase, were assayed in the testis following the methods of Das et al.<sup>31</sup>, Aebi<sup>32</sup> and Paglia and Valentine<sup>33</sup>, respectively.

**Cholesterol:**

The level of cholesterol was estimated in the testis by using commercial diagnostic kit of ENZOPAK (Reckon Diagnostics Private Ltd.).

**Hormonal analysis:**

Blood was collected by cardiac puncture immediately after sacrificing the animals. Serum was obtained by centrifuging the blood at 4500 rpm for 20 minutes in a cooling centrifuge and stored at -20°C until utilized for the study. The level of

serum testosterone was measured by using ELISA kit (LDN, Germany).

**Mating ability and Fertility:**

Five males from each group were caged individually with two virgin females for overnight and according to presence of vaginal plug and implantation sites in females, the mating ability and fertility of the males were assessed, respectively. The females caged with the treated males were sacrificed by cervical dislocation at day eighteenth of gestation and examined their uteri. The ovaries were removed to count the number of corpus luteum. To determine the total number of implantation sites, the dissected out uteri were placed in 10% ammonium sulfide solution, which stained the hemosiderin pigment of resorbed implanted sites blue black<sup>34</sup>. The numbers of live implants, as well as the pre- and the post-implantation losses were recorded. Pre-implantation loss was calculated by using the following formula:

Number of Corpus luteum – (number of resorbed implants + number of live implants + number of dead implants)

Post implantation loss was equal to the total number of resorbed and dead implants.

**Statistical analysis:**

Data were analyzed statistically by one way ANOVA followed by Newman-Keul's test. Body weight and number of live implants as well as pre- and post-implantation losses were analyzed by using Student's T test. Values were considered significant at P<0.05

**RESULTS:****Body weight:**

Low doses of AlCl<sub>3</sub> (25 and 50mg/kg BW/day) treatment did not induce any alteration in the final body weights of the mice, however a significant decrease was found in the final body weight of the mice treated with high dose of AlCl<sub>3</sub> (100mg/kgBW/day). The final body weights of the mice administered with TT (100mg/kgBW/day) only and AlCl<sub>3</sub>(100mg/kgBW/day) along with TT (100mg/kgBW/day), remained unaltered similar to that of the control (**Table 1**).

**TABLE 1: EFFECTS OF AlCl<sub>3</sub>, TT AND AlCl<sub>3</sub> + TT ON THE BODY WEIGHT**

Groups and treatment	Initial body weight (g)	Final body weight (g)
Gr.I: Control	21.8 ± 0.491	24.4 ± 0.599
Gr.II: AlCl <sub>3</sub> (25mg/kgBW/day)	24.0 ± 1.093	26.4 ± 1.688
Gr.III: AlCl <sub>3</sub> (50mg/kgBW/day)	26.0 ± 1.411	26.4 ± 1.206
Gr.IV: AlCl <sub>3</sub> (100mg/kgBW/day)	24.4 ± 0.399	20.8 ± 0.488*
Gr.V: TT (100mg/kgBW/day)	23.6 ± 0.509	25.8 ± 0.374
Gr.VI: AlCl <sub>3</sub> (100mg/kgBW/day) + TT (100mg/kgBW/day)	25.2 ± 0.799	26.0 ± 0.547

Values are mean ± SEM of five animals

\*Significant difference at P < 0.05

### Organs weight:

Lowest dose of AlCl<sub>3</sub> (25mg/kgBW/day) did not affect the weights of the testis, epididymis and seminal vesicle whereas a significant reduction was noticed in the weight of the epididymis, only in the mice treated with middle dose of AlCl<sub>3</sub> (50mg/kgBW/day). High dose (100mg/kgBW/day) of the treatment induced significant reductions in the weights of the testis, epididymis as well as the

seminal vesicle, as compared with the control. Administration of TT (100mg/kgBW/day) alone was ineffective in inducing any alterations in the weights of these organs, however its administration at the same dose along with high dose of AlCl<sub>3</sub> treatment resulted in significant restorations in the organs weights as compared with high dose of only AlCl<sub>3</sub>- treated animals, thus attained the values similar to that of the control (**Table 2**).

**TABLE 2: RELATIVE WEIGHTS OF THE SEX ORGANS OF THE MICE TREATED WITH AlCl<sub>3</sub>, TT AND AlCl<sub>3</sub> +TT**

Groups and treatment	Sex organs (mg/100g body weight)		
	Testis	Epididymis	Seminal vesicle
Gr.I: Control	388.6 ± 17.665	161.376 ± 8.359	192.72 ± 7.049
Gr.II: AlCl <sub>3</sub> (25mg/kgBW/day)	368.46 ± 17.591	161.94 ± 11.351	173.92 ± 25.349
Gr.III: AlCl <sub>3</sub> (50mg/kgBW/day)	342.602 ± 7.408	130.076 ± 1.998 <sup>a</sup>	153.42 ± 19.402
Gr.IV: AlCl <sub>3</sub> (100mg/kgBW/day)	310.266 ± 22.859 <sup>a</sup>	107.11 ± 4.312 <sup>a</sup>	109.07 ± 3.628 <sup>a</sup>
Gr.V: TT(100mg/kgBW/day)	434.892 ± 39.63	140.304 ± 2.124	201.924 ± 21.259
Gr.VI: AlCl <sub>3</sub> (100mg/kgBW/day) + TT(100mg/kgBW/day)	420.94 ± 14.86 <sup>b</sup>	144.41 ± 4.715 <sup>b</sup>	176.25 ± 18.906 <sup>b</sup>

Values are mean ± SEM of five animals

Significant difference at P < 0.05 (a: I vs IV, b: IV vs VI)

### Epididymal sperm assessment:

Low dose of AlCl<sub>3</sub> (25mg/kg BW/day) neither affected the count nor the motility, viability and morphology of the spermatozoa obtained from the cauda epididymidis. However, significant reductions were noticed in the motility and viability of spermatozoa accompanied by a significant elevation in their percentage abnormality following administration of the middle dose of AlCl<sub>3</sub> (50mg/kg BW/day) treatment.

The sperm count remained unaffected at these doses of the treatment. By contrast, high dose of AlCl<sub>3</sub> (100mg/kg BW/day) treatment resulted in

significant reductions in motility, viability as well as in the count of epididymal spermatozoa with significant elevation in the percentage of abnormal spermatozoa. Oral administration of TT

(100mg/kgBW/day) only, did not alter any of the sperm parameters. Supplementation with TT (100mg/kg BW/day) in high dose of AlCl<sub>3</sub> (100mg/kgBW/day) - treated mice induced significant recovery in the sperm motility, viability, abnormality and count as compared to that of the high dose of only AlCl<sub>3</sub> (100mg/kgBW/day) - treated group, thus attained the control values (**Table 3**).

**TABLE 3: EFFECTS OF  $AlCl_3$ , TT AND  $AlCl_3$  + TT ON THE SPERM PARAMETERS**

Groups and treatment	Sperm characteristics			
	Motility (%)	Viability (%)	Count ( $10^6/ml$ )	Abnormalities (%)
Gr.I: Control	76.4±0.925	75.0±1.658	17.78±.225	20±1.786
Gr.II: $AlCl_3$ (25mg/kgBW/day)	71.8±1.712	73.8±0.859	17.85±0.15	22±0.732
Gr.III: $AlCl_3$ (50mg/kgBW/day)	67.6±1.075 <sup>a</sup>	63.4±0.98 <sup>a</sup>	15.69±0.98	37.4 ±0.509 <sup>a</sup>
Gr.IV: $AlCl_3$ (100mg/kgBW/day)	47.0±1.223 <sup>a</sup>	51.2±2.649 <sup>a</sup>	7.814±0.173 <sup>a</sup>	46.6±1.36 <sup>a</sup>
Gr.V: TT(100mg/kgBW/day)	84.0±1.138	68.0±1.841	17.206±1.397	20.8±0.374
Gr.VI: $AlCl_3$ (100mg/kgBW/day) + TT(100mg/kgBW/day)	71.4±0.747 <sup>b</sup>	67.8±2.241 <sup>b</sup>	17.47± 1.025 <sup>b</sup>	20±0.547 <sup>b</sup>

Values are mean ± SEM of five animals

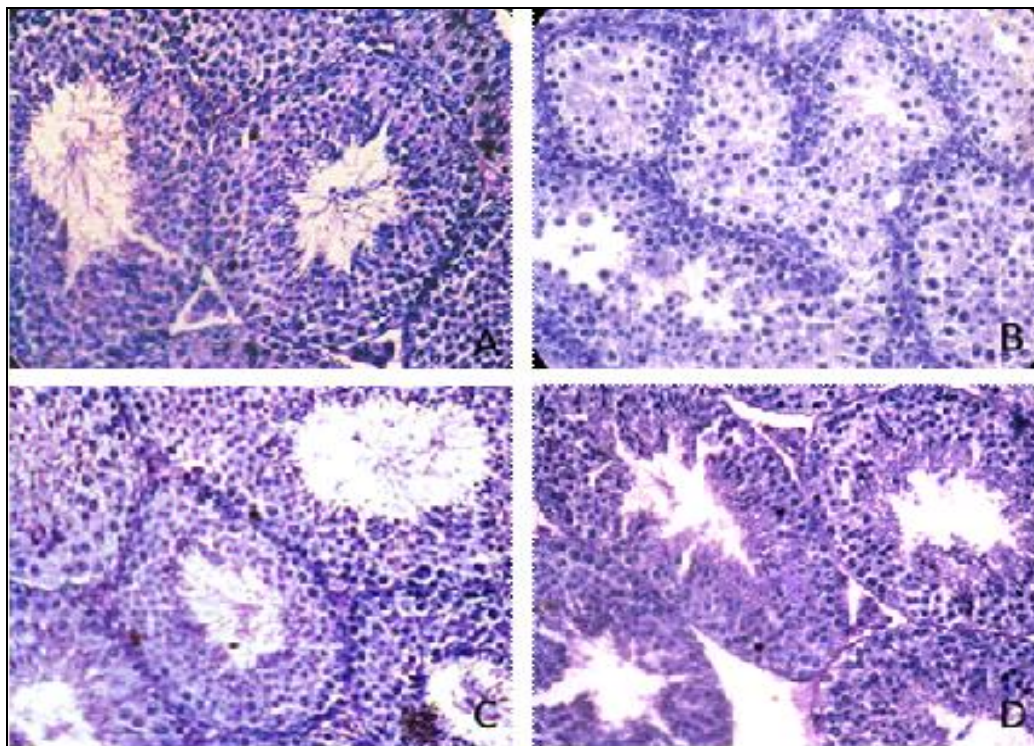
Significant difference at  $P < 0.05$  (a: I vs III and IV, b: IV vs VI)

### Histology of testis:

Histological examinations of the testes of the control, low dose of  $AlCl_3$  (25mg/kgBW/day) and only the TT (100mg/kgBW/day)-treated mice exhibited normal histological features. Administration of the middle dose of  $AlCl_3$  (50mg/kgBW/day) caused mild degenerative changes in seminiferous tubules as indicated by thinning of the tunica propria, loosening of germ cells and mild regressive changes in the Leydig cells. By contrast testis of the high dose of  $AlCl_3$  (100mg/kgBW/day)-treated mouse exhibited noticeable degenerative changes as indicated by

shrinkage of the seminiferous tubules along with thinning of tunica propria, vacuolization, loosening and disorganization of the germ cells.

Lumina of the seminiferous tubules were either devoid of spermatozoa or contained PAS stained cell debris. Atrophy of the Leydig cells were also noticed in the testis of such treated mice. However, complete recovery was noticed in the spermatogenic activity and the Leydig cells morphology following supplementation with TT (100mg/kgBW/day) in  $AlCl_3$  (100mg/kgBW/day)-treated mice (**Fig.1 A-D**).



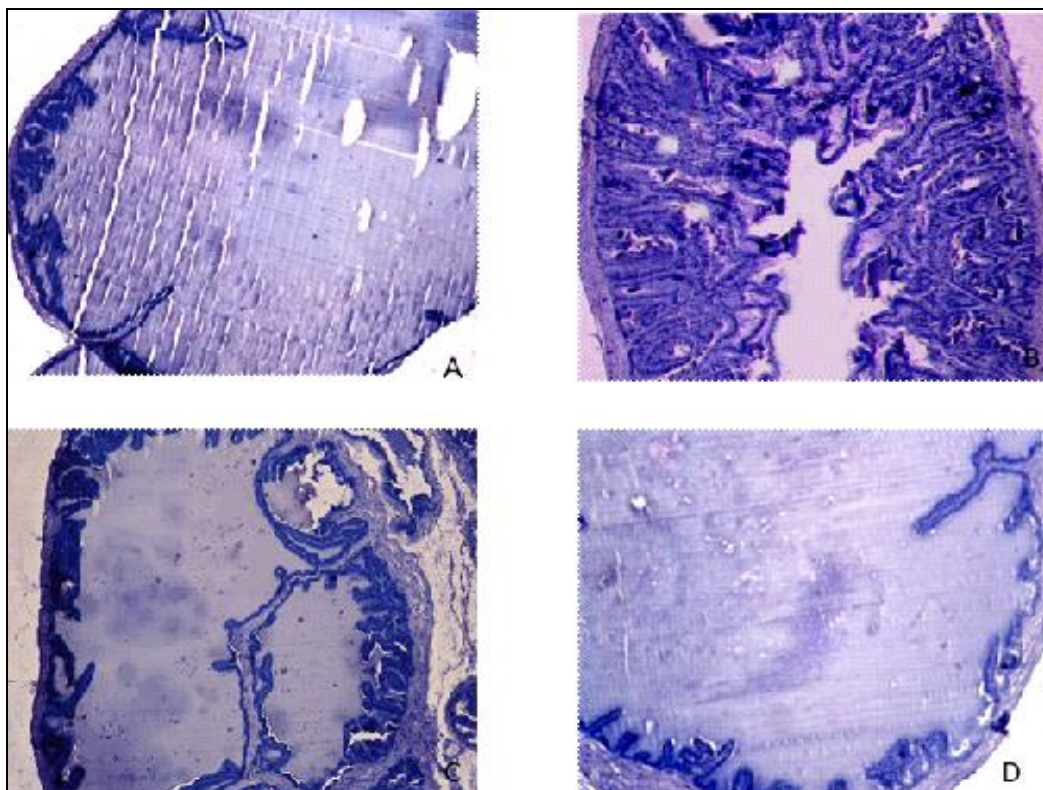
**FIG. 1: (A-D) T.S. OF THE TESTIS OF (A) CONTROL SHOWING NORMAL APPEARANCE OF SEMINIFEROUS TUBULES; (B)  $AlCl_3$  (100 mg/kgBW/DAY)-TREATED MOUSE FOR 30 DAYS SHOWING SHRINKAGE OF THE SEMINIFEROUS TUBULES, DEPLETION AND DISORGANIZATION OF THE GERM CELLS, LUMINA DEVOID OF SPERMATOZOA AND LEYDIG CELLS ATROPHY; (C) TT (100 mg/kgBW/DAY)-TREATED MOUSE PRESENTING NORMAL APPEARANCE OF SEMINIFEROUS TUBULES; (D)  $AlCl_3$  (100 mg/kgBW/day) AND TT(100 mg/kgBW/DAY)-TREATED MOUSE SHOWING THE COMPLETE RECOVERY IN SPERMATOGENESIS AND LEYDIG CELL.**

**Histology of seminal vesicle:**

The seminal vesicle of the low dose of  $\text{AlCl}_3$  (25 mg/kgBW/day)-treated mouse exhibited normal histological features similar to that of the control. The organ of the middle dose of  $\text{AlCl}_3$  (50mg/kgBW/day)-treated mouse showed slight increase in mucosal folding as compared with the control. However, the organ in the high dose of  $\text{AlCl}_3$  (100mg/kgBW/day)-treated mouse presented noticeable regressive histological changes as indicated by an increase in the mucosal foldings

with reduced amount of secretory material in the lumen as compared with that of the control.

Supplementation with TT (100mg/kgBW/day) in  $\text{AlCl}_3$  (100mg/kgBW/day) treated- mouse resulted in complete recovery in the histology of the seminal vesicle as indicated by reduction in the mucosal foldings and distension of the lumen filled with large amount of secretion, comparable to that of the control (**Fig. 2A-D**).



**FIG. 2: T.S. OF THE SEMINAL VESICLE OF (A) CONTROL TO SHOW NORMAL HISTOLOGICAL FEATURES; (B)  $\text{AlCl}_3$  (100 mg/kgBW/DAY)-TREATED MOUSE FOR 30 DAYS SHOWING MARKED REGRESSIVE CHANGES AS INDICATED BY AN INCREASE IN THE MUCOSAL FOLDINGS WITH REDUCED AMOUNT OF SECRETORY MATERIAL IN THE LUMEN; (C) TT (100 mg/kgBW/day)-TREATED MOUSE SHOWING NORMAL APPEARANCE; (D)  $\text{AlCl}_3$  (100 mg/kgBW/day) AND TT (100 mg/kgBW/DAY)-TREATED MOUSE SHOWING COMPLETE RECOVERY IN THE SEMINAL VESICLE AS INDICATED BY REDUCED MUCOSAL FOLDINGS AND ENLARGED LUMEN DISTENDED WITH THE LARGE AMOUNT OF SECRETION**

**Estimation of epididymal sialic acid:**

Administration of  $\text{AlCl}_3$  only at the high dose (100mg/kgBW/day) caused significant decrease in the level of sialic acid in epididymis as compared with the control. However it was restored following supplementation with TT (100mg/kgBW/day) in  $\text{AlCl}_3$  (100mg/kgBW/day)-treated mice, thus attained the values of the control (**Table 4**).

the level of seminal vesicular fructose as compared with the control. However supplementation with TT (100mg/kgBW/day) restored the level of this secretory product in the epididymis of the high dose of  $\text{AlCl}_3$  (100mg/kgBW/day)-treated mice, similar to that of the control (**Table 4**).

**Estimation of seminal vesicular fructose:**

Administration of  $\text{AlCl}_3$  only at the high dose (100mg/kgBW/day) caused significant decrease in

**Antioxidant enzymes:**

The level of testicular MDA and the activities of antioxidant enzymes such as superoxide dismutase, catalase and glutathione peroxidase were comparable in the control and only in the TT

(100mg/kgBW/day)-treated mice. Administration of AlCl<sub>3</sub> only at the high dose (100mg/kgBW/day) caused significant increase in the level of MDA with significant decrease in the activities of testicular superoxide dismutase, catalase and GPx

as compared with the control. However, the altered levels of MDA, SOD, catalase and GPx were restored to the control values, following supplementation with TT (100mg/kgBW/day) in AlCl<sub>3</sub>(100mg/kgBW/day) – treated mice (**Table 5**).

**TABLE 4: EFFECTS OF AlCl<sub>3</sub>, TT AND AlCl<sub>3</sub> +TT ON THE CONCENTRATIONS OF EPIDIDYMAL SIALIC ACID AND SEMINAL VESICULAR FRUCTOSE**

Groups and treatment	Sialic acid (µ mol /100g of tissue)	Fructose(µg/100mg of tissue)
Gr.I: Control	58.8±3.72	166.632±5.247
Gr.II: AlCl <sub>3</sub> (25mg/kgBW/day)	33.212 ± 1.695	162.24±3.417
Gr.III: AlCl <sub>3</sub> (50mg/kgBW/day)	31.626±3.278	159.936±10.614
Gr.IV: AlCl <sub>3</sub> (100mg/kgBW/day)	21.946± 5.24 <sup>a</sup>	114.976±6.183 <sup>a</sup>
Gr.V: TT(100mg/kgBW/day)	61.99±1.22	178.834±29.6
Gr.VI: AlCl <sub>3</sub> (100mg/kgBW/day) + TT(100mg/kgBW/day)	77.272±3.873 <sup>b</sup>	182.966±2.13 <sup>b</sup>

Values are mean ± SEM of five animals

Significant difference at P < 0.05 (a: I vs IV, b: IV vs VI)

**TABLE 5: EFFECTS OF AlCl<sub>3</sub>, TT AND AlCl<sub>3</sub>+TT ON THE ANTIOXIDANT MARKERS**

Groups and treatment	MDA (nmol/mg protein)	SOD (unit/mg protein)	Catalase (µM/min/mg protein)	GPx (unit/mg protein)
Gr.I: Control	0.318±0.042	1.737±0.123	18.1984±3.067	0.084±0.005
Gr.II: AlCl <sub>3</sub> (25mg/kgBW/day)	0.3762±0.005	1.6076± 0.105	17.4322±1.054	0.075±0.007
Gr.III: AlCl <sub>3</sub> (50mg/kgBW/day)	0.396±0.016	1.5202±0.073	14.33±2.382	0.058±0.016
Gr.IV: AlCl <sub>3</sub> (100mg/kgBW/day)	0.539±0.020 <sup>a</sup>	0.9786±0.248 <sup>a</sup>	8.335±1.097 <sup>a</sup>	0.041±0.025 <sup>a</sup>
Gr.V: TT(100mg/kgBW/day)	0.312±0.039	1.768±0.157	34.914 ±4.039	0.158±0.009
Gr.VI: AlCl <sub>3</sub> (100mg/kgBW/day) + TT(100mg/kgBW/day)	0.366±0.012 <sup>b</sup>	1.298±0.08 <sup>b</sup>	17.4082 ±1.647 <sup>b</sup>	0.1144 ±0.013 <sup>b</sup>

Values are mean ± SEM of five animals

Significant difference at P < 0.05 (a: I vs IV, b: IV vs VI)

#### **Cholesterol:**

The level of cholesterol in the testis of AlCl<sub>3</sub> (100mg/kgBW/day)- treated mice was significantly increased as compared with the control. However, its level was significantly decreased in the testis of TT- supplemented AlCl<sub>3</sub>- treated mice, hence attained the values similar to that of the control (**Table 6**).

well as in only TT (100mg/kgBW/day) -treated mice. Administration of only high dose of AlCl<sub>3</sub> (100mg/kgBW/day) caused significant decrease in the level of serum testosterone as compared with the control. However the reduced level of serum testosterone was restored to the control value following supplementation with TT (100mg/kgBW/day) in AlCl<sub>3</sub> (100mg/kgBW/day) – treated mice (**Table 6**).

**Serum testosterone:** The level of serum testosterone remained comparable in the control as

**TABLE 6: EFFECTS OF AlCl<sub>3</sub>, TT AND AlCl<sub>3</sub>+TT ON THE LEVELS OF TESTICULAR CHOLESTEROL AND SERUM TESTOSTERONE**

Groups and treatment	Cholesterol (mg/dl)	Serum testosterone (ng/ml)
Gr.I: Control	21.75±0.50	5.64±0.425
Gr.II: AlCl <sub>3</sub> (25mg/kgBW/day)	23.12±0.22	5.086±0.479
Gr.III: AlCl <sub>3</sub> (50mg/kgBW/day)	24.68±0.29	5.328± 0.135
Gr.IV: AlCl <sub>3</sub> (100mg/kgBW/day)	27.72±0.42 <sup>a</sup>	3.456±0.032 <sup>a</sup>
Gr.V: TT(100mg/kgBW/day)	23.22±0.29	6.082±0.176
Gr.VI: AlCl <sub>3</sub> (100mg/kgBW/day) + TT(100mg/kgBW/day)	22.70±0.38 <sup>b</sup>	5.246± 0.203 <sup>b</sup>

Values are mean ± SEM of five animals

Significant difference at P < 0.05 (a: I vs IV, b: IV vs VI)

**Mating ability and fertility test:**

Mating ability of the males administered with high dose of AlCl<sub>3</sub> (100mg/kgBW) was reduced to approximately 20% as compared with the control. The number of pregnant females impregnated by AlCl<sub>3</sub> (100mg/kgBW/day)-treated males, was significantly reduced. The number of live blastocysts was also decreased with significant

increase in the number of pre- and post-implantation losses in such females. By supplementation with TT (100mg/kgBW/day) in AlCl<sub>3</sub> (100mg/kgBW/day)-treated mice, the mating ability, fertility, the number of live implants as well as the pre- and post-implantation losses were restored to the control values (**Tables 7 and 8**).

**TABLE 7: EFFECTS OF AlCl<sub>3</sub>, TT AND AlCl<sub>3</sub>+TT ON THE MATING ABILITY AND FERTILITY**

Groups and treatment	Males			Females		
	Tested	Mated	Fertile	Tested	Mated	Fertile
Gr.I: Control	5	5	5	10	10	8
Gr.IV: AlCl <sub>3</sub> (100mg/kgBW/day)	5	1	1	10	2	2
Gr.V: TT(100mg/kgBW/day)	5	5	5	10	10	9
Gr.VI: AlCl <sub>3</sub> (100mg/kgBW/day) + TT(100mg/kgBW/day)	5	4	4	10	7	5

**TABLE 8: EFFECTS OF AlCl<sub>3</sub>, TT AND AlCl<sub>3</sub>+TT ON LIVE BLASTOCYSTS AND PRE- AND POST-IMPLANTATION LOSS**

Experimental groups	No. of live blastocysts	Pre-implantation loss	Post-implantation loss
Gr.I: Control	8.4 ± 0.925	1.4 ± 0.509	0.20 ± 0.199
Gr.IV: AlCl <sub>3</sub> (100mg/kgBW/day)	5.2 ± 2.15 <sup>a</sup>	3.4 ± 0.244 <sup>a</sup>	1.4 ± 0.925 <sup>a</sup>
Gr.V: TT(100mg/kgBW/day)	8.8 ± 1.304	1.0 ± 0.446	0.60 ± 0.213
Gr.VI: AlCl <sub>3</sub> (100mg/kgBW/day) + TT(100mg/kgBW/day)	7.8 ± 0.96	1.2 ± 0.83 <sup>b</sup>	0.40 ± 0.244 <sup>b</sup>

Values are mean ± SEM of five animals

Significant difference at P < 0.05 (a: I vs IV, b: II vs VI)

**DISCUSSION:** The present study describes the protective efficacy of *Tribulus terrestris* against aluminium chloride - induced male reproductive toxicity. Oral administration of AlCl<sub>3</sub> at the dose of 100mg/kgBW/day caused significant decrease in the final body weight of the mice as compared with the control. This is consistent with the findings reported in mouse<sup>35</sup>, rat<sup>22</sup> and rabbit<sup>36</sup>. Reduction in the body weight following AlCl<sub>3</sub> treatment may be due to decrease in feed consumption and transient diarrhea<sup>37</sup>. Significant reductions in the relative weight of the testis and epididymis as noticed in the present study are also reported by previous authors<sup>17, 18, 20</sup>. Reduction in the weights of the testis and epididymis may be attributed to the depletion in the germ cells population<sup>38</sup> and spermatogenic inhibition.

Restoration in the body weight and weights of the testis and epididymis following supplementation with TT (100mg/kgBW/day) in AlCl<sub>3</sub>-treated mice may be attributed to the presence of an active phytochemical constituent, protodioscin, which is a

steroidal saponin, bearing androgenic properties<sup>4</sup>. Since androgens are anabolic in nature<sup>39</sup>, therefore, restorations in the body weight and the testicular weight in AlCl<sub>3</sub>-treated mice cannot be ruled out due to existence of androgens present in the fruit extract of TT. Further spermatogenesis is an androgen-dependent process<sup>40</sup>, hence the presence of steroidal protodioscin in TT, possessing androgenic properties might have restored the AlCl<sub>3</sub>-induced reduction in the germ cell population in the seminiferous tubules leading to the recovery in the weights of the testis and thus the epididymis.

In the present study, dose-dependent degenerative changes were observed in seminiferous tubules and Leydig cells resulting in the suppression of spermatogenic activity. Testis of the high dose of AlCl<sub>3</sub> (100mg/kgBW/day)-treated mouse showed shrinkage of the seminiferous tubules, thinning of the tunica propria and necrotic changes presenting lumina either devoid of spermatozoa or contained PAS stained cell debris. Consistent findings have been reported in the mouse<sup>35, 41</sup>. A significant



reduction noticed in the level of serum testosterone following treatment with 100mg/kg/bw/day of AlCl<sub>3</sub> is in agreement with that reported in the mouse<sup>42</sup>. Appearance of degenerated Leydig cells and increased level of testicular cholesterol, a precursor of steroidogenesis, are reflected by reduced level of serum testosterone. Consistent finding has been reported by Chinoy *et al.*<sup>35</sup>.

In our study it might be possible that the aluminium at the high dose would have crossed the blood-testis barrier<sup>43</sup> causing the germ cell death by inducing significant reduction in the level of serum testosterone. Since testosterone is essential for maintenance of spermatogenesis<sup>44</sup>, hence AlCl<sub>3</sub>-induced reduction in the level of this hormone might have resulted in reduction in the epididymal sperm count which is the outcome of inhibited spermatogenic activity.

The inhibited spermatogenic activity with reduced sperm count noticed in our study is in accordance with the findings of Yousef *et al.*<sup>15</sup> and Khattab *et al.*<sup>22</sup>. Significant reductions in the activities of antioxidative enzymes viz. SOD, catalase, GPx and an elevation in lipid peroxidation as reflected by an increase in MDA level, noticed in this study, are in accordance with the findings reported by previous authors<sup>19, 20, 45</sup>. An increased oxidative stress caused by aluminium chloride treatment, as noticed in the present study, might have damaged the Leydig cells resulting in reduced level of serum testosterone which subsequently could have inhibited the spermatogenic activity in the testis and thus sperm count in the epididymis.

Restorations in the levels of serum testosterone, testicular MDA and the activities of antioxidative enzymes following supplementation with 100 mg/kgBW/day of TT in AlCl<sub>3</sub> (100 mg/kgBW/day) treated mice suggest the androgenic<sup>4,46</sup> and antioxidative<sup>47-49</sup> properties, exhibited by protodioscin and flavonoids, respectively, present in its fruit extract, causing recovery in spermatogenic activity.

Restoration in the testicular oxidative stress following TT supplementation has also been reported in cadmium<sup>8</sup> and cypermethrin<sup>9</sup> intoxicated rats. It appears that the flavonoid, an

antioxidative component of TT, might have prevented the free radical production by enhancing the defense system during AlCl<sub>3</sub>-induced testicular stress. This result is in line with the findings of previous authors<sup>22-24, 43</sup> who reported protective potential of flavonoids present in the grape seed, onion and ginger against aluminium-intoxicated testicular injury. Significant reductions in the levels of epididymal sialic acid and seminal vesicular fructose noticed in the high dose (100mg/kg/BW/day) of AlCl<sub>3</sub>-treated mice is consistent with that reported by Chinoy *et al.*<sup>35</sup>

Sialic acid is an essential component for the maintenance of the structural integrity of epididymal membranes and maturation of spermatozoa in the epididymis<sup>35</sup>. Further degenerative changes noticed in the seminal vesicle as indicated by an increase in the mucosal foldings with reduced amount of secretory material in the lumen after AlCl<sub>3</sub> treatment have also been reported by these authors. The decreased level of fructose in the seminal vesicle of such treated mice is reflected by reduced amount of secretory material present in the lumen.

Since the structural and functional integrity of the accessory sex glands in the males are androgen-dependent<sup>50</sup>, therefore, significant decrease in the level of serum testosterone as noticed in our study is deflected by reduced levels of sialic acid in the epididymis and fructose in the seminal vesicle with its regressed histoarchitecture. Significant restorations in the levels of these secretory products of the epididymis and the seminal vesicle following supplementation with TT in AlCl<sub>3</sub>-treated mice indicate its androgenic property.

Significant reductions in the motility and viability, with significant increase in the percentage of abnormal spermatozoa noticed in the epididymis of high dose of AlCl<sub>3</sub>-treated mice is in accordance with the findings of others<sup>15, 22, 23</sup>. Previous reports have suggested the AlCl<sub>3</sub>-induced decrease in sperm motility and viability may be due to reduction in the activity of mitochondrial protein, aconitase<sup>22, 51</sup> which is responsible for the isomerization of citrate to isocitrate in Krebs' cycle, through the intermediate cis-aconitate.

Alteration in the activity of acotinase following aluminium accumulation thus leads to change the mitochondrial functions which may be reflected by the altered sperm motility and viability. Moreover, the observed decrease in the sperm motility may also be due to the reduction in the level of serum testosterone<sup>17, 20</sup>. An increased percentage of abnormal spermatozoa after treatment with AlCl<sub>3</sub> may be attributed to the free radical generation<sup>15</sup>.

Testosterone is an important hormone in stimulating the mating ability<sup>15</sup>. High dose of AlCl<sub>3</sub>-induced decrease in the level of testosterone have thus resulted in reduction in the mating ability leading to significant decrease in the fertility of the male mice. Increase in the pre- and post-implantation losses with decrease in the number of live blastocysts in females impregnated with the high dose of AlCl<sub>3</sub>-treated males is most probably attributed to the significant decline in the level of serum testosterone<sup>15, 37</sup> as well as the poor sperm quality<sup>52</sup>.

Significant recovery noticed in mating ability and fertility of the TT supplemented AlCl<sub>3</sub>-treated males and pre- and post-implantation losses in females impregnated with such males are probably attributed to the presence of steroidal protodioscin implicated in restoring the level of serum testosterone. Presence of flavonoids in TT might have improved the quality of spermatozoa by reducing the oxidative stress in AlCl<sub>3</sub>-treated mice resulting in marked reduction in pre- and post-implantation losses comparable to the controls.

**CONCLUSION:** The results of the present study showed the protective efficacy of the fruit extract of *Tribulus terrestris* against aluminium chloride-induced reproductive toxicity in the male mice. Fruit extract of this plant thus may emerge as an effective herbal remedy in treatment of impaired fertility in the males, induced by certain ubiquitous metals.

**ACKNOWLEDGEMENT:** The first author is thankful to University Grant Commission, New Delhi and Banaras Hindu University, Varanasi, for providing financial assistance to carry out the present work.

## REFERENCES:

1. Abirami P, Rajendran A: GC-MS Analysis of *Tribulus terrestris*. Asian J. Plant Sci. Res. 2011; 1 (4):13-16.
2. Kianbakht S, Jahaniani F: Evaluation of Antibacterial activity of *Tribulus terrestris L.* growing in Iran. IJPT. 2003; 2(1):22-4.
3. Ashwani K, Ashish B: Comparative qualitative and quantitative chemotypic characterization among north indian *Tribulus terrestris*. IRJP. 2012; 3(6): 212-218.
4. Gauthaman K, Ganesan AP, and Prasad RN: Sexual Effects of Puncturevine (*Tribulus terrestris*) Extract (Protodioscin): An Evaluation Using a Rat Model. J Altern Complement Med. 2003; 9 (2): 257-65.
5. Gauthaman K, Ganesan AP, Prasad RN: Aphrodisiac properties of *Tribulus Terrestris* extract (Protodioscin) in normal and castrated rats. Life Sci. 2002; 71: 1385–1396.
6. Lakshmi G D, Kumar PR, Bharavi K, Annapurna P, Rajendar B, Patel P T, Satish Kumar CS V, Rao GS: Protective effect of *Tribulus terrestris linn* on liver and kidney in cadmium intoxicated rats. Indian J Exp Biol. 2012; 141-146.
7. Bashir A, Tahir M, Samee W, Munir B: Effects of *Tribulus Treerstris* on testicular development of immature albino rats. Biomedica 2009; 25: 63 – 68.
8. Rajendar B, Bharavi K, Rao G S, Kishore PVS, Kumar PR, CSV Kumar S, Pankaj Patel T: Protective effect of an aphrodisiac herb *Tribulus terrestris Linn* on cadmium-induced testicular damage. Indian J Pharmacol. 2011; 43(5): 568–573.
9. Sharma P, Huq AU, Singh R: Cypermethrin induced reproductive toxicity in male Wistar rats: protective role of *Tribulus terrestris*. J Environ Biol. 2013; 34(5):857-62.
10. Kamboj P, Aggarwal M, Puri S, single SK: Effect of aqueous extract of *Tribulus terrestris* on oxalate – induced oxidative stress in rats. Indian J Nephrol. 2011; 21(3): 154-159.
11. World Health Organization, WHO. 2009. Chemical Hazards in drinking water- Aluminium (online) last accessed 02. 09. 09 at [http://www.who.int/water\\_sanitation\\_health/dwq/chemicals/aluminiumsum.pdf](http://www.who.int/water_sanitation_health/dwq/chemicals/aluminiumsum.pdf).
12. Abbasali KM, Zhila T, Farshad N: Developmental toxicity of aluminium from high doses of AlCl<sub>3</sub> in mice. The J. Appl. Res. 2005; 5: 575-579.
13. Ochmanski W, Barabasz W: Aluminium-occurrence and toxicity for organisms. Przegl Lek 2000; 57:665–668.
14. Agency for Toxic Substances and Disease Registry (ATSDR), 1990. Toxicological profile for aluminum. US Department of Health and Human Services. Public Health Service.
15. Yousef MI, Salama AF: Propolis protection from reproductive toxicity caused by aluminium chloride in male rats. Food and Chem. Toxicology 2009; 47: 1168-1175.
16. Dawson EB, Evans DR, Harris WA, Powell LC: Seminal plasma trace metal Levels in industrial workers. Biol. Trace Elem. Res. 2000; 74: 97–105.
17. Guo C, LuY, Hsu GSW: The influence of aluminum exposure on male reproduction and offspring in mice. Environ. Toxicol. Pharmacol., 2005a; 20:135-141.
18. Guo C, Huang CJ, Yeh MS, Hsu, and G.S.W: Aluminum induced suppression of testosterone through nitric oxide production in male mice. Environ. Toxicol. Pharmacol. 2005b; 19: 33-40.
19. El- demerdash FM: Atioxidant effect of vitamin E and selenium on lipid peroxidation, enzymes activities and bio chemical parametersin rat exposed to aluminium. J. Trace Elem. Med. Biol. 2004; 18: 113-121.
20. Yousef MI, El-Morsy AM, Hassan MS: Aluminium- induced deterioration in reproductive performance and seminal plasma biochemistry of male rabbits: protective role of ascorbic acid. Toxicology 2005; 215: 97-107.
21. Belgin C, Cengiz Güven M: Vitamin E Protection from Testicular Damage Caused by Intraperitoneal Aluminium. Int. J. Toxicol. 2007; 26 (4): 297-306.

22. Hala AH, Khattab Inas ZA, Abdallaha Gehan M, Kamel: Grape seed extract alleviate reproductive toxicity caused by aluminium chloride in male rats. *J. Am. Sci.* 2010; 6(12):1200-1209.
23. Moselhy WA, Helmy NA, Abdel-Halim BR, Nabil TM, Abdel-Hamid MI: Role of Ginger against the Reproductive Toxicity of Aluminium Chloride in Albino Male Rats. *Reprod Dom Anim.* 2012; 47: 335–343.
24. Ghalehkandi JG, Beheshti R, Maheri Sis N, Ghorbae A: Androgenic effects of Onion (*Allium cepa*. Linn.) Aqueous extract on sperm quantity and viability compared with Zn Sulphate supplementation in the Rats. *Asian J. Exp. Biol.Sci.* 2012; 3(3):506-509.
25. World Health Organization: WHO laboratory manual for the examination and processing of human semen. 5th ed. Geneva, Switzerland: WHO Press 2010; 21-56.
26. Wyrobek AJ, Bruce WR: Chemical induction of sperm abnormalities in mice. *Proc. Natl Acad Sci USA.* 1975; 72(11): 4425-4429.
27. Zaneveld L, Polakoski KL: Collection and physical examination of the ejaculate. In: Hafez ESE, editor. *Techniques of human andrology.* New York: North-Holland Pub, Co, 1977; 147-172.
28. Aminoff D: Methods for the quantitative estimation of N-acetylneuraminic acid and their application to hydrolysates of sialomucoids. *Biochem J.* 1961; 81(2): 384-392.
29. Linder HR, Mann T: Relationship between the content of androgenic steroids in the testis and secretory activity of the seminal vesicle in the bull. *J Endocrinol.* 1960; 21: 341-360.
30. Esterbauer H, Schaur RJ, Zollner H: Chemistry and biochemistry of 4- hydroxynonenal, and related aldehydes. *Free radical. Bio Med.,* 1991; 4: 81-128.
31. Das K, Samanta L, Chainy GBN: A modified spectrophotometric assay of superoxide dismutase using nitrite formation by superoxide radicals. *Ind. J. Biochem. Biophys.,* 2000; 37:201-204.
32. Aebi H: Catalase. In: Bergmeyer H.V., editor. *Methods in enzymatic analysis.* New York; Academic press 1974; 2: 674-84.
33. Paglia DE, Valentine WN: Studies on the quantitative and qualitative characterization of erythrocyte glutathione peroxidase. *J Lab Clin Med.* 1967; 70:158-169.
34. Narotsky MG, Brownie C, Kavlock RJ: Critical period of carbon tetrachloride-induced pregnancy loss in Fischer-344 rats, with insights into the detection of resorption sites by ammonium sulfide staining. *Teratology.* 1997; 56(4): 252-261.
35. Chinoy NJ, Momin R, Jhala D D: Fluoride and aluminium induced toxicity in mice epididymis and its mitigation by vitamin C. *Res. Reprod.* 2005; 38: 115–121.
36. Sallam SMA, Nasser MEA, Yousef MSH, El-Morsy AM, Mahmoud SAS, Yousef MI: Influence of Aluminum Chloride and Ascorbic Acid on Performance, Digestibility, Caecal Microbial Activity and Biochemical Parameters of Rabbits. *Res. J. Agric. & Biol. Sci.* 2005; 1 (1):10-16.
37. Alsayed, AM, Abdel-Rahman Al-Rashidy AH, Ahmed Abd El-Mawla AM: Role of propolis in improving male rat fertility affected with aluminum chloride cytotoxicity. *Spatula DD* 2011; 1(4):189-198.
38. D'souza UJ, Narayana K: Induction of seminiferous tubular atrophy by single dose of 5-fluorouracil (5-FU) in Wistar rats. *Indian J Physiol Pharmacol.* 2001; 45(1): 87-94.
39. Bahrke MS, Yesalis CE: Abuse of anabolic androgenic steroid and related substances in sport and exercise. *Current Opinion in Pharmacology* 2004; 4:614-620.
40. Walker WH: Testosterone signaling and the regulation of spermatogenesis. *Spermatogenesis* 2011; 1:2, 116-120.
41. Mayyas I, Elbetieha A, Khamas W, Khamas WA: Evaluation of reproductive and fertility toxic potential of aluminium chloride on adult male mice. *J. Anim. Vet. Adv.,* 2005; 4: 224–233.
42. Guo CH, Huang CJ, Chen ST, Hsu SW: Serum and testicular testosterone and nitric oxide products in aluminium treated mice. *Environ Toxicol Pharmacol.,* 2001; 10: 53–60.
43. Serah F Ige, Akhigbe RE: The role of *Allium Cepa* on aluminium – induced reproductive dysfunction in experimental male rat models. *J. Hum. Reprod. Sci.* 2012; 5(2): 200-205.
44. Sembulingam K, Sembulingum P: Male reproductive system: In: *Essentials of medical Physiology.* 3rd ed. New Delhi: Jaypee Brothers Ltd; 2004; 371- 418.
45. Guo CH, Huang CJ, Hsu SW: Alteration of trace element distribution and testis ACE activity in mice with high peritoneal aluminium. *Biol Trace Elem Res.* 2002; 86: 145–157.
46. Ahmed AH, Mohammed AA, Ibrahim HH, Abbas AH: Study the Biological Activities of *Tribulus Terrestris* Extracts. *World Academy of Science, Engineering and Technology* 2009; 3:09-24.
47. Amin A, Lotfy M, Shafiullah M, Adeghate E: The protective effect of *Tribulus terrestris* in diabetes. *Ann N Y Acad Sci.,* 2006 1084:391-401.
48. Gauthaman K, Ganesan AP: The hormonal effects of *Tribulus terrestris* and its role the management of male erectile dysfunction - An evaluation using primates, rabbit and rat. *Phytomedicine.,* 2008;15:44–54.
49. Zheleva-Dimitrova D, Obreshkova D, Nedialkov P: Antioxidant activity of *Tribulus terrestris* – A natural product in infertility therapy. *Int J Pharm Sci.* 2012; 4(4): 508-511.
50. Mann T: Secretory function of the prostate, seminal vesicle and other male accessory organs of reproduction. *J Reprod Fertil.* 1974; 37: 179-188.
51. Yousef MI, Kamel KL, ElGuendi, MI, El-Demerdash, and FM: An in vitro study on reproductive toxicity of aluminium chloride on rabbit sperm: The protective role of some antioxidants. *Toxicology,* 2007; 239: 213-223.
52. Atessahin A, Yilmaz S, Karahan I, Pirincei I, Tasdemir B: The effects of vitamin E and selenium on cypermethrin-induced oxidative stress in rats. *Turk. J. Vet. Anim. Sci.* 2005. 29: 385-391.

**How to cite this article:**

Kumar P and Singh P: Protective Role of *Tribulus Terrestris* on Aluminium Chloride - Induced Reproductive Toxicity in the Male Laboratory Mouse. *Int J Pharm Sci Res* 2015; 6(6): 2395-05.doi: 10.13040/IJPSR.0975-8232.6(6).2395-05.

All © 2013 are reserved by International Journal of Pharmaceutical Sciences and Research. This Journal licensed under a Creative Commons Attribution-NonCommercial-ShareAlike 3.0 Unported License.

This article can be downloaded to **ANDROID OS** based mobile. Scan QR Code using Code/Bar Scanner from your mobile. (Scanners are available on Google Playstore)