



Received on 22 January, 2015; received in revised form, 16 March, 2015; accepted, 18 April, 2015; published 01 August, 2015

A REVIEW ON EPIDERMAL MANIFESTATION OF PAPILOMA VIRUS INFECTION IN HUMAN

Yashbir Singh, Rashmi Tripathi, Satyavani Guttula* and Sunil Patel

Department of Bioinformatics, Indian Institute of Information Technology, Allahabad, Uttar Pradesh, India

Keywords:

Papovaviruses,
non-enveloped,
histopathological,
oncogenic, dysplasia,
epidermodysplasia verruciformis

Correspondence to Author:

Satyavani Guttula

Department of Bioinformatics, Indian
Institute of Information Technology,
Allahabad, Uttar Pradesh, India

E-mail: satyavani@iiita.ac.in

ABSTRACT: The Human Papilloma Viruses (HPV) are non-enveloped, small DNA virus, which are responsible for worldwide problem. HPV_S can be associated with different varieties of epidermal manifestations. It belongs to the Papovavirus family. On the basis of oncogenic potential these have been classified as high risk and low risk types of virus. Currently histopathological techniques are widely being used as the diagnostic method for the identification of HPV viral DNA. This article reviews the classification of HPVs and different methods used for the vaccination and diagnosis. The types includes common warts, flat warts, plantar warts, anogenital warts, anal dysplasia and *epidermodysplasia verruciformis*. Vaccines are available for prevention of HPV infection, and recommended vaccination schedules have been outlined.

INTRODUCTION: Human Papilloma Virus (HPV) is a double stranded DNA (dsDNA) virus associated with several epithelial diseases such as condylomata, papillionoma, warts, genital cancer etc. More than 100 HPVs are identified based on genetic sequence of outer coat (capsid) protein layer (L1). HPV is one of the most sexually transmitted virus in both sexes, where the severity varies with geographical location. HPV is roughly divided into two groups the first which infects keratinized surfaces of skin and the another one that infects non-keratinized epithelium (eg. epithelium of mouth, throat, eyes and anogenital tract).

TABLE 1: STRUCTURAL CLASSIFICATION OF HUMAN PAPILOMA VIRUS (HPV)

Genome	dsDNA
Host cells	Keratinocytes of epithelium or moist membrane
Virion	Approximately 8000bp
Symmetry	Icosahedral
Group	Group I
Order	Unranked
Family	Papillomaviridae
Genera	Alphapapillomavirus, Betapapillomavirus, Gammapapillomavirus, Mupapillomavirus, Nupapillomavirus

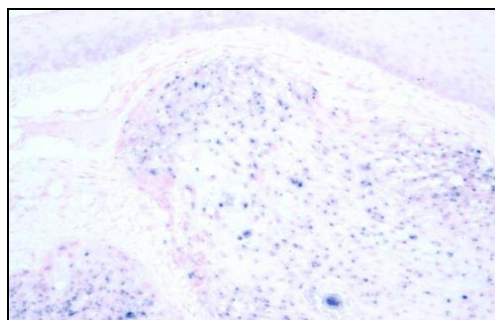


FIG.1: HPV POSITIVE HNSCC (IN SITU HYBRIDIZATION; SOURCE

<http://www.uscap.org/site~/99th/pdf/companion04h03.pdf>

QUICK RESPONSE CODE 	DOI: 10.13040/IJPSR.0975-8232.6(8).3146-50
	Article can be accessed online on: www.ijpsr.com
DOI link: http://dx.doi.org/10.13040/IJPSR.0975-8232.6(8).3146-50	

Each type is distinct, but like every member of this viral group, they possess 8kb virus genome. HPVs have been classified for convenience into those groups which are associated with lesions of mucosal origin and those which are mainly found in cutaneous lesions. A benign tumour is a mass of cells that lacks the ability to infect neighbouring cells¹, while cancerous lesions are those which invade surrounding tissues. Insistent type infection with HPV is absolutely established as a necessary cause of the cutaneous infection. The molecules key to initiation and progression to the infection are oncoprotein E6 and E7 which act initially by removing the negative regulation growth of the host cell. HPV transmission by sexual contact is a responsible for the infection and cervical lesions as well as acts as the same risk factors for other sexually transmitted disease. Mostly sexual partners associated with genital HPV infection and other marks of sexual behaviour, reproductive activity, heredity, immune and smoking habit also subscribe in the same way progressing towards the development of cervical cancer.

In this review, we have discussed detail aspects of the biological and natural history of the virus, structure of HPVs, viruses interaction with the infected host and particular host cell component. The current prevention and treatment options for HPV-related diseases was also concisely reviewed which may prove an essential element for the development of new therapies and effective treatments.

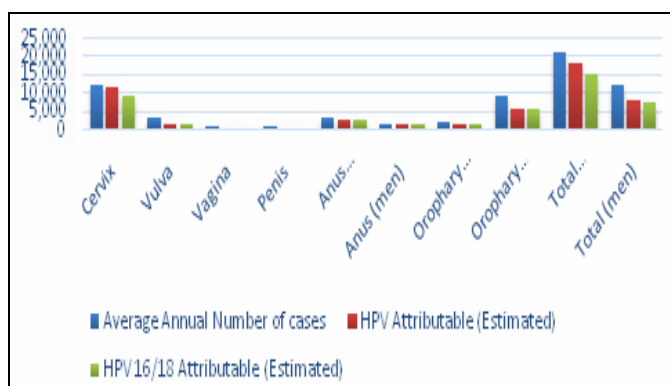


FIG.2: GRAPHICAL REPRESENTATION OF CANCEROUS LESIONS INDUCED BY HPV AND NON HPV² SYMPTOMS AND HPV TYPES

1) Common Warts:

These papulonodules are most often seen on the hands, arms and legs are known as common warts.

The morphology varies from smooth sessile lesions to large pedunculated lesions. These are particularly common in children due to frequent skin-to-skin contact. These are also common in another group of people handling meat poultry and fish^{3, 4}. They occur in subtypes of HPV 2, 7, 22 where HPV2 is most frequently seen in all viral types. HPV2 virus is common cause of condyloma in young children and infants. Ablative methods are surgical excision and destruction by electro desiccation, laser or liquid nitrogen vesicants such as cantharidine alone or in combination with podophyllin are more effective making them a good choice for treating children⁵. Topical medical therapy includes antiviral agent like 5-FU, retinoic acid, podophyllin, podofilox which should be taken once or twice in a day.

2) Plantar Warts:

In this lesions, thickness is remarkable, infected tissue takes more time to get cured compared to other warts occurring in non-acral skin area^{6, 7}. HPV types are known to cause plantar warts, recognized clinically as HPV1, 2, 4, 63. Liquid nitrogen may be applied to small early lesions to prevent it from spreading. Topical 10% formalin may be used twice in a day. A mixture of 5% 5-FU and 0.05% retinoic acid may be used to resist large lesions.

3) Flat Warts:

Warts of this type are dozens of elevated subtle papules 2-4 mm in diameter found on the surface less than a millimetres^{8, 9}. These are caused by HPV3, 8, 10 and occasionally by HPV2. A mixture of 5% 5-FU, 0.05% retinoic acid, podophyllin, podoflox may be used.

3) Varrucous Cyst:

It is an uncommon benign epithelial cyst mainly associated to the cystic skin lesion and caused by HPV 60. Radiation method is ineffective and warts can be removed by simple and easy method of excision.

4) Anogenital Warts:

These warts are caused by sexually transmitted infections. Most of the anogenital warts are caused by HPV6, 11, 42, 44 and others. The warts usually develop on the outer skin of the penis and the

vagina. It looks like small, skin coloured lumps on the skin. There is a good chance to go without treatment, about one third of warts disappear by itself within six months. Podophyllotoxin is available as a cream or lotion may be applied twice daily for three or four days. Imiquimod cream is an alternative it may be applied during bed time and washed off 6-10 hours later. Physical treatment includes freezing warts with liquid nitrogen, surgical removal under local anaesthetic and by burning warts by means of laser or electro cauterly.

5) Anal Dysplasia:

It is a starting stage (pre-malignant) when mucosal lining of the anal canal abnormally changes. In this condition lesions take place. It is same as cervical dysplasia. It is caused by HPV 6, 16, 18, 31, 53, 58. In this penetration sex should be avoided and lesions are destroyed by the intense beam of light, 5% of imiquimod cream and 5% of 5-FU cream may be applied on the infected area.

6) Epidermodysplasia Verruciformis:

It is an autosomal recessive disorder of cutaneous immunity. These disorders are caused by more than 15 types of HPV. Warts are typically flat, numerous, subtle and erythematous. In beginning the warts appear to give clinical appearance of tiny vesicular. The warts can involve any area of the body especially arms. Ablative techniques, liquid nitrogen, topical retinoid can be used to clear sun exposed areas which are at more risk for malignant transformation, H2 blockers may be useful in combination with topical therapies.

7) Genital Cancer:

In genital cancer, male genital part and female genital part both are involved. In male testicular cancer, when the abnormality occurs in the testicular cells, penile abnormality takes place. In female, vulvar cancer and cervical cancer causes genital warts and sexually transmitted infections (STIs). It is caused by highest risk and is cured by radiation therapy and surgery.

8) Focal Epithelial Hyperplasia (Oral):

It primarily occurs in children but lesions may occur in middle-aged adults. It takes place inside the lips, inside of the cheeks, side of the tongue and is also known as Heck disease¹⁰. It is caused by

HPV 13, 32. This is a benign condition that heals spontaneously^{11, 12}. Use of topical imiquimod 5% cream has been reported to be successfully effective. Cryotherapy laser ablation also helps in the treatment.

9) Oral Papillomas:

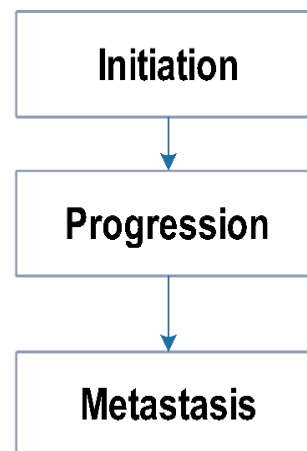
In this condition throat, tongue base and tonsils are included in the oral infection but oral sex is little bit suspected. In this infection symptoms are not immediately visible. It is caused by HPV 6, 7, 11, 16, 32. High levels of radiation that can kill the cancerous cell¹³.

10) Laryngeal Papillomatosis:

It is caused by HPV 6, 11 and also is known as recurrent respiratory papillomatosis. Warty growths occur in the larynx and upper respiratory tract. Vocal function is affected by this disease. It is similar to the common warts. It is more common in both children and adults. Anti-reflux medication, cidofovir, indole-3-carbinol and chemotherapeutic agent helps in the treatment.

Structure of Carcinogenesis:

Cancer can be estimated as the accumulation of 2-6 heritable abnormalities that work in concert to grow into a fully malignant cell. Infection with a human papillomavirus, particularly a positive risk virus, can account for two potentially serious molecular defects (a) loss of p53, and (b) retinoblastoma protein function. Retinoblastoma protein is a normal protein, a critical component of cell cycle control. It (Rb) in unphosphorylated state binds transcription factors necessary for the progression of cell cycle.



In normal cellular physiology the release of Rb is controlled by cyclin dependent kinase. In case of HPV infection viral protein E7 binds Rb to release more E2F protein¹⁴. Other than Rb, P53 acts as a tumour suppressor gene in viral carcinogenesis. P53 has three important functions:

- Repair of DNA damage¹⁵
- Up regulates gene involved in DNA repair
- Stops cell division¹⁶

Therefore P53 has been termed as “Guardian of Genome”. HPV protein E6 circumvent the P53 and promote ubiquitin mediated P53 breakdown leading to carcinoma.

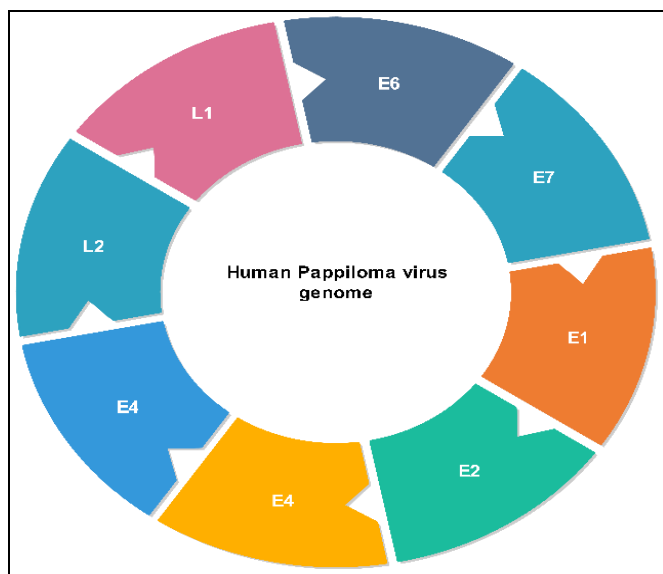


FIG. 2: "E" DESIGNATION INDICATES AN EARLY VIRAL PROTEIN WHICH IS EXPRESSED EARLY IN A VEGETATIVE INFECTION AND "L" DESIGNATION INDICATES A LATE VIRAL GENE.

Indian Layout of the HPV Infection:

Millions of women above age of 15 years in India are suffering from cutaneous Human Papilloma Virus infection (HPV). According to the latest report, annually there are approximately 132,000 newly diagnosed cases and approximately 74,000 deaths known which is 1/3th of the total universal cervical cancer death¹⁶. Women in India face

cumulative life time risks and deaths which is about 2.5 and 1.4% respectively. Among the total population approximately 6.2% women suffer from HPV infection at any particular time. About 76% of cervical cancer in India occurs due to HPV serotype 16 and 18. About 5-25% of sexually transmitted diseases report shows the presence of wart but there is no data for the ano-genital warts in general¹⁷. Now there are many cervical cancer research programmes going on in India. Indian Council of Medical Research has established National Cancer Registry programme which acts like surveillance system in India for cancer, by visiting hospitals and pathology. It collects data and stores information about cancer types and its magnitude¹⁸.

Treatment:

HPV transmission can be reduced but has not been completely eradicated from roots. HPV vaccines helps to prevent the infection from the Human Papilloma Virus. The FDA will examine licensing the vaccines for the people¹⁹. HPV vaccines have been tested in different age group people and has been found to be safe. Gardasil and Cervarix are more effective in preventing infection, both are highly immunogenic vaccines. The efficacy of Gardasil was found to be 89% for the prevention of genital warts and 78% for the anal warts, among the males. This virus vaccines were developed in the early 1990s. Two similar vaccines were approved in the starting years of 2006 and 2009 following extensive clinical testing. Both vaccines stop HPV infection. Implementation of these vaccines is the next provocation.

It is more effective in males. Both vaccines are administered by the intra-muscular routes²⁰. It should be stored at 2-8⁰ C and be protected from light. The second and third doses should be followed two and six months after the first dose, if the HPV vaccine schedule is interrupted then will not be beneficial.

TABLE 2: HPV VACCINES

HPV vaccine	Protection against HPV genotypes (amount in mcg)	Adjuvant	Vaccination age	Schedule	FDA approval
Gardasil	6, 11, 16, 18	Amorphous	i) Routine	0, 2, and 6	Approved

	(20/40/40/40 mcg)	aluminium hydroxyl phosphate sulphate	vaccination in girls of 11-12 years.	months	
Cervarix	16, 18 (20/20 mcg)	Aluminium hydroxide and monophosphoryl lipid A	ii) Health provider's discretion between 9 and 11 years. iii) Catch-up vaccination permitted till 26 years	0, 1, and 6 months	Approved

CONCLUSION: The results after seeing previous results and earlier studies on the role of cutaneous HPV infection specific vaccination is for primary prevention of the HPV. HPV is the most common infectious agent in humans, with a variety of epidermal manifestations. HPV associated lesions vary from place, size and occurrence in different person. Statistical analysis shows its worldwide random explosion. Furthermore studies are required to emphasize its eradication.

ACKNOWLEDGMENT: We thank Shweta Srivastava and Pawan Kumar Pandey for their contributions in preparing the manuscript.

REFERENCES:

- Suryanarayanan, R., Srinivasan, V. R., & O' Sullivan, G: Transtympanic gentamicin treatment using Silverstein MicroWick in Meniere's disease patients: long term outcome. *J Laryngol Otol.*, 2009; 123(1), 45-9.
- Parkin, D. M: The global health burden of infection-associated cancers in the year 2002. *International Journal of Cancer*, 2006; 118(12), 3030-3044.
- Kilkenny, M., & Marks, R.: The descriptive epidemiology of warts in the community. *The Australasian journal of dermatology*, 1996; 37(2), 80-86.
- Rüdlinger, R., Bunney, M. H., Grob, R., & Hunter, J. A. Warts in fish handlers. *The British journal of dermatology*, 1989; 120(3), 375-381.
- Naylor, M. F., Neldner, K. H., Yarbrough, G. K., Rosio, T. J., Iriondo, M., & Yearly, J.: Contact immunotherapy of resistant warts. *Journal of the American Academy of Dermatology*, 1988; 19(4), 679-683.
- Corley, E., Pueyo, S., Goc, B., Diaz, A., & Zorzopulos, J.: Papillomaviruses in human skin warts and their incidence in an Argentine population. *Diagnostic microbiology and infectious disease*, 1988; 10(2), 93-101.
- Jenson, A. B., Sommer, S., Payling-Wright, C., Pass, F., Link, C. C., & Lancaster, W. D.: Human papillomavirus. Frequency and distribution in plantar and common warts. *Laboratory investigation; a journal of technical methods and pathology*, 1982; 47(5), 491-497.
- Fuchs, P. G., & Pfister, H.: Cloning and characterization of papillomavirus type 2c DNA. *Intervirology*, 1984; 22(3), 177-180.
- Majewski, S., & Jablonska, S.: Epidermodysplasia verruciformis as a model of human papillomavirus-induced genetic cancers: the role of local immunosurveillance. *The American journal of the medical sciences*, 1992; 304(3), 174-179.
- Niemiec, B. A. D. V. M.: Oral Pathology. *Topics in Companion Animal Medicine*, 2008; 23(2), 59-71.
- Joffe, R. A.: An assist to the next (10th) edition of Lever's *Histopathology of the Skin*. *The American Journal of dermatopathology*, 2009; 31(1), 26-30.
- Syrjänen, S.: Human papillomavirus infections and oral tumors. *Medical Microbiology and Immunology*, 2003;
- Hay, R., & Adriaans, B.: Bacterial Infections. In G. C. Burns D. A., Breathnach S. M, Cox N. H. (Ed.), *Rook's Textbook of Dermatology*, 2004; 27.16-27.20.
- Munger K., Yee C. L., and Phelps W. C., et al.: Biochemical and biological differences between E7 oncoproteins of the high- and low-risk human papillomavirus types are determined by amino-terminal sequences. *J Virol*, 1991; 65(7):3943-8.
- Sanchez, Y., & Elledge, S. J. Stopped for repairs. *BioEssays : news and reviews in molecular, cellular and developmental biology*, 1995; 17(6), 545-548.
- WHO/ICO Information Centre on HPV and Cervical Cancer (HPV Information Centre). Summary report on HPV and cervical cancer statistics in India, 2007.
- Scheffner M., Werness B. A., Huibregtse J. M., et al.: The E6 oncoprotein encoded by human papillomavirus types 16 and 18 promoted the degradation of p53. *Cell* 63:1129-1136, 1990.
- Ministry of Health and Family Welfare: *Monthly Village Health Nutrition Day*. Health (San Francisco), 2007;
- Bryan, J. T: Developing an HPV vaccine to prevent cervical cancer and genital warts. *Vaccine*, 2007; 25(16 SPEC. ISS.), 3001-3006.
- Shaw, A. R: Human papillomavirus vaccines six years after approval. *Annual review of medicine*, 2013; 64, 91-100.

How to cite this article:

Singh Y, Tripathi R, Guttula S and Patel S: A Review on Epidermal Manifestation of Pappiloma Virus Infection in Human. *Int J Pharm Sci Res* 2015; 6(8): 3146-50. doi: 10.13040/IJPSR.0975-8232.6(8).3146-50.

All © 2013 are reserved by International Journal of Pharmaceutical Sciences and Research. This Journal licensed under a Creative Commons Attribution-NonCommercial-ShareAlike 3.0 Unported License.

This article can be downloaded to **ANDROID OS** based mobile. Scan QR Code using Code/Bar Scanner from your mobile. (Scanners are available on Google Playstore)