



Received on 18 November, 2015; received in revised form, 15 February, 2016; accepted, 18 March, 2016; published 01 May, 2016

A STUDY ON THE EFFECT OF VIRGIN COCONUT OIL ON BENZO(A)PYRENE INDUCED GASTRIC NEOPLASIA IN MICE.

Anu Alex ^{*1}, N. K. Nair ², Shawn Tomy ³, K.Elango ¹ and C. R. Achuthan ⁴

Department of Pharmacology ¹, Department of Pharmacy Practice ², JSS College of Pharmacy, Ooty (JSS University, Mysore), Tamil Nadu, India

Department of Pharmacy Practice ³, RVS College of Pharmaceutical Sciences, Coimbatore, TN, India

Department of Biochemistry ⁴, Amala Cancer Research Centre, Thrissur, Tamil Nadu, India

Key words:

anti-carcinogenicity,
cytotoxicity, virgin coconut oil
(VCO), benzopyrene

Correspondence to Author:

Anu Alex

Research Scholar,
Department of Pharmacology,
JSS College of Pharmacy, Ooty,
Tamil Nadu, India


E-mail: koshy_alex_punthala777@hotmail.com

ABSTRACT: Objective: The present investigation is focused on detecting anti-carcinogenic potential of virgin coconut oil. **Methods:** The virgin coconut oil (VCO) from coconut endosperm was prepared by cold compression method. It was examined then for cytotoxicity by cell exclusion studies using trypan blue dye. Chemical carcinogenesis method using benzopyrene was used to study the anticarcinogenicity of VCO. Curcumin was taken as standard. The low dose and high dose VCO was compared with normal, vehicle and standard treatments. Biomarker studies and histopathological evaluation was also performed. **Result:** The VCO upto 9 μ l showed no significant cytotoxicity. The low dose (4ml/kg body wt) and high dose (8ml/kg body wt) of VCO had significant reduction in gastric Lactate Dehydrogenase (LDH) activity, which is a biomarker for gastric cancer. Histopathological reports also showed very less infiltrations and absence of hyperplasia compared to control. **Conclusion:** The present study showed that, the virgin coconut oil have anti-carcinogenicity property, thus it prevent hyperplasia in the stomach of mice, induced by benzopyrene.

INTRODUCTION: Gastric cancer is one of the most common and life threatening cancer worldwide ¹. It is characterized by alterations in the expression of multiple genes, leading to dysregulation of normal cellular program for cell division and cell differentiation. This results in an imbalance of cell replication and cell death that favours growth of tumour cell population. Cancer development is a multi-step process involving three main phases; initiation, promotion and progression.

Gastric cancer is the third most common cancer worldwide according to an international agency for research on cancer GLOBOSAN database. The need for improvement in therapeutic options for this disorder due to its aggressiveness is evident from the fact that it accounts for second most cancer for cancer death globally ². Various etiological factors including smoking, alcohol, nitrates, and *H. pylori* have been proposed as causative factors for gastric cancer, even though diet has significant association with cancer progression. The involvement of receptors like epidermal growth factors are also reported recently.

Coconut oil has been renowned for its medicinal and nutritional value. Studies on the biological effects of coconut oil revealed that it ameliorates oxidative stress by boosting the antioxidant defense

QUICK RESPONSE CODE	DOI: 10.13040/IJPSR.0975-8232.7(5).1948-55
	Article can be accessed online on: www.ijpsr.com
DOI link: http://dx.doi.org/10.13040/IJPSR.0975-8232.7(5).1948-55	

system, mopping up free radicals and reducing lipid peroxidation³. Further, it suppress microbial and viral activities⁴, promote weight loss and enhance thyroid function⁵. Additionally coconut oil possesses anti-inflammatory and anti-ulcerogenic properties⁶, along with it increases the level of high density lipoprotein (HDL) cholesterol and reduces low density lipoprotein (LDL)³. Copra oil and virgin coconut oil (VCO) are the two main types of coconut oil. Copra oil is extracted from the dried endosperm of coconut fruit whereas VCO is produced by “wet” extraction process from the fresh endosperm⁷. The virgin oil has been reported to be used in many countries including India as edible oil and for cosmetic. Experimental evidence indicates its antioxidant and anti-inflammatory potential⁸. Since inflammation and oxidative stress are involved in carcinogenesis, virgin coconut oil may have better possibility to act as anti-carcinogenic agent. Very little information about its anti-carcinogenic potential is available and no pharmacological research has been reported so far. The present study is aimed to evaluate its effect on benzopyrene induced gastric carcinoma in mice.

MATERIALS AND METHODS:

Chemicals:

Acetic acid, ammonium ferrous sulphate, ascorbic acid, butanol, diethyl ether, hexane, acetone, KCl, malondialdehyde, pyridine, silica, sodium dodecyl sulphate, thiobarbituric acid, trypan blue were of analytical grade and obtained from Merck India. Benzopyrene was procured from Sigma Aldrich(USA). NADH and Sodium pyruvate were obtained from SISCO Research Laboratories, Phosphate buffer saline, Tris-Hcl were prepared in the laboratory according to the standard procedures.

Plant Materials:

The fresh coconuts were collected from Thrissur district of Kerala.

Preparation:

Endosperm of mature coconut was made into a viscous slurry and squeezed through cheese cloth to obtain coconut milk which was refrigerated for 48 h. After 48 h, the milk was subjected to mild heating (50⁰C) in a thermostat oven. Virgin oil thus

obtained was filtered through cheesecloth and was used for the present study.

Cell lines:

Normal cell lines:

Normal spleen was isolated from healthy rat and centrifuged in PBS and spleen cells were obtained. Cells were washed 3 times using PBS below 1000 rpm for 3 min.

Tumor cell lines:

1. Dalton's Lymphoma Ascites (DLA) cells.
2. Ehrlich's Ascites tumour (EAC) cells.

Dalton's Lymphoma Ascites (DLA) and Ehrlich's Ascites Carcinoma (EAC) cells were maintained in the ascites fluid of the peritoneal cavity of mouse. The aspirated tumour cells were washed 3 times with PBS (pH-7.4) and adjusted the cell count to 1×10⁶ cells/ml using haemocytometer. Approximately, 1×10⁶ cells were injected intraperitoneally to develop ascites tumour in mice.

Animals:

Virgin female balb/c mice (6 to 8 weeks old) weighing 25-28 g was taken from Kerala Veterinary University, Mannuthy. The animals were maintained under standardized environmental conditions. They were housed at the animal house facility of Amala Cancer Research Centre in well ventilated polypropylene cages under controlled temperature (22-25⁰C), pressure, relative humidity (60-80%) and light-dark cycle of 12 hrs. They were provided with mice feed (Sai Durga Feeds, Bangalore, India) and water *ad libitum*. All the animal experiments were carried out in Amala Cancer Research Centre by the prior permission of Institutional Animal Ethical Committee (IAEC) (149/99/CPCSEA). All the experiments were conducted according to the rules and regulations of animal ethics committee, Government of India.

METHODS:

Preparation of extract for *in vitro* cytotoxicity assay: The VCO was dissolved in a minimum quantity known volume of ethanol and used for the determination of *in vitro* cytotoxicity.

In vitro cytotoxicity assay by trypan blue dye exclusion method:

Viable cells exclude the dye while non-viable cells take up the dye and will appear in blue colour under magnification by a microscope. Short-term cytotoxicity activity of the VCO was assayed by determining the percentage viability of DLA, EAC and normal spleenocyte cells using the trypan blue dye exclusion technique⁹. DLA and EAC cells were cultured in the peritoneal cavity of healthy albino mice weighing between 25 to 30g by injecting a suspension of cells (1×10^6 cells/ml), intraperitoneally. The DLA and EAC cells were aspirated aseptically from the peritoneal cavity of the mice and centrifuged for 15 min at 1,500 rpm in a centrifuge. The pellet was re-suspended with PBS and the process was repeated three times. Finally, the cells were suspended in a known quantity of PBS and the cell count was adjusted to 1×10^6 cells/ml. The tumour cells (1×10^6 cells/ml) were incubated at 37°C for 3 hrs with different concentrations of drug (25-150 μ g). After incubation, 0.1 ml of trypan blue was added. The cytotoxicity activity was determined by counting the number of dead cells to that of live cells using hemocytometer and substituting in the equation:

$$\% \text{ of cytotoxicity} = \frac{\text{Number of dead cells} \times 100}{\text{Number of total cells}}$$

In-vivo anti-carcinogenic study:

In the present study animals were pretreated with Curcumin (120/kg body wt.), low dose (4ml/kg body wt.) and high dose (8 ml/kg body wt.) VCO for respective groups.

Group I - Normal

Group II - Control (Benzopyrene alone)

Group III- Vehicle (Benzopyrene + Pea nut oil)

Group IV - Standard (Benzopyrene + Curcumin)

Group IV- Low dose (Benzopyrene + VCO 4mL/kg body wt.)

Group V - High dose (Benzopyrene + VCO 8ml/kg body wt.)

After four days of treatment, the animals were given 1.5 mg benzopyrene in 0.2 ml corn oil through stomach tube¹⁰. This dose was repeated

once a week for 4 weeks. Curcumin(120mg/body wt.) was given twice in a week for 4 weeks to standard group. After four weeks, animals were sacrificed and stomach portion was isolated for histopathological studies.

Lactate dehydrogenase assay:

LDH assay was carried out in the gastric wash which obtained from the isolated stomach. Dissolve 2.8ml Tris-Hcl 0.2M buffer of pH 7.3, 0.1 ml 6.6mM NADH and 30mM sodium pyruvate. Incubate in the spectrophotometer for 4-5 mins to achieve temperature equilibrium and establish a blank value, if any. Add 0.1 ml of appropriately dilute gastric wash portion and record $\Delta A_{340}/\text{min}$ from initial linear portion.

$$\text{Units/mg} = \frac{\Delta A_{340}/\text{min}}{6.22 * \text{mg enzyme/ml reaction mixture}}$$

Lipid peroxidation assay:¹¹

The level of lipid peroxidation was measured by the method of Ohkawa *et al.*, (1979). Different mice liver homogenate (10%) containing 30 mM KCl, Tris Hcl buffer (0.04M, pH 7), ascorbic acid (0.06mM) and ferrous ion (0.16mM) in a total volume 0.5 ml for 1 hour. After incubation, 0.4ml of reaction mixture was treated with 0.2 ml SDS(8.1%), 1.5ml thiobarbituric acid (0.8%) and 1.5 ml acetic acid (20%, pH 3.5) distilled water were kept for 1 hour in a boiling water bath at 100°C. After 1 hour, the reaction mixture was removed from the water bath, cooled and added 5ml of pyridine: butanol(15:1 ratio), mix thoroughly and centrifuged at 2000rpm for 10 min. Absorbance of the clear supernatant was measured at 532 nm against pyridine; butanol. Standard graph was obtained by using MDA. The TBARs obtained were obtained from the standard graph and expressed in μ g per mg protein.

Histopathology:

Mice were quickly dissected and the gastric portion were excised and washed with normal saline. The specimens for histopathology were kept in 10% neutral formalin solution. The organ part should be trimmed of any adherent tissue, as appropriate. The above study were performed at Sudharma laboratories, Thrissur.

Statistical analysis:

Each data point is the average of duplicate measurements, with each individual experiment performed in duplicate. Linearity was determined using Microsoft Excel. Data were compared using paired, two-tailed Student’s t-tests, with a value of $p < 0.05$ used to indicate a statistical significance.

RESULTS:

Yield of Virgin Coconut Oil:

Three batches of VCO was prepared from grated coconut. Approximately, 85.6 ± 5.13 oil was obtained from about 746.6 ± 15.27 nut milk. The average yield was found to be 11.3% with respect to the milk obtained.

TABLE 1: YIELD OF VCO IN INDEPENDENT PREPARATIONS

	No. of coconuts	Average wt (kg)	Milk obtained (ml)	VCO obtained (ml)	%yield
Batch 1	4	0.820	730	90	12
Batch 2	4	0.760	760	87	11.4
Batch 3	4	0.840	750	80	10.6

Cytotoxicity of VCO on malignant and non malignant cells:

In the short term cytotoxicity assessment, independent preparations of VCO did not show any sign of toxicity towards DLA and EAC cells. There also no toxicity was observed with normal spleen cells (**Fig.1**). In the untreated control tubes DLA cells (1×10^6 cells) there observed 3% cell death.

No appreciable increase in cell death was noticed with the addition of various concentrations of VCO (5-9 uL) to cell population. In EAC and Spleen cells the similar observation was obtained. In all batch of VCO the results are similar and no promising cytotoxicity were observed. The average of three batches are given below.

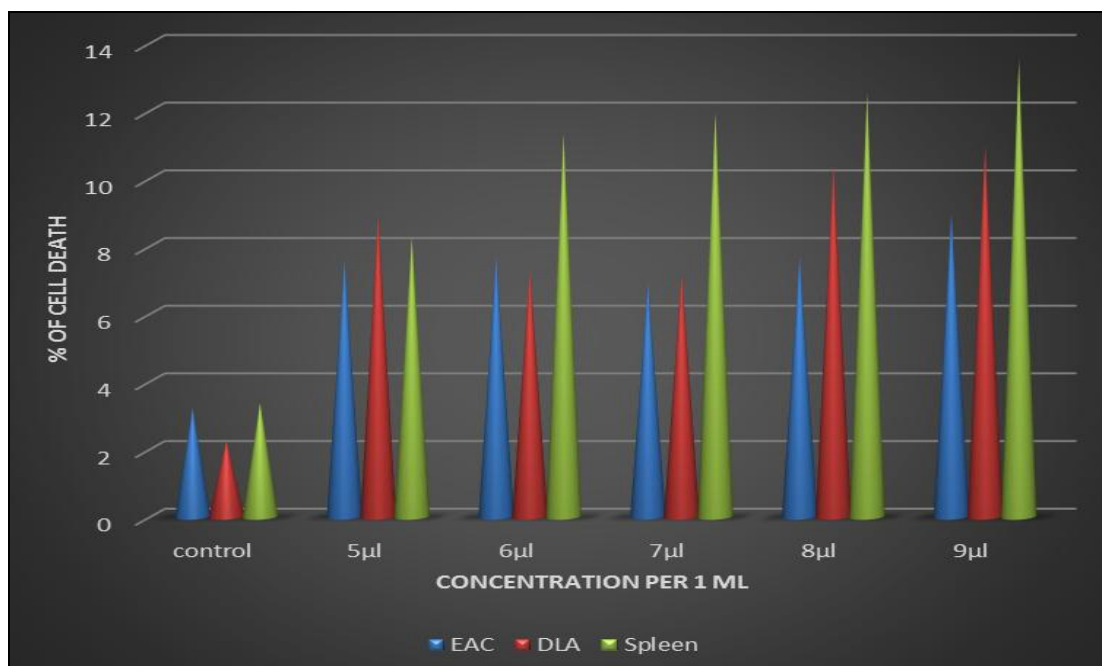


FIG.1: IN VITRO CYTOTOXICITY OF BATCH 1 VCO

Effect of VCO on benzopyrene induced gastric carcinogenesis in female balb/cmice:

Gastric wash analysis. VCO reduced the benzopyrene induced elevation of lactate dehydrogenase activity in the gastric wash:

Compared to normal groups in which the gastric wash LDH activity was 0.2 ± 0.07 U/mg protein benzopyrene treated groups had 1.2 ± 0.37 u/mg

protein. Such a drastic increase in activity was not observed with 4ml and 8ml VCO administered groups. In there the LDH activity were 1.14 ± 0.84 and 1.25 ± 0.05 respectively. In Curcumin treated group, the value was 1.02 ± 0.24 .

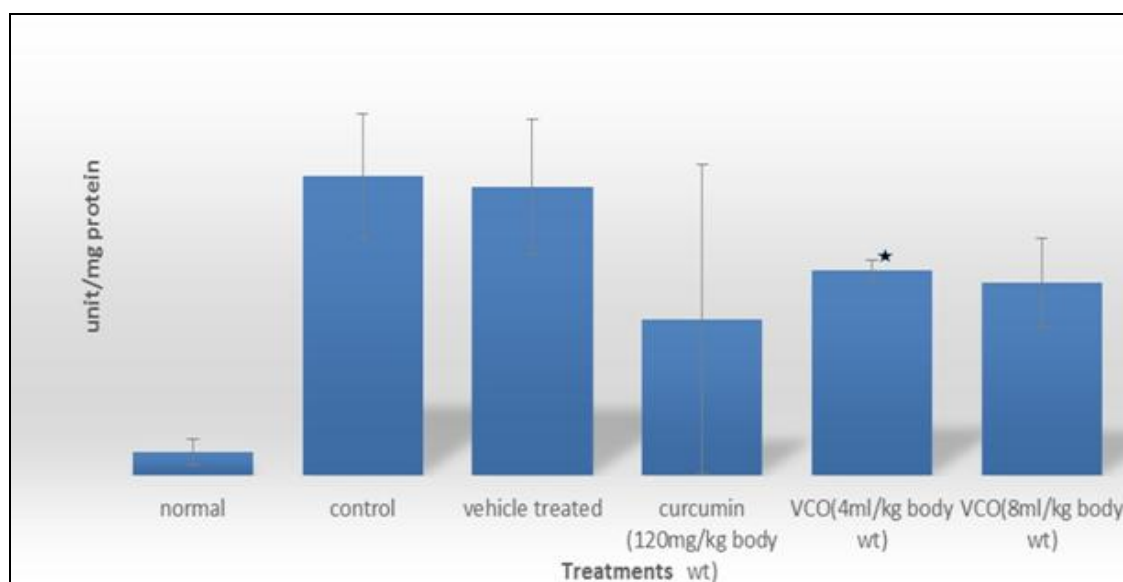


FIG.2: LACTATE DEHYDROGENASE ACTIVITY IN GASTRIC WASH OF MICE (ERROR BARS EXPRESSED AS ± SD OF 6 ANIMALS/GR.) * INDICATE SIGNIFICANCE (P<0.05) OF THE VALUES.

Tissue analysis:

Lipid peroxidation in liver tissue:

The total thiobarbituric acid reacting substances (TBARs) in the liver tissue of normal mice was 0.015ug/mg protein. There was only marginal increase was noticed in benzopyrene alone treated and vehicle treated control groups which was

28.15±3.97, 39.92±6.73. The liver lipid peroxidation of 4ml and 8ml VCO and curcumin were with normal which was 15.42 ± 0.27. Lipid peroxidation for low dose and high dose VCO treatments were 23.76 ± 2.60, 24.74 ± 1.76 respectively.

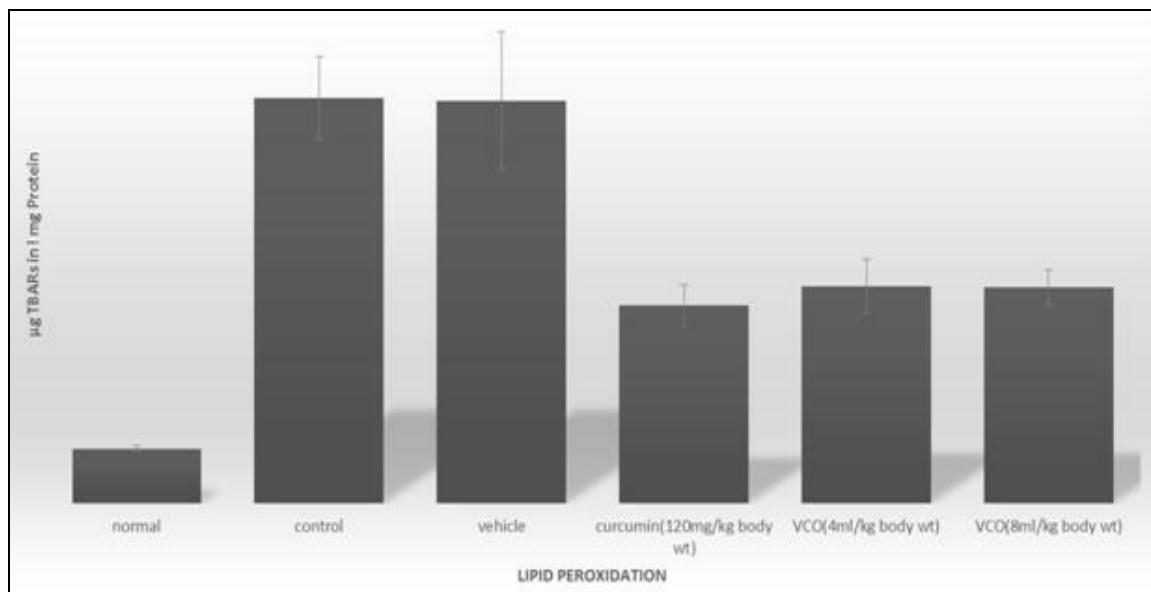


FIG.3: TBARS IN THE LIVER OF MICE EXPOSED TO BENZOPYRENE AND SIMULTANEOUSLY TREATED WITH VCO AND CURCUMIN. DATA ARE EXPRESSED AS µG TBARS PER MG PROTEIN (ERROR BARS EXPRESSED AS ± SD 6 ANIMALS PER GROUP).

Histopathological reports of treated and untreated mice forestomach:

The histopathological evaluation of stomach of normal group animals showed normal mucosal glands which were lined by columnar cells. There

was a mild infiltration of lymphocytes and plasma cells. The serosal layer was also normal. In control groups, received benzopyrene alone, the forestomach section showed a change in complete cell integrity. There was diffuse infiltration by

lymphocytes and plasma cells. The squamous portion showed mild hyperplasia of the epithelium. Vehicle (benzopyrene + peanut oil) treated group, also showed a change in complete cell integrity of fore stomach area. These were similar to benzopyrene alone group. A diffuse infiltration by lymphocytes and plasma cells were also seen. The squamous portion showed mild hyperplasia of the epithelium. Curcumin treated animals showed normal mucosal glands which are lined by columnar cells on histopathological evaluation. There was a diffuse infiltration by lymphocytes and plasma cells. The squamous portion showed mild hyperplasia of the epithelium. In animals received

low dose VCO (4uL/kg body wt.) simultaneously with benzopyrene had forestomach section with normal mucosal glands which are lined by columnar cells. There is a diffuse infiltration by lymphocytes and plasma cells. The squamous portion showed mild hyperplasia of the epithelium. The high dose VCO (8ml/kg body wt)) treated animals showed normal mucosal glands which are lined by columnar cells. There is a diffuse infiltration by lymphocytes and plasma cells. But there was no hyperplasia seen in the squamous portion of epithelium. The muscularis mucosa and muscle layer showed mild inflammatory infiltrate.

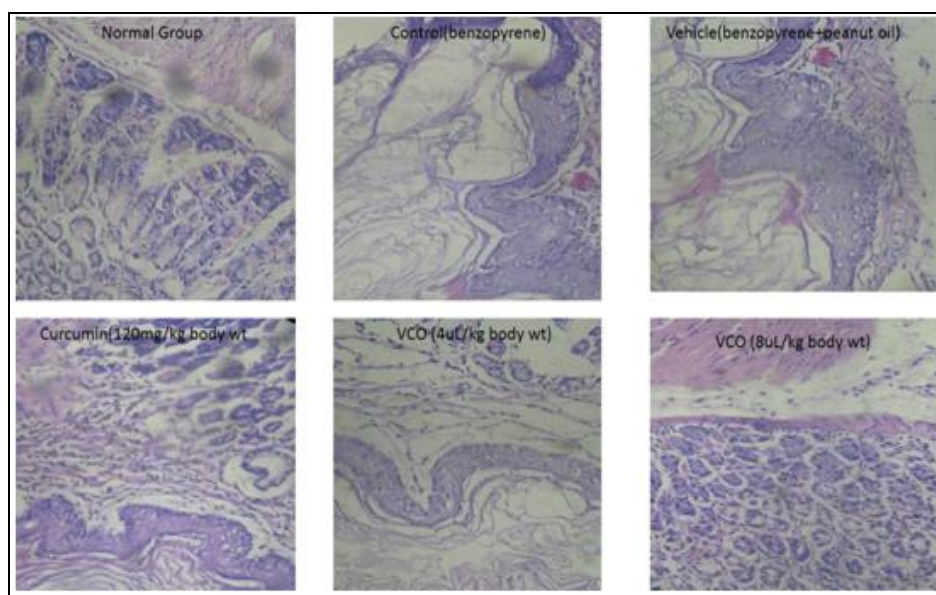


FIG. 4: HISTOPATHOLOGY OF STOMACH OF NORMAL, VEHICLE, CONTROL AND TREATED (TOTAL 6 GROUP) ANIMALS.

DISCUSSION: Virgin Coconut oil has gained much attention due to its health benefits and nutritional values. As a result, use of VCO as food additives has been suggested. Experimental studies have revealed anti-oxidant and hypercholesteremic properties of the VCO. In the present study VCO at various concentrations did not produce cytotoxicity. However, oral administration of VCO could inhibit hyperplasia in the fore stomach of mice received benzopyrene. Compared to Curcumin a known anticancer agent the efficacy of VCO was notable.

Considerable amount of VCO was obtained in different batch preparations yielding approximately 86 mL oil / 747 ml coconut milk. Compared to Kopra Oil VCO is reported to contain tocopherols,

sterols and phospho lipids, in minor quantities. More over it has been revealed that VCO has profound antioxidant activity⁹. The Lauric acid present in the VCO is assumed to fortify the immune system and acts as a natural cholesterol stabilizer. The medium chain saturated fats do not contribute to cholesterol, and are easily digested by the body. This suggest the possibility that the antioxidant and biologically active components present in the VCO in synergism with fatty acids provides the anti carcinogenic effect in the present study.

The VCO in the present study did not show any sign of cytotoxicity towards malignant cells such as EAC and DLA and also to normal spleen cells. This reduce the possibility of VCO to act as anti-

tumor agent. VCO contain unsaturated fatty acids to lesser extent and saturated fats in major proportion. Unsaturated fats are susceptible to oxidation and these oxidized species are known to be cytotoxic to most cancer cells¹². It is thought that antioxidant components in the VCO might have protected unsaturated fats to undergo oxidation which might offer cyto protection. A detail study in this regard may be beneficial in the radiation and chemotherapeutics induced side effects.

Benzopyrene is a strong carcinogen. Benzopyrene undergo metabolic changes in the liver tissue generating free radicals and oxidized metabolites by P450 enzyme system.¹³ The oxidized metabolites of benzopyrene are responsible for its carcinogenic potential. In experimental studies, however 600mg benzopyrene per kg body wt produce significant neoplasia in fore-stomach of mice over 3 months period.¹⁴ In the present study benzopyrene administration (600mg/kg body wt) induce only mild hyperplasia in the fore stomach of experimental mice in a 36 days study. Hyperplasia is the increased cell population due to unregulated cell division and considered a benign condition. It represents the preliminary stage inneoplasia.

Since our present study is only for one month the forestomach area could be in a preliminary stage of carcinogenesis. Hyperplasia if unchecked can lead to neoplasia. In study administration of VCO at 4 and 8 mL per kg body weight of mices did not show any sign of hyperplasia in the fore-stomach. However curcumin a known anticancer agent treated animals had hyperplasia at the fore-stomach region. Further the gastric wash in this group showed normal LDH activity and little peroxidative changes in liver. LDH activity in the benzopyrene administered animals had mild elevation. LDH release indicate the changes in the cellular plasma membrane integrity, thus it is considered as a bio marker for gastric carcinoma.¹⁵

Curcumin could not prevent the increase in the LDH activity. This is a strong indication that VCO could be a possible anti-carcinogenic agent especially against chemical induced carcinogenesis. The activity is seems to be better than Curcumin.

CONCLUSION: The present study shows that Virgin coconut oil prevent hyperplasia in the fore stomach of mice induced by benzopyrene. The activity of LDH, a biomarker for stomach cancer is considerably reduced in VCO treated animals. Together it has been concluded that VCO may have anti-carcinogenic potential. The antioxidant property reported with VCO could be the mechanistic basis for its activity.

CONFLICT OF INTERESTS: All authors have none to declare.

REFERENCES:

1. Power DG, Kelsen DP, & Shah MA: Advanced gastric cancer -Slow but steady progress. *Cancer Treat Rev.* 2010; 36: 384-392.
2. Alberts SR, Cervantes A, Van de Velde CJ: Gastric cancer: Epidemiology, pathology and treatment. *Ann Oncol.* 2003; 14: 31-36.
3. Nevin, K.G. and Rajamohan, T: Virgin coconut oil supplemented diet increases the antioxidant status in rats. *Food Chemistry.* 2006; 99: 260-266.
4. Van Immerseel F, De Buck J, Boyen F, Bohez L, Pasmans F, Volf J, Sevcik M et al.; Medium-chain fatty acids decrease colonization and invasion through hila suppression shortly after infection of chickens with *Salmonella enterica* serovar Enteritidis. *Appl. Environ. Microbiol.* 2004; 70(6): 3582-3587.
5. Bolanle Iranloye, Gabriel Oludare, Makinde Olubiyi: Anti-diabetic and antioxidant effects of virgin coconut oil in alloxan induced diabetic male Sprague Dawley rats. *Journal of Diabetes Mellitus.*2013; 3(4), 221-226
6. Anosike, C.A. and Obidoa, O: Anti-inflammatory and anti-ulcerogenic effect of ethanol extract of coconut (*Cocos nucifera*) on experimental rats. *African Journal of Food, Agriculture, Nutrition and Development.* 2010; 10: 10-16.
7. Cretney, J. and Tafunai, A: Tradition, trade, and technology: Virgin coconut oil in samoa. In *Chains of Fortune: Linking Women Producers and Workers with Global Markets.* 2004; 45-74.
8. Nevin, K.G. and Rajamohan, T: Virgin coconut oil supplemented diet increases the antioxidant status in rats. *Food Chemistry.* 2006; 99: 260-266.
9. Moldeus P, Hogberg J, Orrenius S: Isolation and use of liver cells. *Methods Enzymol.*1978; 52: 60-71.
10. Ayumu Nagahara, Hania Benjamin, Jayne Storkson, Jennifer Krewson, Kuan Sheng, Wei Liu, and Michael W. Pariza: Inhibition of benzo[a]pyrene-induced mouse forestomach neoplasia by a principal flavor component of Japanese-style fermented soy sauce. *Cancer Res.* 1992; 52(7):1754-1756
11. Ohkawa H, Ohishi N, Yagi K: Assay for lipid peroxides in animal tissues by thiobarbituric acid reaction. *Anal Biochem.* 1979; 95: 351-358.
12. Willett WC, Sacks F, Trichopoulos A: Mediterranean diet pyramid: a cultural model for healthy eating. *Am. J. Clin. Nutr.* 1995 61 (6) 1402S-1406S.
13. Kim E, Rundhaug JE, Benavides F, Yang P, Newman RA, Fischer SM: An antitumorigenic role for murine 8S-lipoxygenase in skin carcinogenesis. *Oncogene.* 2005;24: 1174-1187

14. Singh SV, Benson PJ, Hu X, Pal A, Xia H, Srivastava SK et al.; Gender-related differences in susceptibility of A/J mouse to benzo[a]pyrene-induced pulmonary and forestomach tumorigenesis. *Cancer Lett.* 1998; 128: 197-204.
15. Zhi Zhao, Fanghai Han, Shibin Yang, Lixin Hua, Jianhai Wu, and Wenhua Zhan: The Clinicopathologic Importance of Serum Lactic Dehydrogenase in Patients with Gastric Cancer. *Disease Markers.* 2014; 2014: 1-7.

How to cite this article:

Alex A, Nair NK, Tomy S, Elango K and Achuthan CR: A Study on the Effect of Virgin Coconut Oil on Benzo(A) Pyrene Induced Gastric Neoplasia in Mice. *Int J Pharm Sci Res* 2016; 7(5): 1948-55. doi: 10.13040/IJPSR.0975-8232.7(5).1948-55.

All © 2013 are reserved by International Journal of Pharmaceutical Sciences and Research. This Journal licensed under a Creative Commons Attribution-NonCommercial-ShareAlike 3.0 Unported License.

This article can be downloaded to **ANDROID OS** based mobile. Scan QR Code using Code/Bar Scanner from your mobile. (Scanners are available on Google Playstore)