



Received on 29 April, 2017; received in revised form, 16 August, 2017; accepted, 17 September, 2017; published 01 January, 2018

PROLONGED PROSTAGLANDIN INFUSION AND CORTICAL HYPEROSTOSIS IN AN INFANT WITH CYANOTIC CONGENITAL HEART DISEASE

Ammar Ashraf¹, Usman Saeed², Omar Alhadi³, Asad-ur-Rehman⁴ and Sohail Iqbal^{*5}

Department of Medical Imaging¹, Department of Paediatrics³, King Abdul Aziz Hospital for National Guards, Al-Ahsa, Saudi Arabia.

Radiology Department², Royal Blackburn Hospital, ELHT, Blackburn, UK.

Specialty Doctor⁴, Radiology Department, Kettering General Hospital, Kettering, UK.

Cardiac Imaging Fellow⁵, North West Heart Center, UHSM, Manchester, UK.

Keywords:

Prostaglandins(PG),
Intermediate care nursery (ICN)
Neonatal intensive care unit (NICU)

Correspondence to Author:

Dr. Sohail Iqbal

4-Tagore Close,
Manchester, M13 0YS, UK.

E-mail: drsohailiqbal@yahoo.com

ABSTRACT: Prostaglandins (PG) are commonly used in neonates with cyanotic congenital heart diseases to keep the ductus arteriosus patent. The definite treatment for these conditions is surgery. It is occasionally used for longer duration (weeks to months) in preterm babies. Reversible cortical hyperostosis is a relatively recently recognized side effect of prolonged prostaglandin therapy. We describe the case of an infant presenting this complication secondary to prolonged use of PGE1, with typical and extensive radiological findings. The enzymes (prostaglandin 15-OH dehydrogenase & prostaglandin -13 reductase) that catalyze the degradation of prostaglandins are widely distributed in many vascular beds including those of the spleen, kidney, adipose tissue, intestine, liver, testicles and lungs. PGE is normally rapidly inactivated by these tissues, particularly during passage through the lungs. However, infants with cyanotic congenital heart diseases that cause decreased pulmonary blood flow and reduced clearance of PGE may have a higher systemic concentration of PGE. In addition, these patients often receive pharmacologic doses of PGE to maintain the patency of the ductus arteriosus. The resultant higher PGE concentration in the blood may result in osseous changes. However the exact mechanism of cortical hyperostosis is not yet known. It may be a direct, dose-related stimulation of osteoblastic cells.

INTRODUCTION: Prostaglandin-induced cortical thickening seems to be related to duration or dosage of continuous Prostaglandin E1 infusion. Cortical hyperostosis due to PGE treatment can persist for months. This adverse effect is mainly duration dependent but could be dose related as well. After PGE has been discontinued, generally the process is self-limiting with no apparent effect on subsequent bone growth and development.

Case Report: Full term male Saudi baby with birth weight of 3.7 Kg was normally delivered with Apgar score 7 and 8 at 1st and 5th minutes respectively.

In intermediate care nursery (ICN) he developed cyanosis and desaturated to 60% on nasal cannula on 25% oxygen within a few hours of birth. He was shifted to neonatal intensive care unit (NICU), intubated and connected to ventilator. An echocardiogram revealed situs solitus, levocardia, dilated right atrium, small atrioseptal defect (ASD), severe tricuspid valve regurgitation with pressure gradient of 70 mm Hg and small patent ductus arteriosus (PDA) of 2mm Prostaglandin E1 (PGE1) 0.05 microgram / kilogram / minute infusion was

	<p>QUICK RESPONSE CODE</p> <p>DOI: 10.13040/IJPSR.0975-8232.9(1).369-72</p>
	<p>Article can be accessed online on: www.ijpsr.com</p>
<p>DOI link: http://dx.doi.org/10.13040/IJPSR.0975-8232.9(1).369-72</p>	

started on day 3. Baby improved significantly and was extubated on day 5. Chest radiograph immediately after birth showed mild cardiomegaly; however, subsequent chest radiographs at day 3 and 9 showed cardiomegaly with pulmonary plethora. On day 15, PG dose was reduced to 0.04 microgram / kilogram / minute. On day 49, PG dose was further reduced to 0.02 microgram / kilogram / minute.

On day 15 of PG therapy, an isolated elevation of alkaline phosphatase level (688 U/L; Normal \leq 500) was noted which was assumed to be related to PG therapy. Peak elevation of alkaline phosphatase level (1860 U/L) was noted on day 46 of PG therapy. Alkaline phosphatase level returned to normal on day 123; however, again mild elevation was noted in its value on day 140 and 149.

On day 53, chest radiograph revealed periosteal reaction/cortical thickening of bilateral clavicles, ribs and partially visualized humeri which was seen to be progressed on day 113 babygram involving all long bones. Last chest radiograph obtained at day 157, did not reveal any significant interval change in periostitis in the visualized bony skeleton.

Local cardiology and cardiothoracic teams decided not to attempt any corrective surgery because of poor prognosis of this complex pathology and lack of facilities. Patient was discharged on prostaglandin E1 0.02 microgram / kilogram / minute and was sent abroad for surgical intervention if possible after 5 months. Palliative surgery was performed without recovery and patient died at the age of 8 months.

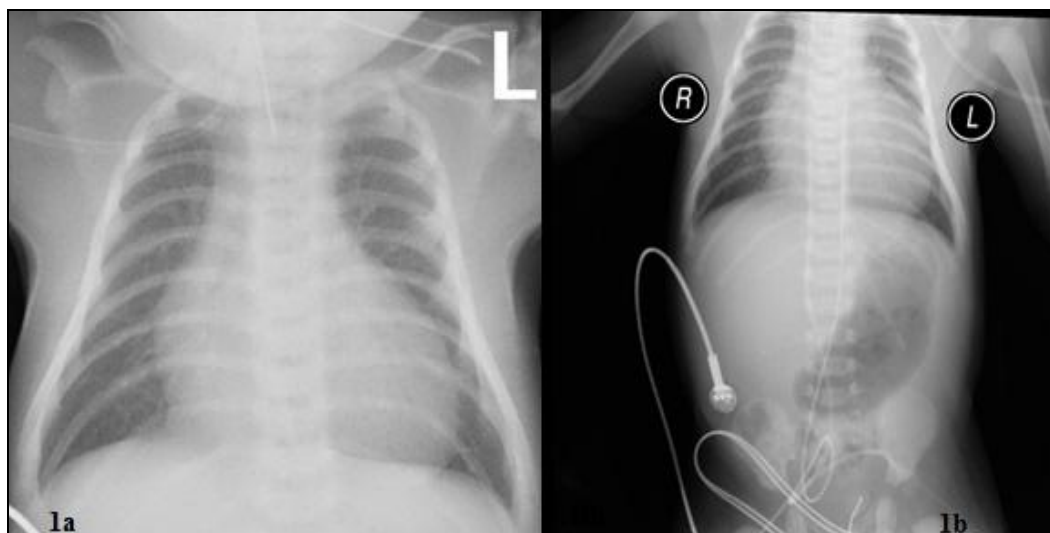


FIG. 1a AND 1b: X-RAY CHEST AND ABDOMEN AT DAY 3 DEPICTING CARDIOMEGALY. NO PERIOSTEAL REACTION ALONG THE RIBS, CLAVICLES OR HUMERII

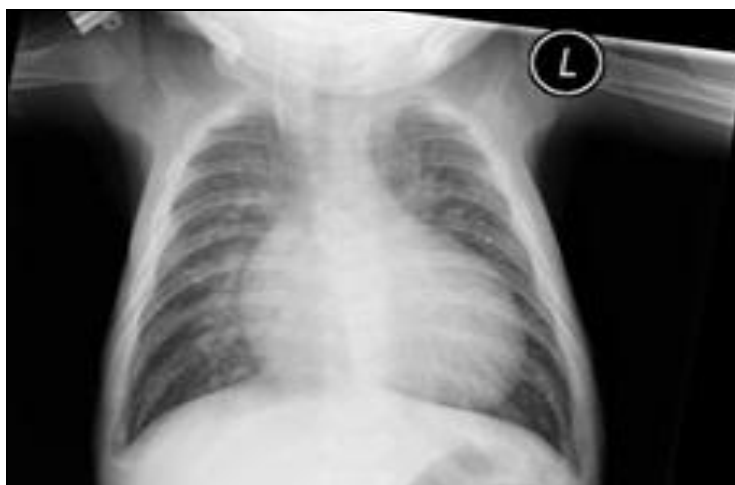

FIG. 2: CHEST X-RAY AT DAY 53, FIRST INCIDENCE OF SMOOTH PERIOSTEAL REACTION ALONG THE RIBS, CLAVICLES AND PARTIALLY VISUALIZED HUMERII

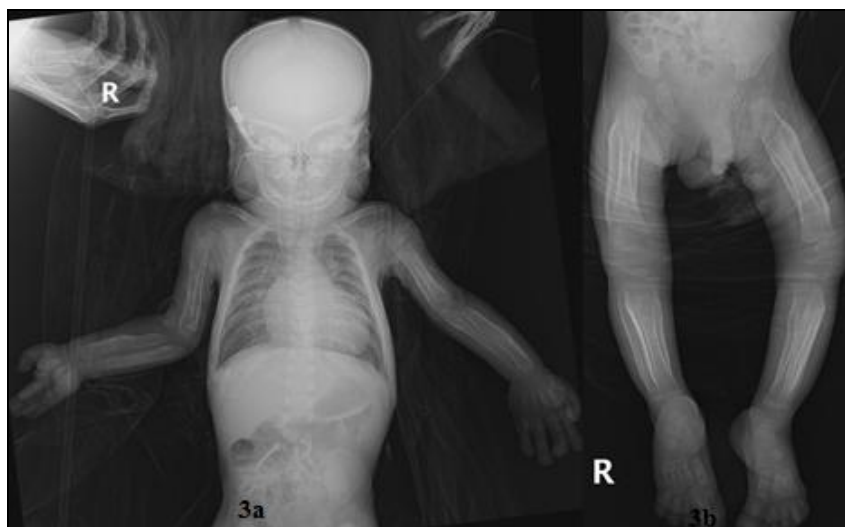

FIG. 3a AND 3b: EXTENSIVE PERIOSTEAL REACTION ALONG THE LONG BONES

DISCUSSION: Elliot used prostaglandins in congenital cyanotic heart disease in 1975 to keep the ductus arteriosus patent¹. E-type prostaglandins (PGE), prostaglandin-E1 (PGE1, injection form) and prostaglandin-E2 (PGE2, oral form) have been documented as being effective in maintaining the patency of ductus arteriosus in neonates with congenital ductal-dependent heart diseases².

PGE1 is usually used as an intravenous infusion in a dose of 0.05-0.1 mcg/kg/minute for a short duration (ranging between 6 hours to 20 days, till surgical intervention is attempted. Recent studies have tried even lower doses in the range of 0.003-0.005 mcg/kg/minute with success³. It is occasionally used for longer duration for weeks to months in preterm babies to allow growth of pulmonary arteries to a size suitable for surgery, low birth weight, infection, absence of a specialized hospital or babies awaiting cardiac transplant⁴.

Common side effects of short-term prostaglandin therapy include apnea, fever, convulsions, rash, skin flushing, vasodilatation with hypotension, necrotizing enterocolitis, diarrhea and gastric outlet obstruction. In rare situations of prolonged use of alprostadil (PGE1), the most important side effects include soft tissue swelling and reversible cortical hyperostosis in the long bones, friability of ductus arteriosus and damage to the pulmonary arterial smooth muscle⁵.

Compared to other side effects of prostaglandins, cortical thickening is considered to be less common

within the few days after commencing prostaglandins. Prostaglandin-induced cortical thickening seems to be related to duration or dosage of continuous PGE1 infusion. The percentage of infants on continuous PGE1 infusion, who develop hyperostosis, increases with duration of PGE infusion from 42% at <30 days to 100% at >60 days. These changes can be seen as early as 9 to 11 days on PGE infusion.

Most commonly affected bones are the long bones of upper and lower limbs, followed by ribs and to a lesser extent, clavicles and scapula. When cortical hyperostosis appears, multiple areas may be involved and it is always symmetrical but does not present uniformly. Pseudo-widening of the cranial sutures due to presence of an un-ossified zone at the margins of cranial sutures with no pathological increase in head circumference had also been reported. Zarur *et al.*, reported thickening of skin and subcutaneous tissues, rough texture of skin, coarse facial features, prominent supraorbital ridges and hypertrichosis⁶.

The severity of periostitis correlates with rise in serum alkaline phosphatase (ALP) activity which in turn correlates with the duration of PGE1 therapy. Nadroo *et al.*, made a similar observation that ALP activity can be used as a marker for PGE1 induced hyperostosis⁷.

Mandible is not involved unlike Caffey's disease where it is almost always involved. Long bones are always symmetrically affected. There is periosteal elevation of diaphysis with no destructive changes.

Metaphysis is spared. Radiological widening of cranial sutures has been reported by some authors without any pathological increase in head circumference. Cortical hyperostosis due to PGE treatment often resolves after cessation of the treatment but can persist for months.

CONCLUSION: Awareness of late complications of prolonged PGE therapy is essential. Hyperostosis is a common side effect of prolonged prostaglandin therapy if it is continued for more than three weeks. Although this is commonly seen with a prolonged use of PGE, it can present as early as 9 days after initiation of therapy. Isolated increase in serum alkaline phosphatase level might be helpful in making a diagnosis of cortical hyperostosis and can be used as a marker for monitoring the activity of the periostitis. Early suspicion and detection may avoid costly and unnecessary laboratory evaluations or inaccurate diagnoses such as child abuse or osteomyelitis, during the resolution phase.

ACKNOWLEDGEMENT: Nil

CONFLICT OF INTEREST: Nil

REFERENCES:

1. Elliot RB, Starling MB and Neutze JM: Medical manipulation of the ductus arteriosus. *Lancet* 1975; 1: 140-42.
2. Hundalani SG, Kulkarni M, Fernandes CJ, *et al.*, Prostaglandin E1 for maintaining ductal patency in neonates with ductus-dependent cardiac lesions (Protocol). *Cochrane Database of Systematic Reviews* 2014; 12. Art. No.: CD011417. Doi: 10.1002/14651858.CD011417.
3. Yucel I, Cevik A, Bulut M, *et al.*, Efficacy of very low-dose prostaglandin E1 in duct-dependent congenital heart disease. *Cardiology in the Young*. 2015; 25: 56-62. doi:10.1017/S1047951113001522
4. Cucerea M, Simon M, Moldovan E, *et al.* Congenital Heart Disease Requiring Maintenance of Ductus Arteriosus in Critically Ill Newborns Admitted at A Tertiary Neonatal Intensive Care Unit, *The Journal of Critical Care Medicine*, 2016; 2: 4.
5. Sen S, Kamath A, Gupta M, *et al.*, A localised soft tissue and bone enlargement in an infant mandible. *BMJ Case Reports*, 2013, bcr2013010291. <http://doi.org/10.1136/bcr-2013-010291>.
6. Zarur FP, d'Almeida LV, Novellino ABC, *et al.*, The Action of Prostaglandins on Ciliary Hypertrichosis: A Case Report of Pachydermoperiostosis. *International Journal of Trichology*. 2014; 6: 25-6. doi:10.4103/0974-7753.136756.
7. Nadroo AM, Shringari S, Garg M, *et al.*, Prostaglandin induced cortical hyperostosis in neonates with cyanotic heart disease. *J Perinat Med* 2000; 28: 447-52.

How to cite this article:

Ashraf A, Saeed U, Alhadi O, Asad-ur-Rehman and Iqbal S: Prolonged prostaglandin infusion and cortical hyperostosis in an infant with cyanotic congenital heart disease. *Int J Pharm Sci & Res* 2018; 9(1): 369-72. doi: 10.13040/IJPSR.0975-8232.9(1).369-72.

All © 2013 are reserved by International Journal of Pharmaceutical Sciences and Research. This Journal licensed under a Creative Commons Attribution-NonCommercial-ShareAlike 3.0 Unported License.

This article can be downloaded to **ANDROID OS** based mobile. Scan QR Code using Code/Bar Scanner from your mobile. (Scanners are available on Google Playstore)