



Received on 21 May 2018; received in revised form, 13 August 2018; accepted, 14 December 2018; published 01 January 2019

## EFFICIENT USE OF TRADITIONAL MEDICINE TO DETOXYFIFY UPPER REPRODUCTIVE ORGANS TOXICITY THAT MAY LEAD TO INFERTILITY

Joseph O. Ezugworie<sup>1</sup> and Obinna O. Uchewa<sup>\*2</sup>

Department of Anatomy<sup>1</sup>, Faculty of Basic Medical Sciences, University of Nigeria Enugu Campus (UNEC), Enugu State, Nigeria.

Department of Anatomy<sup>2</sup>, Faculty of Basic Medical Sciences, College of Medicine, Alex Ekwueme Federal University Ndufu-Alike Ikwo (AE-FUNAI), PMB 1010, Ebonyi State, Nigeria.

### Keywords:

Reprotoxins,  
Traditional, Infertility,  
Antioxidant, Toxicity, Ogbu

### Correspondence to Author:

**Uchewa Obinna Onwe**

Department of Anatomy,  
Faculty of Basic Medical Sciences,  
College of Medicine, Alex Ekwueme  
Federal University Ndufu-Alike, Ikwo  
(AE-FUNAI), Ebonyi State, Nigeria.

**E-mail:** [euchewa1@gmail.com](mailto:euchewa1@gmail.com)

**ABSTRACT:** This study aims at investigating the use of herbal medicine (*F. vogelii*) as a natural antioxidant to detoxify reproductive toxicity. Twenty-five (25) female Wistar rats used in this research were divided into five groups of five (5) rats per group. Group A served as negative control and received feed and water *ad libitum*. It also received formal saline. B and C served as the low (100 mg/kg) and high (300 mg/kg) dose extract groups. They received lead acetate for 14 days after the extract has been administered for first 7 days. Groups D served as the positive control and received only lead acetate 14 days too while E received only the extract for 14 days. The experiment lasted for 28 days including an acclimatization period of 7 days. The positive control group showed a significant increase in SOD activity at  $P \leq 0.01$  while that of group E rats had ovarian SOD closer to group A. Group B and C showed reduced SOD level as well as significant weight gain. The extract presented chemicals capable of removing free radicals generated by toxins in the body. The ovarian and uterine weights were significantly reduced in the positive control group (group D). The histological changes include edema, necrosis, empty optical spaces, denudations, and fatty changes. The extract had a positive effect on the organs against the lead acetate. The results of this study suggest *F. vogelii* leaves can be used as an antioxidant to treat lead reproductive toxicity.

**INTRODUCTION:** Women participation in the menial jobs is on the increase especially in the mining sites, and there is evidence showing the health implications they suffer from occupational exposure to reprotoxins<sup>1, 2, 3</sup>. Therefore, the European Commission presented an analysis of the impacts of a possible amendment of the Carcinogens and Mutagens Directive 2004/37/EC to include reprotoxic substances<sup>4</sup>.

Lead is a toxic metal not essential for bodybuilding, and it is deleterious to every part of the body especially the reproductive systems of both male and female<sup>5, 6</sup>. Lead has been implicated in the reduction of sperm count in males, and it also causes other changes in the volume of sperm when blood lead levels exceed 40 µg/dL<sup>7</sup>.

At this level, motility and morphology of sperm are also affected<sup>8</sup>. The problems caused by lead exposure in the female reproductive organs are more severe and complicated than their male counterparts. Increase in lead toxicity in the body can lead to miscarriages, premature delivery<sup>9</sup>, low birth weight and developmental problems<sup>10, 11</sup>. Blood lead levels in mothers and infants are usually similar to the lead present in mothers' blood passes

<p><b>QUICK RESPONSE CODE</b></p> 	<p><b>DOI:</b> 10.13040/IJPSR.0975-8232.10(1).347-55</p> <p>The article can be accessed online on <a href="http://www.ijpsr.com">www.ijpsr.com</a></p> <p>DOI link: <a href="http://dx.doi.org/10.13040/IJPSR.0975-8232.10(1).347-55">http://dx.doi.org/10.13040/IJPSR.0975-8232.10(1).347-55</a></p>
---	---

into the fetus through the placenta and also through breast milk<sup>12</sup>. Increased calcium intake during pregnancy can help mitigate this phenomenon)<sup>6,13</sup>.

*Ficus* is a genus of about 850 species of woody trees, shrubs, vines and epiphytes in the family of Moraceae<sup>14</sup>. Collectively known as fig trees or figs, they are native throughout the tropics with a few species extending into the semi-warm temperate zone<sup>15</sup>. The common fig (*F. carica*) is a temperate species native to southwest Asia and the Mediterranean region (from Afghanistan to Portugal), which has been widely cultivated from ancient times for its fruit.

The fruit of most other species is also edible though they are usually of only local economic importance or eaten as bush food<sup>15</sup>. The leaves of *F. vogelii* are used locally as vegetables. However, they are extremely important food resources for wildlife and are of considerable cultural importance throughout the tropics as an object of worship. The Igbos refers to *F. vogelii* as ogbu.

Since this herb serves as a delicacy in Ikwo and there is a large lead mining site in this same place, we decided in this research to check the efficacy of the leave in the detoxification of the reproductive organs (ovary and uterus) toxicities as a natural antioxidant.

## MATERIALS AND METHODS:

**Collection of Plant Material:** *F. vogelii* leaves were taken from Ndufu-Alike in Ikwo Local Government Area of Ebonyi State and were authenticated in Botany Department of the University of Nigeria Nsukka (UNN).

**Extract Preparation:** The leaves were dried in a ventilated room for two weeks and grinded to get a fine powder. The powder was soaked in a container with ethanolic were kept in a refrigerator for 48 h. The mixtures were filtered, first, with cheesecloth, and then re-filtered with Whatman no. 1 filter paper (24 cm). The filtrates were separated and concentrated in vacuum using Rotary Evaporator to 10% of their original volumes at 37 °C - 40 °C. These were concentrated using a water bath until a powder was gotten. The extracts were stored in a refrigerator at a very low temperature until it is required for use.

**Ethical Approval:** The ethical clearance for this work was obtained from the Ethics Committee of the Faculty of Basic Medical Sciences, University of Nigeria Nsukka, Enugu Campus (UNEC). There was a strict adherence to International Guidelines for the use of animals in research studies based on European Commission Directive on Animals use<sup>4</sup>.

**Animal Housing:** Twenty five (25) adult female rats were procured from the animal house of the Department of Pharmacology, University of Nigeria Enugu Campus (UNEC) and maintained in the Animal House of Anatomy Department of Faculty of Basic Medical Sciences of the same University. The animals were housed in netted cages, fed with grower's mash and allowed water *ad libitum* with acclimatization period of one week (7 days) was observed.

**Experimental Design:** The animals were grouped as follows and received standard rat's diet containing 0.5% NaCl, 16.8% protein and 46.5% dietary fat, 35.7%, vitamins, other micronutrients and tap water *ad libitum*<sup>16</sup>, throughout the study.

**Group A: Control Group (Negative):** This group received feed as stated above with water *ad libitum*. The rats also received normal saline to expose them to the sane stress as the other groups.

**Group B and C: (Protective Effects of Ethanolic Extract):** The rats in these groups received an ethanolic extract of *F. vogelii* for 7 days and 24 hours later exposed to lead acetate (1.5 mg/kg) for the remaining 7 days.

**Group D: Lead Acetate Solution (Positive):** The rats in this group received 1.5 mg/kg of Lead acetate solution daily for 14 days.

**Group E: (Effect of Ethanolic Extract FV):** The rats in this group received 300 mg/kg ethanolic extract of *F. vogelii* only for 14 days.

**Drug Administration:** The animals were randomly assigned into seven groups (A, B, C, D, and E) after they have been weighed. Groups A and D contained 4 animals per group and received normal saline and lead acetate solution respectively. Group A and C received ethanolic extract for 14 days and lead acetate solution for 7 days. In both groups, B and C were dose-dependent.

Group E received ethanolic extract. The extracts and lead acetate solution were administered by oral intubation using oral gavage (cannula). Administration lasted for 2 weeks (14 days) and 24 h after the last administration the animals were sacrificed, and the uterus and ovaries were removed and preserved for histological studies.

**Phytochemical Screening:** The phytochemical screening was performed using 500 g of the extract. This portion was subjected to quantitative phytochemical screening using the method described by Prashant, *et al.*,<sup>17</sup> and Ene-Obong *et al.*<sup>18</sup>

**Ovarian SOD Activities:** During the sacrifice, one of the ovaries was removed and homogenized with mortar and pestles<sup>19</sup> and then preserved with phosphate buffer. The preserved homogenate was centrifuged and kept under refrigeration before it was sent to a laboratory for the antioxidant check. Superoxide dismutase activity was measured according to the method of Winterbourn *et al.*,<sup>20</sup> as described by Rukmini *et al.*<sup>21</sup> The principle of the assay was based on the ability of SOD to inhibit the reduction of nitro-blue tetrazolium (NBT)<sup>22, 23</sup>. Briefly, the reaction mixture contained 2.7 ml of 0.067M phosphate buffer, pH 7.8, 0.05 ml of 0.12mM riboflavin, 0.1 ml of 1.5mM NBT, 0.05 ml of 0.01M methionine and 0.1 ml of enzyme samples.

We made sure that the tubes were uniformly illuminated by placing it in air aluminium foil in a box with a 15W fluorescent lamp for 10 min. Control without the enzyme source was included. The absorbance was measured at 560 nm<sup>24, 25, 26</sup>. One unit of SOD was defined as the amount of enzyme required to inhibit the reduction of NBT by 50% under the specific conditions.

**Histological Study:** At the end of 28 days, the animals were starved overnight and anesthetized before decapitating and sacrificing them<sup>27</sup>. After sacrificing and dissecting the animals, the uterus and ovaries were removed, weighed and immediately fixed in bouin's fluid for routine histological procedures. These tissues were processed and embedded in paraffin wax. The thin sections (5-6  $\mu$ m) were obtained and stained using hematoxylin and eosin (H and E) and were examined under a light microscope to determine the histological changes caused by the toxicity.

**Statistical Analysis:** Data from the study were analyzed using descriptive statistics and presented as Mean  $\pm$  Standard Error of Mean (SEM). The statistical significance level was established at a value of  $P \leq 0.05$  (\*) or  $P \leq 0.01$  (\*\*). The data were compared with those for negative control and positive control groups. Inferential statistics of paired student's t-Test was adopted with the aid of the Statistical Software Package (SPSS) version 20.0.

## RESULTS:

**TABLE 1: TABLE SHOWING THE WEIGHT (g) OF ANIMALS THAT RECEIVED ETHANOLIC EXTRACT OF *F. VOGELII* AND LEAD ACETATE SOLUTION DURING THE PERIOD OF THE RESEARCH**

S. no.	Groups	No. of Animals	Weeks (Mean $\pm$ SEM)		
			First (g)	Second (g)	Third (g)
1	A	5	139.25 $\pm$ 12.07	150.05 $\pm$ 12.52*	152.83 $\pm$ 13.85**
2	B	5	155.15 $\pm$ 8.10	157.48 $\pm$ 9.40*	155.78 $\pm$ 10.26
3	C	5	121.60 $\pm$ 4.43	128.53 $\pm$ 4.97*	127.00 $\pm$ 4.78*
4	D	5	163.65 $\pm$ 12.15	165.55 $\pm$ 5.14	158.78 $\pm$ 5.71+
5	E	5	114.58 $\pm$ 2.02	116.60 $\pm$ 1.52	118.75 $\pm$ 1.56**

\* Significant increase in weight at  $P \leq 0.05$ . \*\* Significant increase in weight at  $P \leq 0.01$ . + Significant reduction in weight at  $P \leq 0.01$

**TABLE 2: MEAN WEIGHT (mg) OF UTERUS OF CONTROL AND EXPERIMENTAL GROUPS OF ADULT FEMALE WISTAR RATS**

S. no	Groups	No. Animals	Mean $\pm$ SEM (mg)
1	A	5	521.00 $\pm$ 0.50
2	B	5	513.10 $\pm$ 1.00***
3	C	5	514.11 $\pm$ 1.50***
4	D	5	463.50 $\pm$ 5.00**
5	E	5	528.90 $\pm$ 1.00****

\*\* Significant reduction in uterine weight when compared to A ( $P \leq 0.01$  and  $P \leq 0.05$ ). \* Significant uterine weight gain when compared to D ( $P \leq 0.01$ ).

\*\*\* Significant uterine weight gain when compared to D ( $P \leq 0.01$ ). \*\*\*\* Significant uterine weight gain when compared to A ( $P \leq 0.01$ )

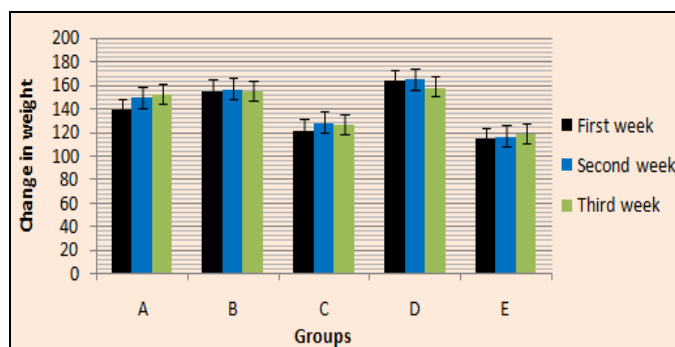


FIG. 1: THE CHART SHOWING THE MEAN WEIGHT OF THE ANIMALS DURING THE EXPERIMENT

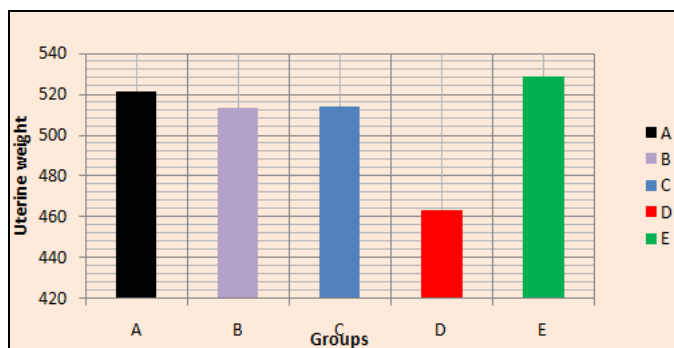


FIG. 2: THE CHART SHOWING THE MEAN WEIGHTS OF THE UTERUS OF THE ANIMALS DURING THE EXPERIMENT

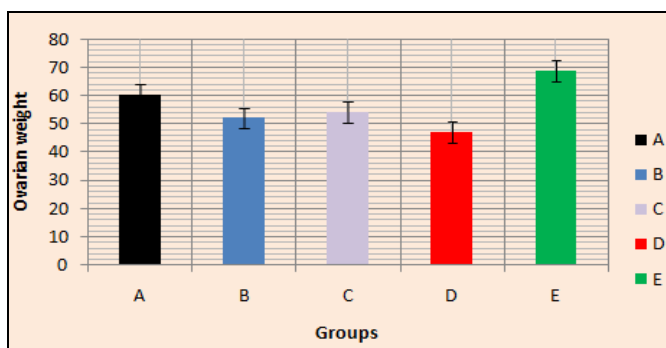


FIG. 3: THE CHART SHOWING THE MEAN WEIGHTS OF THE OVARY OF THE ANIMALS DURING THE EXPERIMENT

TABLE 3: MEAN WEIGHT (mg) OF OVARIES OF CONTROL AND EXPERIMENTAL GROUPS OF ADULT FEMALE WISTAR RATS

S. no.	Groups	No. of Animals	Mean ± SEM (mg)
1	1	5	60.10 ± 0.50
2	2	5	51.91 ± 1.00d
3	3	5	54.00 ± 1.00d
4	4	5	47.10 ± 2.00**
5	5	5	68.61 ± 0.40***

\*\*\* Significant increase in ovarian weight when compared to group A (P≤0.01). \*\*Significant reduction in ovarian weight when compared to group A (P≤0.01). A significant increase in ovarian weight when compared to group D (P≤0.01)

Ovarian SOD Activities: The results of the SOD are presented in Table 5 and Fig. 4 below.

TABLE 5: RESULTS OF THE ACTIVITIES OF OVARIAN ENZYME SUPEROXIDE DISMUTASE (SOD) OF THE EXPERIMENTAL

S. no	Groups	No. Animals	Mean ± SEM (µg/mg)
1	A	5	20.00 ± 0.38
2	B	5	21.99 ± 2.35**
3	C	5	20.80 ± 0.65**
4	D	5	27.15 ± 5.22***
5	E	5	20.20 ± 0.53

\*\*\* Significant increase in SOD activity when compared to group A (P≤0.01 and P≤0.05). \*\* Significant reduction in SOD activity when compared to group D (P≤0.01)

**Phytochemical Screening:** Using standard method as recorded in Sahiru and Catherine<sup>28</sup>, the following chemicals below screened for in *F. vogelii*.

TABLE 4: PHYTOCHEMICAL COMPOSITIONS OF ETHANOLIC EXTRACTS OF DRIED LEAVE OF *F. VOGELII*

S. no.	Parameter	Present	Absent	Moderate	High
1	Saponins				***
2	Alkaloids	*			
3	Flavonoids				***
4	Coumarins			**	
5	Steroids			**	
6	Triterpenoids	*			
7	Carotenoids			**	
8	Polyphenols				***
9	Cardiac glycosides	*			

\* = Indicates the presence of phytochemicals. - = Indicates the absence of phytochemicals. \*\* = Shows moderate concentration level of phytochemicals. \*\*\* = Shows a high concentration level of phytochemicals

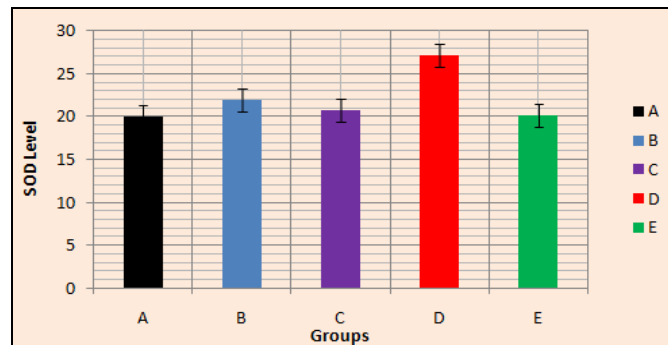


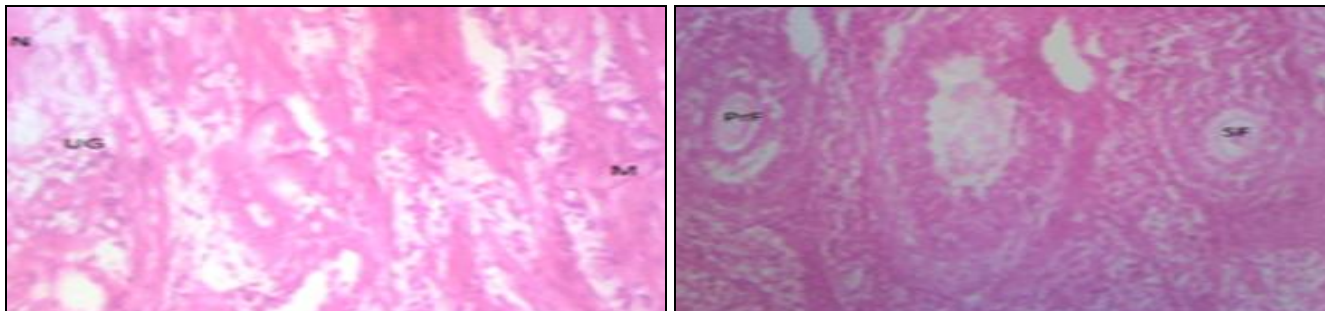
FIG. 4: CHART SHOWING THE MEAN SOD LEVELS OF THE OVARIES OF THE ANIMALS

It indicates that the positive control (group D) has a significant increase in SOD activity as compared to the negative control (group A).

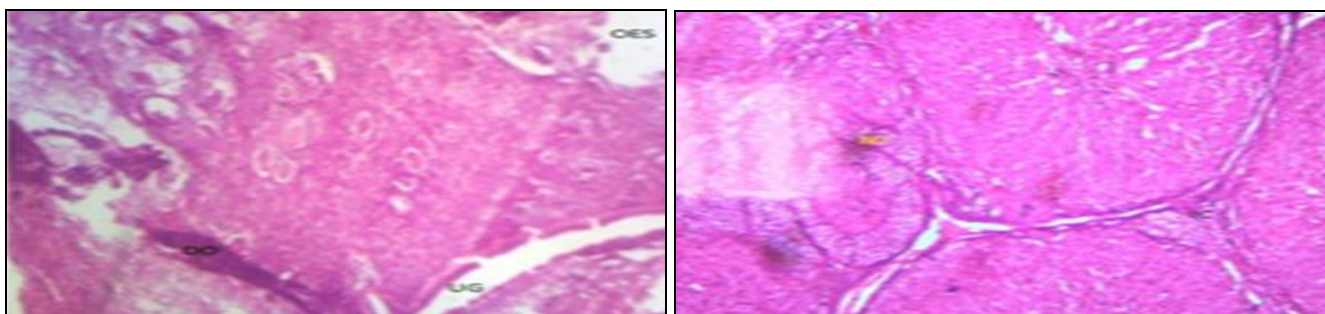


The ovaries of B and C showed a significantly decreased ovarian SOD activity when compared to that of the positive control (group D). There was a significant decreased in SOD level were the protective groups of both aqueous and ethanolic extracts.

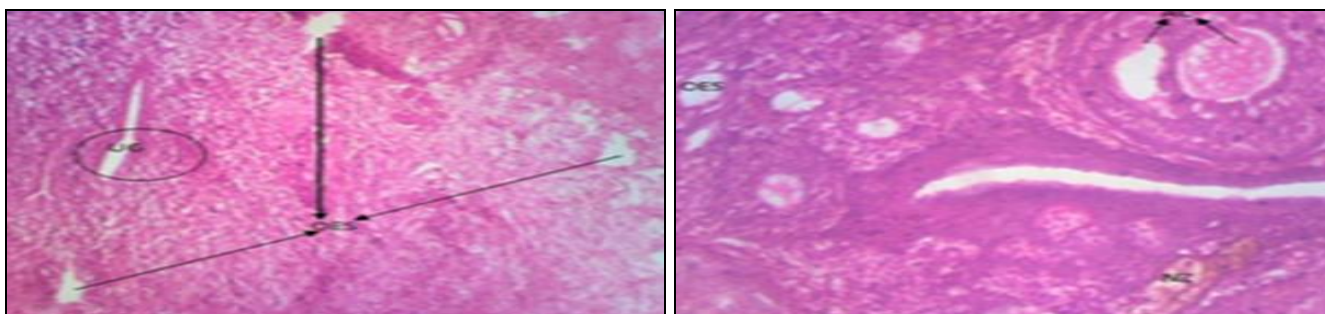
**Histological Studies:** The tissues were processed and stained with hematoxylin and eosin (H and E) stain and view with a microscope under the magnification of 200X. The alterations an observed microscopically is presented as photo micrographical plate below.



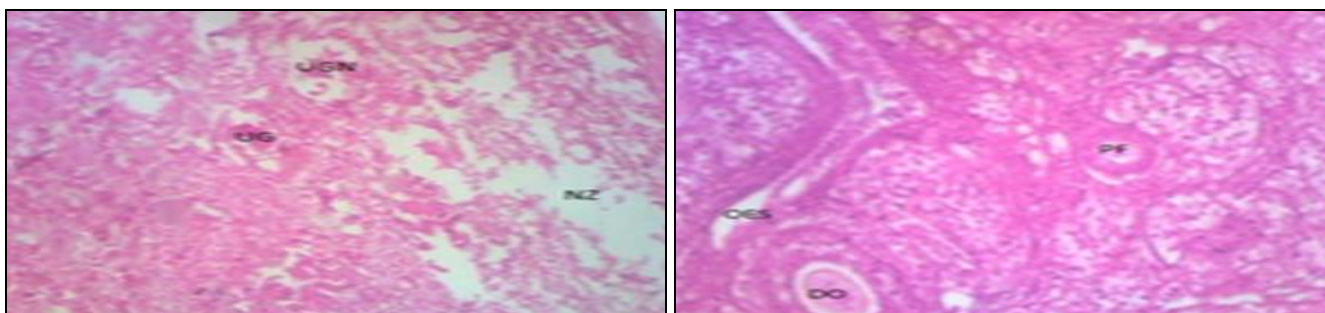
**FIG. 5: NEGATIVE CONTROL UTERUS REVEALS THE PRESENCE OF N- NORMAL MUCOSA STRUCTURE, M-MYOMETRIUM, AND UG- UTERINE GLANDS) AND OVARY SHOWING PRF- PRIMARY FOLLICLE AND SF- SECONDARY FOLLICLE. H AND E 200X**



**FIG. 6: GROUP B UTERUS SHOWING DO-DIFFUSE OEDEMA, UG-UTERINE GLAND, AND OES-OPTICAL EMPTY SPACE AND OVARY SHOWING NZ-NECROTIC ZONE AND IC- INTERSTITIAL CELLS H AND E STAINS, 200X**



**FIG. 7: GROUP C UTERUS SHOWING OES-OPTICAL EMPTY SPACES AND UG-UTERINE GLAND AND OVARY SHOWING AC-ANTRAL CAVITIES OF SECONDARY FOLLICLES, OES-OPTICAL EMPTY SPACES AND NZ-NECROTIC ZONE, H & E STAINS, 200X**



**FIG. 8: GROUP D NZ-NECROTIC ZONE, UG-UTERINE GLANDS, UGN-UTERINE GLANDS NECROSIS, AND ENDOMETRIAL DENUDATION AND OVARY SHOWING OES-OPTICAL EMPTY SPACES, PF-PRIMORDIAL OVARIAN FOLLICLES AND DO-DIFFUSE OEDEMA, H AND E 200X**

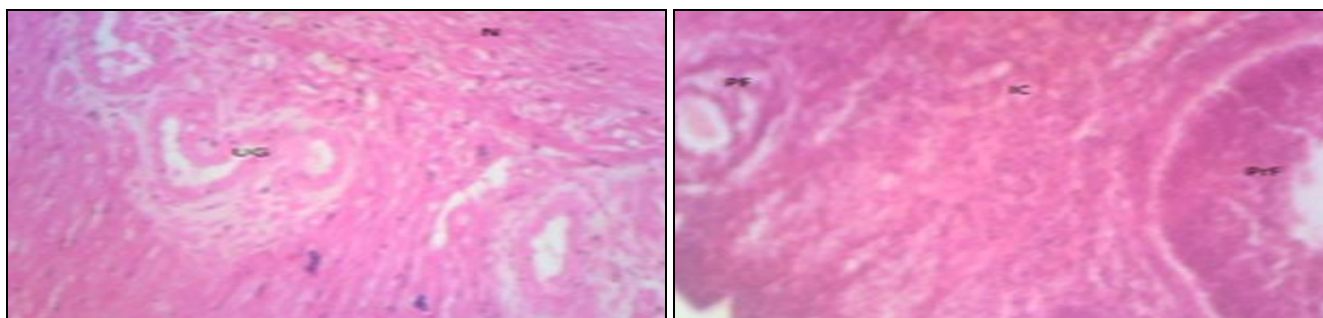


FIG. 9: GROUP E UTERUS UG-UTERINE GLANDS, M-MYOMETRIUM AND N-NORMAL MUCOSA, AND OVARY PRF-PRIMARY FOLLICLE, PF-PRIMORDIAL FOLLICLE, AND IC- INTERSTITIAL CELLS, H AND E STAINS, 200X

**DISCUSSION:** The female reproductive system is adversely affected by exposure to environmental toxicants, and only a few researchers' attention has been drawn to toxic environmental factors that cause uterine and ovarian toxicity<sup>29, 30</sup>. The uterus is a thick-walled, hollow, pear-shaped muscular organ responsible for the reception, implantation, and nutrition of the fertilized ovum<sup>31-33</sup>. The ovaries produce and periodically release ova, secrete estrogen, testosterone and progesterone<sup>34-36</sup>. Much attention has been given for the approval of herbal medicine in the new millennium, and *F. vogelii* is a vegetable that has been used locally to treat some illnesses and also implicated by some researchers as an herbal remedy for some human diseases<sup>37</sup>.

According to OECD<sup>38</sup>, and Ali *et al.*,<sup>39</sup> weight determination is considered as a constituent in the study of the safety of any therapeutic agent. The body weight of the negative control group increased significantly throughout the research ( $P \leq 0.01$  and  $P \leq 0.05$ ) as recorded in **Table 1**, while the lead acetate group recorded an insignificant body weight increase first before recording a significant weight loss ( $P \leq 0.01$ ). This reduction in weight might be due to the deleterious effect of lead on the organs at this stage. This increase in weight is one of the major pointers that the leave of *F. vogelii* has a nutritive value as a vegetable<sup>39</sup>. There was a significant decrease in the uterine and ovarian weights of positive control at  $P \leq 0.01$  and  $P \leq 0.05$ . This agrees with the research conducted by Durgesh and Lata<sup>40</sup> which stated that "the animals that received only lead acetate experienced a significant reduction in uterine weight." The experimental groups showed ovarian and uterine weights that were not affected much which might be due to the protective effects of the extract as shown in **Tables 2** and **3** above. The above findings

are in agreement with the findings of Durgesh and Lata in 2014. The higher the dose, the higher the weight gained by the organs signifying their role in restoring the normal physiology of the organs of the body which may be dose-dependent<sup>41</sup>. The groups that received only the extract recorded a significant uterine and ovarian weight gain at  $P \leq 0.01$ . This weight gain could be an insight into the therapeutic benefits of the leaves.

Natural antioxidants are very effective in removing free radicals released in the body during reactive oxygen species (ROS) as a result of various disease conditions, and it has been an active area of research<sup>42</sup>. Various researches have revealed over a long period that these antioxidants are capable of either preventing or curing the damages caused by the presence of these free radicals in the body<sup>42</sup> and antioxidants such as SOD, flavonoids, *etc.* are compositions of many vegetables like *F. vogelii*<sup>43</sup>. Toxicity causes an increment in the concentration of free radicals leading to an imbalance between the free radicals and antioxidants which cause oxidative stress<sup>44</sup>.

*F. vogelii* as a vegetable contains an antioxidant which can be taken through diet to maintain the homeostasis between free radicals and antioxidants and thus prevent various deleterious effects, like lead toxicity, inflammation, cancer, aging, cardiovascular and brain disorders<sup>45, 46</sup>. According to Flora *et al.*,<sup>42</sup> and Ene-Obong *et al.*,<sup>18</sup> "those consume antioxidant-rich diet are better positioned to reaping various health benefits and boost their antioxidant levels; therefore, food is always favored over supplements mainly because it contains thousands of antioxidants in contrast to supplements which are generally rich in single or a few antioxidants".



As shown in **Table 5**, there was a significant increase in ovarian SOD in the positive control group while the experimental groups showed a significant decrease when compared to the positive control. These reductions in SOD could be due to the role of the extract as an antioxidant. The extracted group showed SOD level closer to the negative control which is suspected to be a result of the extract in removing free radicals produced due to inflammation caused by the presence of toxins that cause it to rise above normal<sup>47, 48</sup>.

On screening, the following chemicals were seen; saponins, flavonoids, alkaloids, triterpenoids, polyphenols, coumarins, steroids, carotenoids and cardiac glycosides. Various phytosteroids on plants have been shown to promote fertility<sup>49</sup>. Flavonoids present in the leave of plants have been shown to possess many pharmacological properties such as anti-oxidant activities, anti-inflammatory activities, anti-cancer activities and anti-microbial effects<sup>51, 52</sup>. Flavonoids might have contributed to the extracts healing (anti-inflammatory) properties as observed from the histological studies<sup>52</sup>. The extract is very rich in triterpenoids, a compound which plays a very active role in wound healing<sup>53</sup>. According to Krishnaiah *et al.*,<sup>54</sup> triterpenoids are shown to strengthen the skin, increase the concentration of antioxidants in wounds and restore inflamed tissues by increasing blood supply.

In this experiment, we also considered the role of the extract in restoring the normal histological of the ovaries and uterus after some alterations. The examination of the ovary microscopically showed damages and reduction in the formation of follicles with a marked increase in the number of atretic follicles which is in agreement with the work done by Patrick<sup>55</sup>, Dumitrescu *et al.*,<sup>56</sup> and Igile *et al.*,<sup>57</sup>. According to Taupeau *et al.*, 2001, low lead in the ovary caused dysfunction of folliculogenesis, with fewer primordial follicles and increased atretic antral follicles<sup>43</sup>. The organs also presented diffuse edema, necrosis, empty optical spaces, denudations and atretic follicles<sup>57</sup>.

The organs looked well vascularized in the groups that received the extracts indicating restoration of the blood supply to the organs that were lost due to the lead-induced toxicity. According to Shah *et al.*,<sup>58</sup> oral administration of lead causes reduced

ovarian follicles and increased atretic follicles as observed in this study.

The organs (uterus and ovaries) belonging to the animals in the negative control group presented a normal histoarchitecture<sup>56</sup>. The organs of the animals that received only lead acetate (positive control) presented a fatty change (a reversible change that occurs in organs due to toxicity) appearance, focal loss of tissue (empty optical spaces) and endometrial denudation with polypoid appearance. This fatty change may have occurred due to toxicity caused by loss of blood supply leading to tissue necrosis. Lead also inhibits the body's ability to making hemoglobin by interfering with several enzymatic steps in the haem pathway<sup>59</sup>. The uterine glands were seriously affected by the lead acetate toxicity. The structural changes observed as a direct effect of lead exposure on the ovaries and uteri in this research were also reported by Dumitrescu *et al.*<sup>56</sup>

The uterus of low dose (100 mg/kg) group showed the efficacy of the extract in protecting the uterus from histological alterations caused by the induced lead acetate toxicity although there were still some areas of edema **Fig. 7**. The high dose (300 mg/kg) group showed tiny uterine glands with little damages caused by the lead toxicity. This agrees with the report of Dumitrescu *et al.*<sup>56</sup> The uterine glands edema was observed to be far smaller than edema seen in the low dose group. The above may be a pointer that the extract is dose-dependent, that is, the higher the dose, the more efficacious it is. The ovaries of this group showed a multiple ovarian follicular developments. It also showed ovarian follicles protected from the induced lead toxicity by the extract. The extracts group only, the uterus and ovaries looked well perfused with blood and also healthier than the positive control group. In this group, an improvement was observed in the organ perfusion signifying the nutritional values of the extracts.

**CONCLUSION:** In summary, our results demonstrated that *F. vogelii* leave extract is a very good natural antioxidant that could be used as alternative herbal medicine. Our results also showed that the herb is good in fighting reactive oxygen species (ROG) production and also can resist lead reproductive toxicity.

**ACKNOWLEDGEMENT:** We want to appreciate Mr. Nwajagu G. I., Chief Technologist Gross unit of Anatomy Department Dr. G. G. Akunna and Dr. Ogugua Egwu an Associate Professor of Anatomy and Dean Faculty of Basic Medical Sciences, Alex Ekwueme Federal University Ndufu-Alike (AE-FUNAI), Ikwo for their advice and assistance all through the study period. We equally appreciate all the lecturers and Staff of Anatomy Department, Faculty of Basic Medical Sciences, University of Nigeria Nsukka Enugu Campus (UNEC).

**CONFLICT OF INTEREST:** Nil

### REFERENCES:

- Dobrakowski M, Kasperczyk J, Romuk E, Prokopowicz A and Birkner E: The influence of beta-carotene on homocysteine level and oxidative stress in lead-exposed workers. *Med Pr* 2014; 65: 309-16.
- Haouas Z, Sallem A, Zidi I, Hichri H, Mzali I and Mehdi M: Hepatotoxic effects of lead acetate in rats: Histopathological and Cytotoxic Studies. *J Cytol Histol* 2014; 5: 256.
- World Health Organization (WHO). Lead poisoning and health. 2016; Available online at <http://www.who.int/mediacentre/factsheets/fs379/en/>
- European Commission. Directive 2010/63/EU of the European Parliament and the Council on the Protection of Animals used for Scientific Purposes. Brussels, Belgium: European Commission 2010.
- Restanty DA, Soeharto S and Indrawan WA: The effect of oral lead acetate exposure on bax expression and apoptosis index granulosa cells antral follicle in female wistar rat (*Rattus norvegicus*). *Asian Pac J Reprod* 2017; 6(2): 54-57.
- BaSalamah MA, Abdelghany AH, El-Boshy M, Ahmad J, Idris S and Refaat B: Vitamin D alleviates lead-induced renal and testicular injuries by immunomodulatory and antioxidant mechanisms in rats. *Scientific Reports* 2018; 8: 4853, 1-13
- Wani AL, Ara A and Usmani JA: Lead toxicity: a review. *Interdiscip Toxicol* 2015; 8(2): 55-64.
- Navas-Acien A, Guallar E, Silbergeld EK and Rothenberg SJ: Lead exposure & cardiovascular disease- A systematic review. *Environ Health Perspect* 2007; 115: 472-82.
- Aprioku JS and Siminialayi IM: Maternal lead exposure and pregnancy outcome in Wistar albino rats. *Journal of Toxicology and Environmental Health Sciences* 2013; 5(10): 185-193. DOI: 10.5897/JTEHS2013.0279.
- Fang JY, Wang PW, Huang CH, Hung YY and Pan TL: Evaluation of the hepatotoxic risk caused by lead acetate via skin exposure using a proteomic approach. *Proteomics*, 2014; 14: 2588-2599.
- Haryanto B: Lead exposure to battery recycling in Indonesia. *Rev Environ Health*, 2016; 31, 13-6 Goyer RA, Cheian MG, Jones MM and Reigart JR: Role of chelating agents for prevention and treatment of exposure to toxic metals. *Environ. Health Perspective* 1995; 103: 1048-52.
- Dart RC, Hurlbut KM and Boyer-Hassen LV: Lead: Medical Toxicology. Lippincot Williams and Wilkins, Edition 3<sup>rd</sup>, 2004.
- Grant LD: Lead & Compounds. Environmental toxicants: Human exposures and their health effects. Wiley Interscience, Edition 3<sup>rd</sup>, 2009.
- Berg CC and Corner EJH: Moraceae. In: *Flora Malesiana Ser I* 2005; 17: 2.
- Egbuna PAC, Joshua PE and Chigbo MU: Antihepatotoxic effects of *Ficus vogelii* ethanol leaf extract on the liver function indices of CCl<sub>4</sub>-induced hepatotoxicity in rats. *Journal of American Science* 2011; 7(6).
- Krinke GJ: *The Laboratory Rat*. Academic press 2002.
- Tiwari P, Kumar B, Kaur M, Kaur G and Kaur H: Phytochemical screening and Extraction: A Review. *Internationale Pharmaceutica Scientia* 2011; 1(1). Available online at <http://www.ipharmsciencia.com>
- Ene-Obong H, Onuoha N, Aburime L and Mbah O: Chemical composition and antioxidant activities of some indigenous spices consumed in Nigeria. *Food Chem* 2017.
- Akunna GG, Saalu LC, Ogunlade B, Ojewale AO and Enye LA: Consumption of bay leaf (A food spice) may be a safe and effective treatment for male infertility resulting from partial ligation of the left renal vein in Wistar rat: Study suggests. *American Jour of Research Communication* 2013; 3: 123-142. [www.usajournals.com](http://www.usajournals.com).
- Winterboun CC, Hawkins RE, Brian M and Carell RW: The estimation of red blood cell superoxide activity. *J Lab. Clin Med* 1975; 85: 337-341.
- Rukmini MS, D'Souza B and D'Souza V: Superoxide dismutase and catalase activities and their correlation with malondialdehyde in schizophrenic patients. *Indian J Clin Biochem* 2004, 11: 719-724.
- Pisoschi AM, Pop A, Cimpeanu C and Predoi G: Antioxidant capacity determination in plants and plant-derived products: A review. *Oxid Med Cell Longev* 2016: 9130976.
- Romero MPR, Brito RE, Palma A, Montoya MR, Mellado JMR and Rodríguez-Amaro R: An electrochemical method for the determination of antioxidant capacities applied to components of spices and condiments. *J Electrochem. Soc* 2017; 164: B97-B102.
- Adenuga GA, Adegbesan BO and Adebayo OL: Anti-oxidant defense of zinc acetate supplementation on the brain of Protein undernourished rats. *Int J Biol Chem Sci* 2009; 3(1): 152-155.
- Xu D, Li Y, Meng X, Zhou T, Zhou Y, Zheng J, Zhang J and Li H: Neutral antioxidants in foods and medicinal plants: Extraction, assessment and resources. *Int J Mol Sci* 2017; 18: 96.
- Venetsanou A, Anastasaki E, Gardeli C, Tarantilis PA and Pappas CS: Estimation of antioxidant activity of different mixed herbal infusions using attenuated total reflectance Fourier transform infrared spectroscopy and chemometrics. *Emir J Food Agric* 2017; 29: 149-155
- Schoenwolf GC, Bleyl SB, Brauer PR, Francis-west PH and Philipa H: *Larsen's Human Embryology*. New York; Endinburgh: Churchill Livingstone, Edition 5<sup>th</sup>, Chapter 16, 2015.
- Sahiru KB and Catherine L: General techniques involved in phytochemical analysis. *International Journal of Advanced Research in Chemical Science (IJARCS)* 2015; 2: 4.
- Casarett LJ, Klaassen CD and Doull J: Toxic effects of metals. *Casarett and Doull's Toxicology: The Basic Science of Poisons*. McGraw-Hill Professional, Edition 7<sup>th</sup>, 2007.
- Caïto S, Lopes A, Paoliello MMB and Aschner M: *Toxicology of Lead and its Damage to Mammalian Organs*. 2017/07/22 ed. *Met Ions Life Sci* 2017: 17.



31. Drake R, Vogl W and Mitchell AWM: Grays anatomy for students. Churchill Livingstone (Elsevier's) Publishers; Saunders, Edition 3<sup>rd</sup>, Chapter 5, 2014: 397-416.
32. Snell RS: Clinical Anatomy by regions, Lippincott, Williams & Wilkins, London, Chaptet 7, 2012: 279-297.
33. Standring S, Ellis H, Healy JC, Johnson D, Williams A and Collins P: Gray's Anatomy: The Anatomical Basis of Clinical Practice. Madrid Churchill Livingstone, 40<sup>th</sup>, Chapter 77, 2008: 1530-1720.
34. Chaurasia BD: Regional and Applied Dissection and Clinical Human Anatomy. Edition 6<sup>th</sup>, 2013; 2: 382-392.
35. Marieb and Elaine: Anatomy & physiology Textbook. Benjamin-Cummings 2013: 903.
36. Ross M and Pawlina W: Histology: A Text and Atlas. Lippincott Williams & Wilkins, Edition 6<sup>th</sup>, 2011.
37. Igile GO, Utin IC, Iwara IA, Mgbeje BIA and Ebong PE: Ethanolic extract of *Ficus vogelii* ameliorates dyslipidemia in diabetic Albino Wistar rats. International Journal of Current Research in Biosciences and Plant Biology 2015; 2(8): 87-96. www.ijcrbp.com
38. OECD: The OECD Guideline for Testing of Chemical usage in Experiment. The organization of Economic Co-operation Development, Paris 2001; 1-14.
39. Alli LA, Oluwole OP, Aniah, JA and Adesokan AA: Histopathological effects of aqueous root extract of *Acacia nilotica* on rat liver, kidney and lungs. Jour of Anatomical Sciences 2015; 6(1): 12-18.
40. Durgesh NS and Lata B: Role of vitamin E on anti folliculogenesis effects of lead acetate on the diameter of follicles containing ovarian tissue of Swiss albino mice; GJBAHS 2014; 3(1): 322-325.
41. Rastogi S, Pandey M and Rawat AKS: Spices: Therapeutic potential in cardiovascular health. Curr Pharm 2017; 23: 989-998.
42. Flora G, Gupta D and Tiwari A: Toxicity of lead: A review with recent updates Interdiscip Toxicol 2012; 5(2): 47-58.
43. Flora SJS: Structural, chemical and biological aspects of antioxidants for strategies against metal and metalloid exposure. Oxid Med Cell Longev 2009; 2: 191-206.
44. Blokhina O, Virolainen E and Fagerstedt KV. Antioxidants, oxidative damage and oxygen deprivation stress: A review. Ann Bot 2003; 91: 179-194.
45. Willcox JK, Ash SL and Catignani GL: Antioxidants and prevention of chronic disease. Crit Rev Food Sci Nutr 2004; 44: 275-295.
46. Wadood A, Ghufuran M, Jamal SB, Naeem M and Khan A: Phytochemical analysis of medicinal plants occurring in the local area of Mardan. Biochem Anal Biochem 2013; 2: 144.
47. Sirisha N, Sreenivasulu M, Sangeeta K and Madhusudhana CC: Antioxidant properties of *Ficus species*: A review. International Journal of Pharm Tech Research CODEN (USA) 2010; 2(4): 2174-2182.
48. Srinivasan K: Ginger rhizomes (*Zingiber officinale*): A spice with multiple health beneficial potentials. Farma Nutrition, 2017; 5: 18-28.
49. Iwara IA, Igil GO, Uboh FE, Eyong EU and Ebong PE: Hypoglycemic and hypolipidemic potentials of an extract of *vernonia calvaona* on alloxan-induced diabetic Albino Wistar rats. Eur J Med Plants 2015; 8(2): 78-88.
50. Uche FI, Obianime AW and Gogo-Abite M: Effects of Vanadium pentoxide on the histological and sperm parameters of male Guinea Pigs. Jour of Applied Science and Environmental Management 2008; 12(3): 107-115.
51. Serafini M and Peluso I: Functional foods for health: The interrelated antioxidant and anti-inflammatory role of fruits, vegetables, herbs, spices and cocoa in humans. Curr. Pharm. Des 2016; 22: 6701-6715.
52. Okwu DE and Josiah C: Evaluation of the Chemical Composition of two Nigerian Medicinal Plants. Afri J Biotechnol 2006; 5(4): 357-361.
53. Chirag JP, Tyagi S, Halligudi N, Yadav J, Pathak S, Singh SP, Pandey A and Singh D: Antioxidant activity of herbal plants: a recent review. Journal of Drug Discovery and Therapeutics 2013, 1(8): 01-08.
54. Krishnaiah D, Devi T, Bono A and Sarbatly R: Studies on phytochemical Constituents of six Malaysian Medicinal Plants. Journal of Medicinal Plants Research 2009; 3(2): 067-072.
55. Patrick L: Lead toxicity Part II: The role of free radical damage and the use of antioxidants in the pathology and treatment of lead toxicity. Alt Med Rev 2006; 11: 114-127.
56. Dumitrescu E, Chiurciu V, Muselin F, Popescu R, Brezovan D and Cristina RT: Effects of long-term exposure of female rats to low levels of lead: Ovary and uterus histological architecture changes. Turk J Biol 2015; 39: 284-289.
57. Taupeau C, Poupon J, Nomé F and Lefèvre B: Lead accumulation in the mouse ovary after Treatment-Induced Follicular Atresia Reprod Toxicol 2001; 15(4): 385-391.
58. Shah A, Mian M, Khan S, Tayyab M, Chaudhary N and Ahmed N: Correlation of blood lead levels with atresia of ovarian follicles of Albino mice. Ann Pak Inst Med Sci 2008; 4: 188-192.
59. ATSDR: Toxicological profile for lead. Atlanta, GA, USA: Agency for Toxic Substances and Disease Registry 2005.

**How to cite this article:**

Ezugworie JO and Uchewa OO: Efficient use of traditional medicine to detoxify upper reproductive organs toxicity that may lead to infertility. Int J Pharm Sci & Res 2019; 10(1): 347-55. doi: 10.13040/IJPSR.0975-8232.10(1).347-55.

All © 2013 are reserved by International Journal of Pharmaceutical Sciences and Research. This Journal licensed under a Creative Commons Attribution-NonCommercial-ShareAlike 3.0 Unported License.

This article can be downloaded to **ANDROID OS** based mobile. Scan QR Code using Code/Bar Scanner from your mobile. (Scanners are available on Google Play store)