



Received on 01 January 2020; received in revised form, 07 April 2020; accepted, 10 April 2020; published 01 January 2021

ALLEVIATION EFFECT OF *VENTILAGO CALYCVLATA* AGAINST DEXAMETHASONE DELAYED WOUND HEALING

Shweta Kumar¹, Deepti Jain² and Rajesh Singh Pawar^{*3}

Pharmacognosy and Pharmacology Laboratory¹, VNS Group of Institutions, Faculty of Pharmacy, VNS Campus, Vidya Vihar, Neelbud, Bhopal - 462044, Madhya Pradesh, India.

School of Pharmaceutical Sciences², RGPV, By-pass Road, Gandhinagar, Bhopal - 462036, Madhya Pradesh, India.

Truba Institute of Pharmacy³, Karod-Gandhi Nagar by Pass Road, Bhopal - 462038, Madhya Pradesh, India.

Keywords:

Ventilago calyculata, Excision and incision wound, Wound healing, Hydroxyproline, Tensile strength

Correspondence to Author:

Dr. Rajesh Singh Pawar

Director & Principal,
Truba Institute of Pharmacy,
Karod-Gandhi Nagar By-Pass Road,
Bhopal - 462038, Madhya Pradesh,
India.

E-mail: dr_pawar14@rediffmail.com

ABSTRACT: Suppression of wound repair is a challenge for patients and healthcare workers globally. Excision and incision wounds were created on Wistar albino rats on the back of the experimental animals. The rats were categorized into seven groups (n = 6). The study aimed to determine the effect of topical administration of successive extracts of *Ventilago calyculata* (stem bark) against dexamethasone-suppressed wound healing. The rats of Group I (normal - given saline and wounds covered with hydrogel base); Group II (positive control was given dexamethasone (1 mg/kg/body weight) intraperitoneally (10 days) and wounds covered with SSDee Ultra cream); Group III (untreated was given dexamethasone (1 mg/kg/body weight) intraperitoneally (10 days) and wounds covered with hydrogel base; Group IV-VII (treatment groups were given dexamethasone intraperitoneally (10 days) (1mg/kg/body weight) and wounds covered with F1, F2, F3, and F4 respectively. Excision and incision wounds were inflicted on the next day of dexamethasone dosing. At the end of the 30-day treatment period, wound contraction, epithelisation period, hydroxyproline content, tensile strength, and histological changes during wound healing were assessed in rats. The statistical analysis showed that in excision and incision wound models, all the preparations exhibited significant (p<0.01) wound healing efficiency as compared to the untreated. Among all the treatment groups, aqueous extract one revealed maximum wound repair potential. In light of our finding that topical treatment with F4 accelerated the wound repair in the dexamethasone-treated group. We propose that treatment with F4 is a therapeutically beneficial method of decelerating wound retardation by dexamethasone intake.

INTRODUCTION: The wound is defined as the interruption in the structural and functional continuity of living tissues.

Wound healing is a product of the integrated response to an injury to tissue that leads to events that either occur concurrently or are associated with some chemical, biological and cellular pathways.

These phases require inflammation, the proliferation of fresh cells, cellular differentiation, and orderly movement of cells in particular directions to particular locations. Disruption into any of these stages could alter the repair process¹. Wound healing problems pose a serious challenge

| | |
|--|--|
| | <p style="text-align: center;">DOI: 10.13040/IJPSR.0975-8232.12(1).347-55</p> |
| | <p style="text-align: center;">This article can be accessed online on www.ijpsr.com</p> |
| <p>DOI link: http://dx.doi.org/10.13040/IJPSR.0975-8232.12(1).347-55</p> | |

and are probable to intensify since they are linked to conditions such as diabetes, hypertension, obesity, a drug-induced delay (steroidal and non-steroidal anti-inflammatory drugs, chemotherapeutic agents, etc.) which may retard wounds, cause organ failure, and can even be life-threatening. Dexamethasone is a synthetic glucocorticoid that is very effective in suppressing inflammation. It is also used as antiemetic, in transplantation and allograft rejection². It is known to retard wound repair owing to its catabolic action on the epithelial tissues^{3,4}.

Medicinal plants have facilitated in treatment of ailments for patients throughout the world, especially India, who is endowed with rich knowledge of indigenous herbs. Research on wound healing using plants is an area explored widely in the present clinical system. The research in plants based on ethnomedicinal use as an anti-inflammatory and wound healing agents might be a logical research strategy in the development of potent herbal formulations. After reviewing the literature, it was revealed that *Ventilago calyculata* Tul. (Rhamnaceae) syn. *Ventilago denticulata* have been employed in treating many skin-related problems traditionally^{5, 6, 7}. It was hypothesized that formulations prepared from the extracts of *V. calyculata* may be able to accelerate wound healing suppressed due to dexamethasone administration in rats.

MATERIALS AND METHODS:

Authentication of Raw Material: The bark of *V. calyculata* (VC) was collected from the adjoining area of Bhopal and was identified by Dr. Zia-Ul-Hasan, HOD, Dept. of Botany, Safia College, Bhopal. The exsiccated specimen was deposited in the same Department. (Voucher specimen no.: 415/Safia/Botany/15)

Extraction of Plant Material: The bark of VC was dried in shade and ground, separated the comminuted material by sieve #60, and stored in sealed containers for future use. Further, the material was subjected to extraction in a Soxhlet extractor successively using solvents in increasing order of polarity, i.e., petroleum ether (60-80 °C), ethyl acetate, methanol, and finally macerated to obtain the aqueous extract. The crude extracts were filtered and dried using a rotary evaporator.

Phytochemistry of Extracts:

Preliminary Phytochemistry of the Fractionates:

The extracts were investigated to confirm the presence of various active principles, with the help of standard qualitative procedures⁸.

Estimation of Total Phenolic Content:

The amount of phenols in the crude extracts was assessed using a 96-well plate by Folin-Ciocalteu (FC) reagent. The extract solution (50 µl) was added to the microtiter plate. Further, Folin Ciocalteu reagent (50 µl) and sodium hydroxide (100 µl) was added. After 3 min. recorded the absorbance (λ_{\max} 765 nm) using the 96-well plate reader (Bioteck, Gen 5). A calibration curve of gallic acid (2.5-30 µg/ml) was plotted which was used as the standard ($r^2 = 0.9855$)⁹.

Estimation of Total Flavonoidal Content:

The amount of flavonoids in the extracts was assessed based on Yang *et al.*, 2011 protocol using aluminium chloride (AlCl₃) in a 96-well plate¹⁰. The extract solution (50 µl) was added into the micro-titer plate. Further, aluminum chloride (2% w/v) was added. After 3 min. recorded the absorbance (λ_{\max} 435 nm) using the 96-well plate reader (Bioteck, Gen 5). A calibration curve of quercetin ($r^2 = 0.9951$) was plotted which was used as the standard ($r^2 = 0.9855$).

Antioxidant Potential:

DPPH Radical-Scavenging Activity:

The ROS-scavenging capacity of the crude plant extracts were assessed using DPPH reagent in a micro-titer plate. The crude plant extracts (0.1-1.6 mg/ml) in methanol were made to react with 0.2 mM DPPH reagent and kept in dark for 15 min. The intensity of the resulting violet color was read spectrophotometrically at λ_{\max} 517 nm using EON, BioTek's micro-titer plate¹⁰. The scavenging potential of extracts was calculated by contrasting with the standard (ascorbic acid) using the following equation:

$$\text{Radical Scavenging activity (\%)} = \left[\frac{(\text{Abs}_{\text{control}} - \text{Abs}_{\text{sample}} / \text{standard})}{\text{Abs}_{\text{control}}} \right] \times 100$$

Hydrogel Formulation Containing Various Extracts:

Preparation of Hydrogel Base and Formulations:

Hydrogel base was prepared by adding 1% w/v Carbopol 934 in water, allowed to

stand to swell for 12 h. Then dissolved 0.02% methyl/propyl paraben-and 0.2% sodium meta bisulphite separately in water ¹¹. **Table 1** Then triethanolamine was added drop wise to obtain the

desired pH. To this mixture weighed amount of *V. calyculata* crude extracts (2.5%) were added further and volume adjusted to 100 ml with water ¹².

TABLE 1: INGREDIENTS OF HYDROGEL PREPARATIONS USING VARIOUS CRUDE EXTRACTS

| Compositions (grams) → ↓ Preparation code | Carbomer 934 | Methyl paraben | Propyl paraben | Sodium metabi sulphite | Triethanol amine | Distilled Water qs | Extract 2.5% |
|--|-----------------|-------------------|-------------------|---------------------------|---------------------|-----------------------|-----------------|
| F ₁ | 1.00 | 0.02 | 0.02 | 0.2 | qs | 100 | VCP |
| F ₂ | 1.00 | 0.02 | 0.02 | 0.2 | qs | 100 | VCEA |
| F ₃ | 1.00 | 0.02 | 0.02 | 0.2 | qs | 100 | VCM |
| F ₄ | 1.00 | 0.02 | 0.02 | 0.2 | qs | 100 | VCA |

Physio-chemical Evaluation of the Topical Preparations: The crude extract hydrogels were evaluated for their physical appearance, spreadability, pH, skin irritation, etc. following the method by Khan *et al.*, 2013 ¹¹.

Test of Dermal Irritation: The hydrogel preparations- F₁, F₂, F₃, and F₄ were tested for their Skin irritation potential by dermal irritation assay following the OECD Guideline number 404 (2000b) on rats ¹³. The hydrogel preparations containing 2.5% of the respective crude extracts (0.5 g each) were applied on rat's skin after shaving. The test animals were observed daily for the next three days for any signs of erythema and edema.

Experimental Protocol for the Wound Healing Potential of Various Crude Extracts against Dexamethasone (decdan®) in Wistar Rats:

Experimental Animals: Wistar albino rats were issued from the animal center of the Pharmacology Division of our institution for assessing the pharmacological activity. The animals weighing 150-250 g of either sex were selected and housed in cages at approximately 20 °C with an artificial 12-hour light-12-h dark cycle. The study was approved by the Institutional Animal Ethical Committee (CPCSEA protocol no. PH/IAEC/VNS/ 2K13/16) and maintenance of the animals confirmed to their guidelines.

Acute Toxicity Study: The toxicity test of the hydrogel preparations was carried to determine the safe dose of the crude extracts in rats on applying Guideline number 434 (2004) of the Organization for Economic Co-operation and Development (OECD) ¹⁴. The rats were subdivided into 7 groups (n=6). The toxicity of hydrogel preparations F₁, F₂, F₃, and F₄ (2000 mg/kg b.w. of rats) was evaluated

in all the groups for 24 h. The rats were observed for behavioral changes and mortality following the application of test hydrogels for 24 h.

Wound Repair Protocol:

Excision/ Incision Models after Dexamethasone Administration:

To evaluate the effectiveness of the treatments of F₁, F₂, F₃, and F₄ against suppression caused by dexamethasone, excision/incision wound protocols were chosen. The rats were divided into seven groups (where n=6). Wounds of Group I rats (untreated normal group) were dressed with Carbopol base. Group II rats (positive control group) wounds were given dexamethasone and dressed in SSDeeUltra cream. Group III animals (the untreated group) was given dexamethasone (and dressed with hydrogel base; Groups IV-VII (treatment groups) were given dexamethasone and dressed with F₁, F₂, F₃, F₄ hydrogel preparations base respectively. Dexamethasone (Decdan®) was given intraperitoneally at 1 mg/kg b.w. for 10 days ¹⁵. The wounds were observed daily till 30 days or until complete healing of wounds, whichever was earlier ^{16, 17}. The animals were kept separate for approximately 30 min. after the application of hydrogel formulations to ensure proper absorption and then kept in individual cages up to a maximum of 5 rats in each cage.

Experimentally Induced Excision Wounds: The animals were firstly anesthetized with ketamine and xylazine (80 and 40 mg kg⁻¹ respectively); the hair of the dorsal region was depilated and cleaned with ethanol and sedated with lidocaine ointment. Under deep sedation using punch biopsy, two full-thickness wounds (6 mm diameter each) were created on the dorsal side of each rat. The day of wound infliction was taken as day zero and the percentage wound healing was calculated on these

days¹⁸. The following parameters were assessed using this protocol:

- (A) *In-vivo* Wound Closure (percentage of contraction)
- (B) Analysis of the Re-epithelialisation

(A) *In-vivo* Wound Closure: The wounds were photographed using a digital camera (Nikon Coolpix L830), and their width was calculated using ImageJ2x[®] (Wayne Rasband, USA). The wound closure was monitored by measuring wound width with 5-days interval till wounds were completely healed. It was computed as the percentage of the initial wound area.

(B) Analysis of Re-epithelialisation Process: Falling of dead tissue leaving no raw wound behind was considered as completion of epithelialisation and counting the days taken to achieve this was taken as a period of epithelialisation^{19, 20}.

Experimentally Induced Linear Incision Wounds: All the rats were weighed and intramuscularly anesthetized and placed in a prone position. Further, the rats were subjected to entire thickness incision on the depilated back of the animals parallel to the spine (four centimeters in length). This was done aseptically with a scalpel up to the fleshy panniculus of the skin. The incision was closed through simple interrupted sutures using a sterile curved needle and black silk surgical thread and was left undressed after suturing⁴. Animals were divided into various groups and treated daily, as described above, for the excision wound protocol. The hydrogel base/standard formulation/various hydrogel preparations were applied daily for over 30 consecutive days or until the complete repair of experimental wounds, whichever was earlier. Using this protocol, the breaking strength, level of hydroxyproline, and histomorphometric evaluation were done.

(A) Analysis of Biochemical Marker (hydroxyproline): The sample tissue was collected from various groups, dried up to constant weight (60-70 °C), and noted. The hydroxyproline level in the dried tissue was estimated by first hydrolyzing it in 6 N HCl (110 °C). Further, the hydrolysate of the tissue was oxidized for 20 min. with 0.05 M chloramine -T at RT, which was stopped by 3.15 M perchloric acid. To this mixture, 20% p-

dimethylamino-benzaldehyde was added to develop a red color due to the reaction between amino acids of hydroxyproline and incubated (60 °C) for 20 min. The absorbance was recorded at 557 nm, and the concentration of hydroxyproline was computed by comparing it with a standard curve²¹.

(B) Wound Breaking Strength: Breaking strength indicates the force per unit of cross-sectional area needed for breaking down of wound under tension. It is taken as the Index of the rate of repair as it gives an idea for the intra and the intermolecular cross-linking of collagen fibers newly deposited at the site of the wound. The rats were again sedated on day 30, and sutures were gently pulled out. Rats were placed one after another on the tensiometer.

The rat's skin was fixed on both sides by means of steel clips. One side of the clip was supported firmly, whereas the other side, with a long string with a weighing pan suspended at the end, was mounted on the pulley. To assess the tensile strength of the incision, weights were put on the pan gradually until the wound edges were pulled apart. The weight which was required to break the wound was recorded and was expressed as the breaking strength of the wound in grams⁴.

(C) Microscopic Morphometric Examination: At the end of the 30th day of experimentation, specimen tissue was taken from each group for histopathologic evaluations. The samples were fixed in 10% formalin and later on dehydrated in ethanol and cleared in xylene.

Further, blocked by embedding in paraffin and subsequently sectioned using the microtechnique. The tissue was stained with hematoxylin-eosin (H&E) for observation of histology under a light microscope and representative images were captured²².

Statistical Analysis: The data analysis was done with the help of Graph Pad Prism 5.00 software (Graph Pad, San Diego, CA). The wound closure images were analyzed by using the ImageJ2x[®] (Wayne Rasband, USA). The antioxidant values and wound repair measurements were evaluated using One-way ANOVA, following that Dunnett's multiple comparison test was applied for post hoc analysis. The p-value of <0.05 was accepted as significant.

RESULTS AND DISCUSSION:

Phytochemistry of Extracts:

Preliminary phytochemistry of Fractionates:

The phytochemical analyses of the crude drug extracts revealed that petroleum ether extract possesses sterols; ethyl acetate extract was found to contain glycosides and alkaloids; flavonoids, phenolic compounds, alkaloids, and triterpenoids were mainly found in methanolic extract and carbohydrates, proteins, phenolic compounds, flavonoids, and tannins were adequately found to be present in the aqueous extract.

Estimation of Total Phenolic Content: The content of phenols in the ethyl acetate (VCEA), methanolic (VCM), aqueous (VCA) extracts of *V. calyculata* was found to be 10.93 ± 0.17 , 14.91 ± 0.28 , and 15.64 ± 0.26 mg GAEg⁻¹ of DW respectively. The highest amount of total phenolics was found in the aqueous extract of *V. calyculata* (VCA).

Estimation of Total Flavonoidal Content: The content of flavonoids in the ethyl acetate (VCEA), methanolic (VCM), aqueous (VCA) extracts of *V. calyculata* was found to be 2.51 ± 0.02 , 6.66 ± 0.12 , 5.48 ± 0.19 mg QEG⁻¹ of DW respectively. The data were expressed as the mean \pm standard deviation of three determinations.

Antioxidant Potential:

DPPH Radical-Scavenging Activity: The violet color of 1, 1-diphenyl-2-picrylhydrazyl radical (DPPH) turned to pale yellow of picryl group because of its reduction by hydrogen ion from the free radical of the sample. Ascorbic acid exhibited the highest percent inhibition of DPPH radicals of $99.6 \pm 4.13\%$.

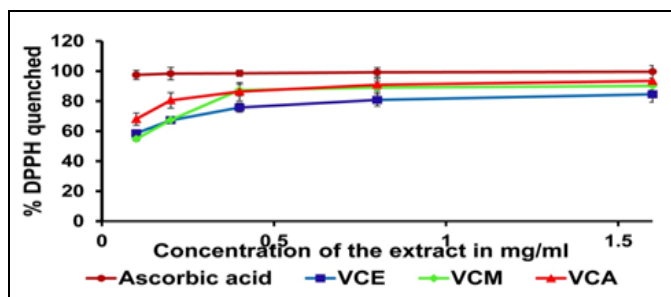


FIG. 1: CONCENTRATION-DEPENDENT % INHIBITION OF DPPH RADICAL BY DIFFERENT EXTRACTS OF *V. CALYCVLATA* AND THE ASCORBIC ACID VCM = METHANOLIC EXTRACT OF *V. CALYCVLATA*; VCM = methanolic extract of *V. calyculata*; VCA = aqueous extract of *V. calyculata*; VCE = ethyl acetate extract of *V. calyculata*

The different extracts of *V. calyculata* showed the following percentage inhibition of DPPH radicals-VCE (82.22 ± 5.10 %), VCM (90.8 ± 5.21 %), and VCA (93.41 ± 6.11 %). Scavenging of DPPH radical of different extracts and ascorbic acid showed were concentration-dependent a good, as obvious from the graph in Fig. 1.

Physio-chemical Evaluation of the Topical Preparations:

Testing of all the topical herbal hydrogels (F1, F2, F3, and F4) showed that they were homogeneous with pH value (6.4 to 7.4). The spreadability and viscosities were also found to be ideal for a hydrogel preparation.

Test of Dermal Irritation: The treatment with various hydrogel preparations at 2000 mg/kg topically body weight of rats exhibited no signs of toxicity and mortality after observing for 14 days in both the treated and control animals. So, the 1/10th value of the dose was selected for the experimental study.

Excision Wound Protocol:

(A) % Wound Contraction: The results of % wound closure in Table 2 and pictogram in Fig. 2 indicate that the area of each wound contracted with time. There was no significant difference in wound closure between each group till the dexamethasone was administered *i.e.*, day 10. Subsequently, on day 20, Group I (normal) showed 100% wound closure and other treatment groups a higher percentage of wound closure compared with the untreated group. In untreated Group III (Decdan[®], *i.p.*) the wounds were open even after 30 days in Table 2 and Fig. 2.

(B) Evaluation of Epithelialisation Process:

There was a significant difference in the period of re-epithelialization in the treated and the untreated groups, as evident from Table 2.

The process of re-epithelialization was noticed to be fastened in Group I (normal group-Carbopol base+saline) - 15.6 ± 1.1 ($p < 0.01$) days and in Group II (positive control-SSDeeUltra cream+Decdan[®])- 19.6 ± 1.6 ($p < 0.01$) days, ranged between 18.33-26.3 days in various treatment Groups IV-VI ($p < 0.01$), Table 2 compared to Group III-(Untreated-Decdan[®]) which was found to be maximum at 26.3 ± 1.9 days ($p < 0.01$).

TABLE 2: EFFECT OF TOPICAL APPLICATION OF REFERENCE FORMULATION AND HYDROGELS FORMULATED FROM VARIOUS EXTRACTS OF *V. CALYCVLATA* AGAINST DEXAMETHASONE-SUPPRESSED HEALING IN RATS

| | Group I | Group II | Group III | Group IV | Group V | Group VI | Group VII |
|---|---------------------|-----------------------|------------------------|------------------------|------------------------|-----------------------|-----------------------|
| (a) Wound region (mm²) and wound closure (%) | | | | | | | |
| Oral administration of Decdan® (dexamethasone) initiated | | | | | | | |
| 0 th day | 6.3±0.2 | 6.7±0.4** | 6.8±0.5** | 6.6±0.33** | 6.6±0.18** | 6.7±0.4** | 6.8±0.4** |
| 5 th day | 4.1±0.1 (35.65%) | 6.0±0.6** (10.5%) | 6.6±0.3** (3.58%) | 6.4±0.34** (2.90%) | 6.4±0.28** (2.31%) | 6.3±0.3** (4.50%) | 6.2±0.3** (5.82%) |
| 10 th day | 2.2±0.1 (63.77%) | 5.2±0.3** (22.21%) | 6.3±0.4** (7.74%) | 6.2±0.27** (6.80%) | 5.8±0.25 (11.35%) | 5.9±0.6** (11.94%) | 5.9±0.3** (13.39%) |
| Decdan® (dexamethasone) stopped and dressed with hydrogel preparations/marketed hydrogel | | | | | | | |
| 15 th day | 1.2±0.1 (80.35%) | 4.2±0.3* (32.07%) | 6.1±0.2** (10.41%) | 5.8±0.12** (12.41%) | 5.3±0.16** (19.02%) | 5.5±0.4** (17.29%) | 5.6±0.4** (17.29%) |
| 20 th day | 0±0 (100%) | 2.5±0.2** (61.95%) | 3.6±0.2** (47.26%) | 3.1±0.23** (52.65%) | 3.3±0.30 (49.40%) | 2.6±0.2** (60.77%) | 1.9±0.2** (60.77%) |
| 25 th day | 0±0 (100%) | 0±0** (100%) | 2.6±0.1** (61.06%) | 1.1±0.26** (82.23%) | 0.9±0.18** (85.39%) | 0.7±0.3** (88.90%) | 0.5±0.3** (88.90%) |
| 30 th day | 0±0 (100%) | 0±0** (100%) | 1.29±0.1** (81.16%) | 0±0** (100%) | 0±0** (100%) | 0±0** (100%) | 0±0** (100%) |
| (b) Epithelization period | | | | | | | |
| | 15.6±1.1* | 19.6±1.6* | 26.3±1.9** | 22.67±3.3** | 18.33±0.4** | 20.67±1.8** | 20.3±1.4** |

All data expressed as mean ± SD; n=6; *p<0.05, **p<0.01 (Comparison of I, II, IV, V, VI with III) where Group I: normal group (Hydrogel base +Saline); Group II: positive control group (SSDeeUltra++ Decdan®); Group III: untreated group (Decdan® only); Group IV-VI: treatment groups administered with HF1+ Decdan®/HF2+ Decdan®/HF3+ Decdan® respectively

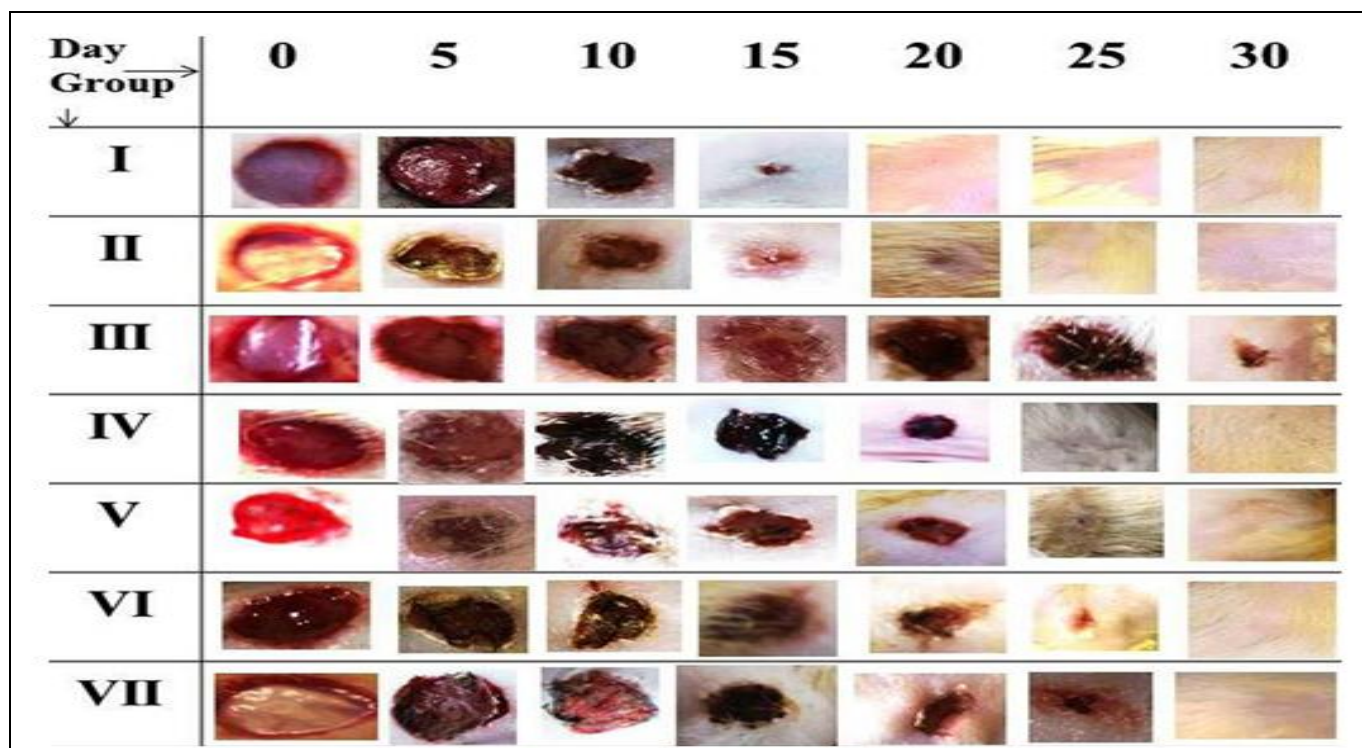


FIG. 2: PICTOGRAPHIC REPRESENTATION OF WOUND CLOSURE- NORMAL, POSITIVE, UNTREATED, AND TREATMENT GROUPS (HYDROGELS OF *VENTILAGO CALYCVLATA* EXTRACTS) AGAINST DEXAMETHASONE-SUPPRESSED EXCISION WOUND REPAIR IN RATS

Incision Wound Protocol:

(A) Analysis of Biochemical Marker (hydroxyproline): Hydroxyproline content of Group VII (aqueous extract) was found to be the maximum - 46.6 ± 1.29 i.e., 2.0-fold ($p < 0.01$), in comparison

to the untreated group against dexamethasone delay on the 30th day. The readings are presented in Fig. 3A. It was computed from the calibration curve according to the equation $Y = 0.006X - 0.022$, $R^2 = 0.989$.

(B) Wound Breaking Strength: The wound breaking strengths of the incised wounds of rats belonging to Group VII (aqueous extract) were found to be the maximum *i.e.*, 2.0-fold ($p < 0.01$),

in comparison to the untreated group against dexamethasone delay on the 30th day. The measurements are presented in **Fig. 3B**.

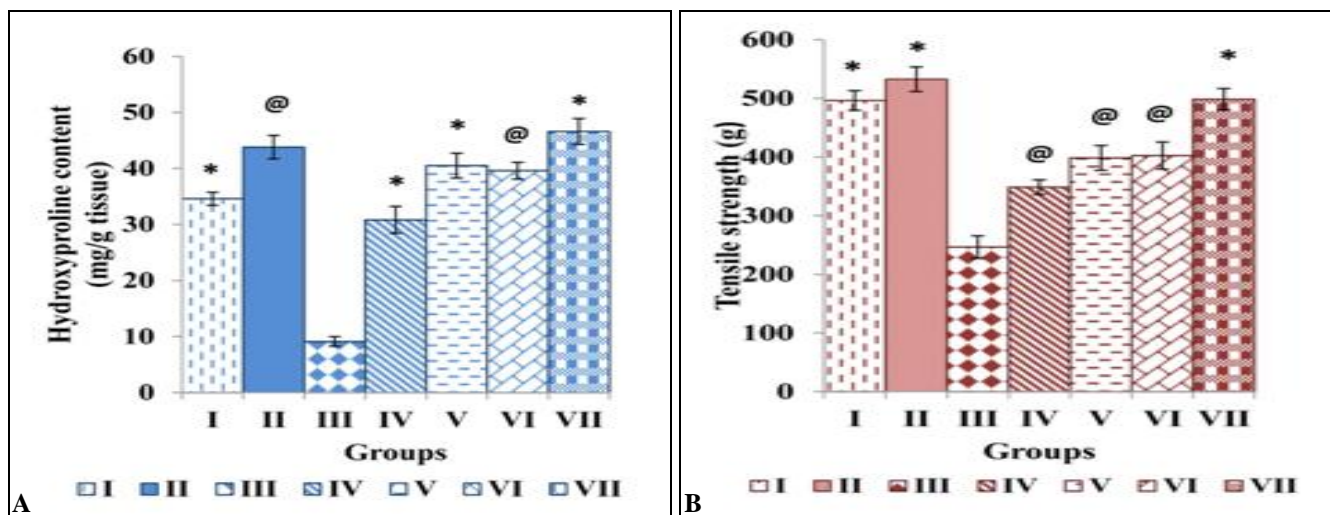


FIG. 3: EFFECT OF TOPICAL APPLICATION OF STANDARD FORMULATION AND HYDROGELS FORMULATED FROM VARIOUS FRACTIONATES OF *V. CALYCVLATA* ON (A) HYDROXYPROLINE (B) TENSILE STRENGTH AGAINST DEXAMETHASONE (DEC DAN®) DELAY ON INCISION WOUND IN RATS ON DAY 30 POST-WOUNDING. All data expressed as mean ± SD; n = 6; @p < 0.05, *p < 0.01; when compared to Group III. Group I: normal group (Carbopol base+Saline); Group II: standard group (SSDeeUltra++Decdan®); Group III: untreated group (Decdan® only); Group IV-VII: treatment groups administered with Decdan®/HF1+Decdan®/HF2+Decdan®/HF3+Decdan®/HF4, respectively

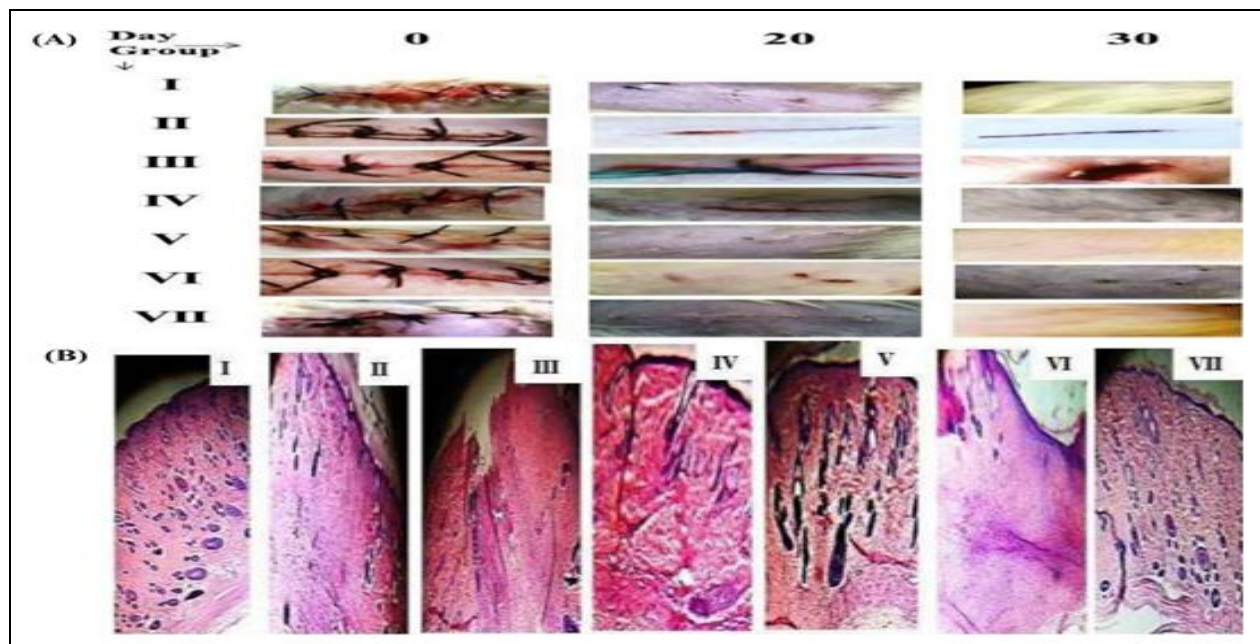


FIG. 4: (A) MACROSCOPIC REPRESENTATION OF INCISION WOUND HEALING OF NORMAL, POSITIVE, UNTREATED AND TREATMENT GROUPS (B) HISTOPATHOLOGIC REPRESENTATION: H&E STAINED SECTION OF SKIN AT DAY 30 (40X). Group I (normal-hydrogel base); Group II (positive control - SSDee Ultracream+Decdan® Group III (Untreated group-Decdan®); Group IV (HF1+Decdan®); Group V (HF2+Decdan®); Group VI (HF3+Decdan®)

(C) Microscopic Morphometric Examination: The histomorphological inspection of skin incisions on the 30th postoperative day revealed that original

tissue regeneration was much greater in rats of treatment groups to be recovered successfully, closed in normal, standard, and the treatment

groups and there was no significant variation. In contrast, the skin of the rats of untreated groups still had opened incisions **Fig. 4A**. In dexamethasone-suppressed incision wound protocol, complete re-epithelialisation of the wound area was observed in all groups except Group III. The histomorphological inspection of the dermal tissue of the untreated group exhibited prolonged inflammation with increased neo-angiogenesis, few fibroblasts and bundle of collagen fibers on day 30. Group, I showed a neo-generated epithelium that appeared thin. An interdigitation between epithelium and dermis, a large number of well-organized collagen fibers were also observed in the skin of rats in Groups II and VII, suggesting stronger integrity of skin **Fig. 4B**.

DISCUSSION: Dexamethasone, prototype steroidal anti-inflammatory drug, is a widely used analgesic, antipyretic, and an anti-emetic with chemotherapy. In addition to its widely known side effect of promoting bleeding events, it also inhibits wound healing. It delays wound healing by various mechanisms, and nearly all phases of wound repair are affected by it²³. The findings of this investigation revealed that the repair was retarded due to intake of dexamethasone in all the groups (except the normal) till dexamethasone was fed orally (day 10) Wound contraction leads to wound closure which is necessary for restoring the functional barrier. An incredible repair pattern was noted in the extract-treated groups after the 10th day resulting in complete wound closure between 20-25 days in comparison to the untreated group which failed to heal even till day 30.

It was observed that Group VI applied with HF3/aqueous extract of *V. calyculata* (VCA) hydrogel did not only reverse but also accelerate the dexamethasone-retarded wound repair process in both excision and incision models in rats. The findings of the excision wound model revealed that Group VI applied with HF3/VCA hydrogel showed maximum wound contraction and a shortened period of epithelialization after discontinuing dexamethasone. In the incision wound model, the increase in the tensile strength reveals better wound healing as a result of applying the herbal formulation. Tensile strength in wounds closed under tension appeared to be related to the large quantity of collagen and fibroblasts.

Highly cross-linked collagen may be an additional reason leading to the higher tensile strength of wounds in rats of the treatment group²⁴. The increment in breaking strength was correlated with the increase in the hydroxyproline levels in the Group VI applied with HF3/VCA hydrogel and histopathology results.

In the same wound model, the dexamethasone-fed untreated animals (Group III) displayed suppressed wound repair, as verified by incomplete wound closure, an extended period of epithelialization, a significant reduction in granulation breaking strength and hydroxyproline level, the histopathology results revealed several inflammatory cells at the site of the wound.

It is reported that when phytochemicals with potent free-radical-scavenging properties are applied topically in patients, the wound repair is accelerated; therefore, antioxidant studies were also undertaken²⁵. The results establish the ability of VCA (or HF3) to scavenge ROS molecules in vitro, which are likely to be owing to the pharmacologically active phytochemicals, present individually or additively in the extract. This was reported in our recent previous study on the plant on aspirin-retarded wound repair process.

Although traditional medicines offer a safe, inexpensive approach to the treatment of wounds, it has not received adequate attention. The current study justifies the wound healing related ethnopharmacological uses of *V. calyculata*, which could possibly be made use clinically for healing wounds in patients on long-term dexamethasone therapy.

ACKNOWLEDGEMENT: The experimental facilities of the Faculty of Pharmacy, VNS Group of Institutions, Bhopal, M. P., India, were used to carry out this research work. The research work was financially supported by the Indian Council of Medical Research, New Delhi, and the Government of India with Fellowship (SRF-ICMR).

CONFLICTS OF INTEREST: The authors declare that they have no conflicts of interest.

REFERENCES:

1. Nayak BS, Suresh Rao AVC, Pillai GK, Davis EM, Ramkissoon V and Mc Are A: Evaluation of wound

- healing activity of *Vandarox burghii* R.Br (Orchidaceae)- A preclinical study in rat model. International Journal of Lower Extremity Wounds 2005; 4: 200-04.
2. Tripathi KD: Corticosteroids in essentials of medical pharmacology. Jaypee Brothers Medical Publishers, New Delhi, Edition 7th, 2013: 282-95.
 3. Polderman JA, Farhang-Razi V, Van Dieren S, Kranke P, DeVries JH, Hollmann MW, Preckel B and Hermanides J: Adverse side effects of dexamethasone in surgical patients. Cochrane Database of Systematic Reviews 2018; 8: 6-8.
 4. Ehrlich HP and Hunt TK: Effects of cortisone and Vitamin A on wound healing. Annals of Surgery 1968; 167: 324-28.
 5. Kumar S, Balakrishnan N, Lakshmi PK, Toppo FA and Pawar RS: Pharmacognostical and phytochemical evaluation of *Ventilago calyculata* Tul. (Bark). Pharmacognosy Journal 2015; 7: 271-75.
 6. Adhikari BS, Babu MM, Saklani PL and Rawat GS: Medicinal plants diversity and their conservation status in wildlife, Dehradun. Ethnobotanical Leaflets 2010:14:46.
 7. Parrotta K: Study on healing plants of Peninsular India, CABI publishing, Wallingford, UK 1978; 602-03.
 8. Harborne JB: Phytochemical Methods a Guide to Modern Techniques of Plant Analysis, third ed., Chapman and Hall, UK. 1998.
 9. Magalhães LM, Santos F, Segundo MA, Reis S and Lima JL: Rapid microplate high-throughput methodology for assessment of Folin-Ciocalteu reducing capacity. Talanta 2010; 83: 441-47.
 10. Yang H, Dong Y, Du H, Shi H, Peng Y and Li X: Antioxidant compounds from propolis collected in Anhui, China. Molecules 2011; 16: 3444-55.
 11. Khan AW, Kotta S, Ansari SH, Sharma RK, Kumar A and Ali J: Formulation development, optimization and evaluation of Aloe vera gel for wound healing. Pharmacognosy Magazine 2013; 9: S6-S10.
 12. Das S, Haldar PK and Pramanik G: Formulation and evaluation of herbal gel containing Clerodendron infortunatum leaves extract. International Journal of Pharmtech Research 2011; 3: 140-43.
 13. OECD, 2000b. OECD Guideline for Testing of Chemicals, No. 404. Acute Dermal Toxicity-Fixed Dose Procedure. Paris, France: Organization for Economic Cooperation and Development Publishing 1-3.
 14. OECD, 2004. OECD Guideline for Testing of Chemicals, No. 434. Acute Dermal Toxicity-Fixed Dose Procedure. Paris, France: Organization for Economic Cooperation and Development 4-5.
 15. Tsala DE, Nga N, Thiery BNM, Bienvenue MT and Theophile D: Evaluation of the antioxidant activity and the healing action of the ethanol extract of *Calotropis procera* bark against surgical wounds. Journal of intercultural ethnopharmacology 2015; 4: 64-69.
 16. Masre SF, Yip GW, Sirajudeen KN and Ghazali FC: Wound healing activity of total sulfated glycol-saminoglycan (GAG) from *Sticho pusvastus* and *Sticho pushermanni* integumental tissue in rats. International Journal of Molecular Medicine and Advance Sciences 2010; 6: 49-53.
 17. Thakur R, Jain N, Pathak R and Sandhu SS: Practices in wound healing studies of plants. J Evidence Based Complementary Alternative Medicine 2011: 1-17.
 18. Rao CV, Sairam K and Goel RK: Experimental evaluation of Bacopa moniera on rat gastric ulceration and secretion. Indian Journal of Physiology and Pharmacology 2000; 44: 435-41.
 19. Rashed A: A simple evaluation of the wound healing activity of a crude extract of *Portulaca oleracea* L. (growing in Jordan) in Mus musculus JVI-1. Journal of Ethnopharmacology 2003; 88: 131-36.
 20. Dwivedi D, Dwivedi M, Malviya S and Singh V: Evaluation of wound healing, anti-microbial and antioxidant potential of *Pongamia pinnata* in Wistar rats. Journal of Traditional and Complementary Medicine 2017; 7: 79-85.
 21. Woessner JF: The determination of hydroxyproline in tissue and protein samples containing a small proportion of this amino acid. Archives of Biochemistry and Biophysics 1961; 93: 440-47.
 22. Zandifar E, Sohrabi BS, Zandifar A and Haghjooy JS: The effect of captopril on impaired wound healing in experimental diabetes. International Journal of Endocrinology 2012; 1-6.
 23. Wang AS, Armstrong EJ and Armstrong AW: Corticosteroids and wound healing: Clinical considerations in the perioperative period. Am J of Surgery 2013; 206: 410-17.
 24. Madden JW and Peacock EE: Studies on the biology of collagen during wound healing: the rate of collagen synthesis and deposition in cutaneous wounds of the rat. Surgery 1968; 64: 288-95.
 25. Ghosh S, Derle A, Ahire M, More P, Jagtap S, Phadatare SD, Patil AB, Jabgunde AM, Sharma GK, Shinde VS and Pardesi K: Phytochemical analysis and free radical scavenging activity of medicinal plants *Gnidia glauca* and *Dioscorea bulbifera*. PLOS One 2013; 8(12): e82529.

How to cite this article:

Kumar S, Jain D and Pawar RS: Alleviation effect of *Ventilago calyculata* against dexamethasone delayed wound healing. Int J Pharm Sci & Res 2021; 12(1): 347-55. doi: 10.13040/IJPSR.0975-8232.12(1).347-55.

All © 2013 are reserved by the International Journal of Pharmaceutical Sciences and Research. This Journal licensed under a Creative Commons Attribution-NonCommercial-ShareAlike 3.0 Unported License.

This article can be downloaded to **Android OS** based mobile. Scan QR Code using Code/Bar Scanner from your mobile. (Scanners are available on Google Playstore)