



Received on 10 April, 2013; received in revised form, 18 May, 2013; accepted, 26 July, 2013; published, 01 August, 2013

EVIDENCE BASED HOMOEOPATHY IN TREATING LONG STANDING & RECURRING VENOUS ULCER- A PROSPECTIVE AND INTERVENTIONAL STUDY

Chandranath Das

Metropolitan Homoeopathic Medical College & Hospital, Sodepur, West Bengal, India

Keywords:

Venous ulcer, Homoeopathy,
Prospective, Interventional study

Correspondence to Author:

Chandranath Das

Madhyakalyan pur, P.O. + P.S.-
Baruipur, District- South 24
Parganas, Kolkata-144, West
Bengal, India

E-mail: dr.cndas@rediffmail.com

ABSTRACT: The common cause of leg ulceration in Western countries is venous disease of the lower limb. Venous insufficiency causes appreciable disability. Venous ulcer is one of the most prevalent diseases in the western countries and India, which can hamper personal and professional life of individual. After various methods of modern medicinal treatment and management there is a chance recurrence. This case study is a prospective and intervention to combat long standing & recurring venous ulcer aided by Homoeopathy.

INTRODUCTION: The incidence of venous ulcer in the lower limb due to venous disease is about 60% to 70% of all ulcer of lower limb. Characteristically, the venous ulcer develops in the gaiter area of the lower leg, medially from the instep to above the ankle. Malignant change may complicate a long-standing venous ulcer¹. Venous ulcers are accompanied by lipodermatosclerosis and haemosiderosis^{1, 2, 3}. By the modern medicinal treatment different bandaging regimens, compression stocking, different surgical method have been used^{1, 2}. Different antibiotics do not hasten ulcer healing in absence of cellulitis and other specific ulcer healing medicines are of suspicious validity. After various methods of modern medicinal treatment there is a 20-30 per cent incidence of reulceration by five years¹.

By the alternative way of treatment introducing of low cost medicine may eradicated the venous ulcer.


Material and Method: Taking of the case, find out totality of symptoms. Selected the similimum on basis of individualize of the patient and miasmatic consideration. A 30 years old male presented with venous ulcer at Homoeo specialty clinic, Uluberia Subdivisional Hospital, Uluberia, Howrah, Govt. of West Bengal on 09/06/2011. Patient written consent was taken for study.

Taking the case:

Chief complaint with duration : An ulcer on right leg, near medial malleolus (**Fig. 1**) and having varicosity of lower limbs and thin discharges was came from it, for 8 years.

On examination: An ulcer measure 3.5cm X 2.5cm with stepping margins. Floor- yellowish pink, Edge-irregular but well defined, thin discharges were coming from it, dark pigment around it.

H/o Present complaint: Two times treated with surgery but ulcer was recurring again.

<p>QUICK RESPONSE CODE</p> 	<p>DOI: 10.13040/IJPSR.0975-8232.4(8).3266-69</p>
<p>Article can be accessed online on: www.ijpsr.com</p>	
<p>DOI link: http://dx.doi.org/10.13040/IJPSR.0975-8232.4(8).3266-69</p>	

Past History: Leg injury at childhood, carbuncle at 20 years age.

Family History: Rheumatism. Occupation: Barber

Physical General:

Appetite: less, **Desire:** salt. **Intolerance:** meat, egg. **Thirst:** Moderate, **Stool:** constipation. **Urine:** 4 – 6 times /day, can hold it. **Sleep:** regular, **Sweat:** on face and palm. **Thermal reaction:** hot patient.

Mental General: easily anger.

Totality of Characteristics Symptoms:

- 1) Ulcer on right leg, near medial malleolus and having varicosity of lower limbs and thin discharges from it,
- 2) H/o Leg injury at childhood & carbuncle,
- 3) Desire for salt,
- 4) Intolerance to meat, egg,
- 5) Sweat on face and palm,
- 6) Hot patient,
- 7) Easily anger.

Treatment and follow-up: *Natrum mur* 200 was prescribed orally along with *Calendula Q* for dressing the ulcer which improved the discharge from the ulcer but there was no sign of healing. *Arnica* 200 was prescribed after 5 days based on strong history of injury. The ulcer started healing but a burning sensation appeared at the ulcer side.

Arsenicum album 30 was prescribed after 2 months. In the next visit after 6 days, the burning disappeared but the patient developed a cough which was unrelated to the disease. On the basis of present symptoms *Ipecac* 30 was prescribed. Patient visited the OPD after 1 month and the ulcer heal by 75% (Fig. 2).

Re-case record:

Chief complaint with duration: ulcer on right leg, near medial malleolus and having varicosity of lower limbs.

Physical general:

Appetite: Cannot tolerate hunger, **Desire:** salt, sweet. **Intolerance:** egg. **Thirst:** moderate, **Stool:** regular. **Urine:** 5 – 6 times /day, can hold it. **Sleep:** regular, **Sweat:** on face and palm. **Thermal reaction:** hot patient.

Mental General: easily anger.

Totality of Characteristics Symptoms:

- 1) Ulcer on right leg, near medial malleolus and having varicosity of lower limb
- 2) Desire for salt and sweet
- 3) Intolerance to egg,
- 4) Sweat on face and palm,
- 5) Hot patient.
- 6) Easily anger.

Treatment and follow up: After re-case taking *Nat sulph* 200 was prescribed. Patient return after 8 days as the discharge started from the ulcer. Re-case taking was done.

Chief complaint: ulcer on right leg, near medial malleolus and having varicosity of lower limbs and thin watery discharge emitted from it.

Physical general:

Appetite: Cannot tolerate hunger, **Desire:** warmth things, salt, sweet. **Intolerance:** cabbage causes dyspepsia. **Thirst:** moderate, **Stool:** regular. **Urine:** 5 – 6 times /day, can hold it. **Sleep:** disturbed at night but feels drowsy at day time. **Sweat:** on face and palm. **Thermal reaction:** hot patient.

Mental General: sadness, loss of confidence.

Totality of Characteristics Symptoms:

- 1) Ulcer on right leg, near medial malleolus and having varicosity of lower limb and thin discharge was came from it.
- 2) Desire for warmth things, salt and sweet
- 3) Intolerance to cabbage causes dyspepsia,
- 4) Feels drowsy at day time.
- 5) Sweat on face and palm,
- 6) Hot patient.
- 7) Sadness of mind, loss of confidence.

Treatment and follow up: Lycopodium1M was prescribed. After 11 days, no such result occurred except the change in discharge that was of pus, Calc sulphur 30 was prescribed. Discharge absent with healthy granulation tissue at ulcer site, but few cracks were still present and slight pain appeared.

Silicea 200 was prescribed which completed the case (**Fig. 3**).

RESULT: Ulcer on right leg near medial malleolus (**fig. 1**) has been disappeared after completion of treatment (**fig. 3**).

TABLE 1: PROTOCOL OF TREATMENT

Date	Medicine	Remark
09.06.11	<i>Natrum Mur</i> 200/2d/0d	First prescription
14.06.11	<i>Arnica</i> 200/2doses/od	improved
12.08.11	<i>Ars alb</i> 30/8doses/bd	Changing symptoms
18.08.11	<i>Ipec</i> 30/2 doses/od	improved
01.09.11	<i>Natrum sulph</i> 200/2doses/od	Changing symptoms
9.09.11	<i>Lycopodium</i> 1m/1dose/od	Changing symptoms
22.09.11	<i>Calc sulph</i> 30/4doses	improved
03.11.11	<i>Silicea</i> 200/2doses/od	May cure

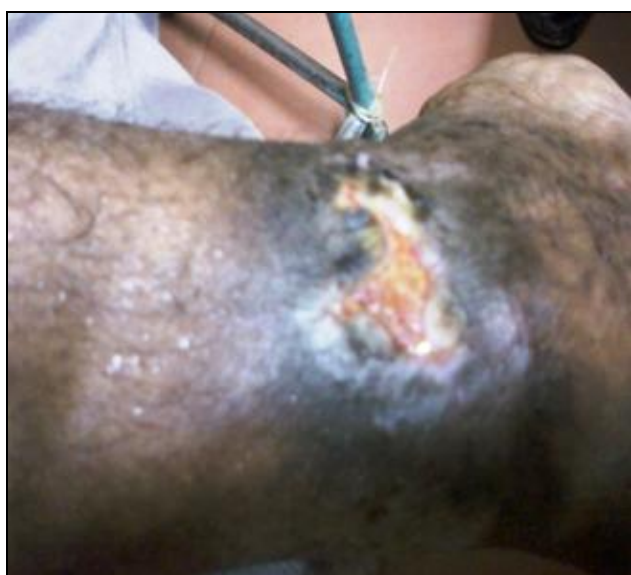

FIG. 1: VENOUS ULCER BEFORE TREATMENT

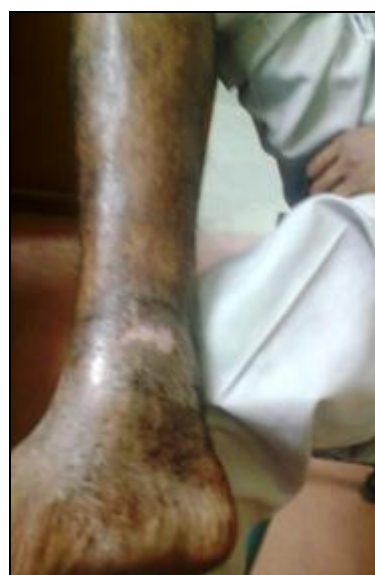

FIG. 3: VENOUS ULCER AFTER TREATMENT

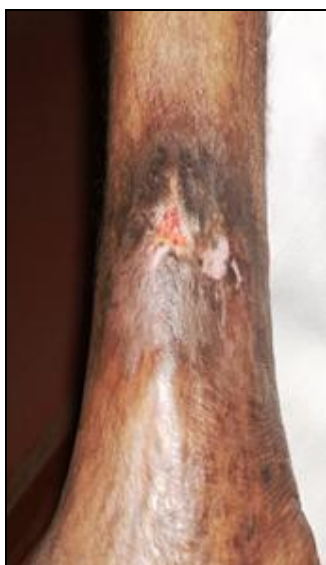

FIG. 2: VENOUS ULCER DURING TREATMENT

DISCUSSION: After scrutinizing the case, I diagnosed the venous ulcer due to professional hazard but the person must continue his profession. Homoeopathic medicine can successfully treat the venous ulcer and varicose vein. All the diseases known to man have their likeness in the *Materia Medica* and the physician must be so conversant with this art that he may perceive this likeness. All the senses must be on the alert in order to perceive that which similar, and most similar 4. After taking of the case, finding out totality of the symptoms, I selected *similimum* and before prescribing, I verified every time with *Materia Medica*.

For rapid and gentle cure, I find out the uncommon, peculiar, rare symptoms of the case. The objective of this study was to evaluate the role of classical Homoeopathy in venous ulcer and larger trials in future may suggest.

Calendula officinalis is one of the most remarkable healing agents⁵. I have used these medicines locally to cure the ulcer. By alternative way of treatment, small doses of less expensive medicine was introduced orally and by regularly dressing with calendula Q, the venous ulcer was disappeared as well as varicosity of leg disappeared permanently. Discharges from the ulcer also disappeared. Venous ulcer did not appear again after completed the treatment.

CONCLUSION: By means of nano pharmacology like Homoeopathy including oral and local application of medicine ameliorates venous ulcer and varicosities of leg within very short span of time.

ACKNOWLEDGEMENT: With a profound sense of gratitude, I express my sincere respect to the Director of Homoeopathy, Govt. of west Bengal

and Superintended, Uluberia Sub Divisional Hospital, Howrah, Govt. of West Bengal for allow me to conduct the work.

REFERENCES:

1. Norman S. Williams, Christopher J.K. Bulstrode, P. Ronan Oconnell: Bailey & Loves, Short Practice of Surgery. CRC Press, Boca Raton, Edition 26, 2013:237-250
2. Courtney M. Townsend, Jr., R. Daniel Beauchamp, B. Mark Evers, Kenneth L. Mattox: Sabiston Text Book of Surgery, The Biological Basis Of Modern Surgical Practice. Elsevier, a division of Reed Elsevier India Private Limited, New Delhi, Edition 19, Vol.II, 2012:1805-1812
3. Schwartz, Shires, Spencer: Principles of Surgery. Mc Graw-Hill, United State of America, Edition 6, Vol. I, 1969:1003-1005
4. James Tyler Kent: Lectures on Homoeopathic Philosophy. Modern Homoeo Publication, Kolkata, Edition 2, 1990:182-183.
5. Boericke William: Homoeopathic Materia Medica Comprising, The Characteristic And Guiding Symptoms Of All Remedies (Clinical And Pathogenetic). Modern Homoeo Publication, Kolkata, Edition 9, 2011: 156.

How to cite this article:

Das C: Evidence based Homoeopathy in treating long standing & recurring venous ulcer- A prospective and interventional study. *Int J Pharm Sci Res* 2013; 4(8); 3266-3269. doi: 10.13040/IJPSR.0975-8232.4(8).3266-69

All © 2013 are reserved by International Journal of Pharmaceutical Sciences and Research. This Journal licensed under a Creative Commons Attribution-NonCommercial-ShareAlike 3.0 Unported License.

This article can be downloaded to **ANDROID OS** based mobile. Scan QR Code using Code/Bar Scanner from your mobile. (Scanners are available on Google Playstore)