



Received on 28 March 2023; received in revised form, 12 May 2023; accepted 25 August 2023; published 01 November 2023

## CERVICAL POLYP TREATED WITH INDIVIDUALIZED HOMOEOPATHIC MEDICINE - CASE REPORT

S. Kadam <sup>\* 1</sup>, P. Lamba <sup>1</sup>, D. B. Sharma <sup>2</sup>, P. A. Chaphekar <sup>1</sup> and P. Aphale <sup>3</sup>

Department of Homoeopathic Materia Medica <sup>1</sup>, Department of Forensic Medicine <sup>2</sup>, Department of Homoeopathic Pharmacy <sup>3</sup>, Dr. D. Y. Patil Homoeopathic Medical College & Research Centre, Pimpri, Pune, Maharashtra, Dr. D. Y. Patil Vidyapeeth, Pimpri, Pune - 411018, Maharashtra, India.

### Keywords:

Natrum muriaticum, Homoeopathy, Cervical polyp, Case report

### Correspondence to Author:

**Dr. S. Kadam**

P. G. Scholar,  
Department of Homoeopathic Materia Medica, Dr. D. Y. Patil Homoeopathic Medical College & Research Centre, Pimpri, Pune, Maharashtra, Dr. D. Y. Patil Vidyapeeth, Pimpri, Pune - 411018, Maharashtra, India.

**E-mail:** kadamsurabhi1693@gmail.com

**ABSTRACT:** A known case of a cervical polyp of a 26-year-old woman presented in the Outdoor-patient Department of Dr. D. Y. Patil Homoeopathic Medical College and Research Centre with complaints of abnormal bleeding in between periods, pain after coition, and profuse white discharge. USG reports confirmed the diagnosis of the cervical polyp. After a detailed history taking of the patient and considering a complete totality of symptoms, Natrum Muriaticum 30C, a single individualized homeopathic medicine, was prescribed to the patient, and it proved effective in the treatment of cervical polyp. The patient slowly showed improvement in physical symptoms, followed by mental symptoms. Modified Naranjo Criteria were used, and regular follow-ups were taken to assess the case. This case demonstrates the usefulness of homeopathic medicines in psychosomatic diseases wherein the psychological cause is the main cause of the disease in the patient. Also, this case shows the effectiveness of Homoeopathic remedies in the treatment of cervical polyps. It can be looked at as an alternative method of treatment with further research on the same.

**INTRODUCTION:** Cervical polyps are excess non-cancerous growths arising from end cervical tissue that protrudes in the cervical canal and are the most common condition in gynecological practice <sup>2</sup>. to 5 % of women are at risk of developing cervical polyp <sup>1</sup>. The etiology of cervical polyps is not clearly understood. Risk factors that contribute to the development of polyps are chronic inflammation due to recurrent infection, hormonal disturbances, past history of pregnancy, and endometrial hyperplasia.

Presenting symptoms of polyp is intermenstrual bleeding, abnormal discharge from the vagina, post coition bleeding, painful menses, and heavy bleeding during menses. Many of the patients remain asymptomatic <sup>1, 8</sup>.

If left untreated, there are 0.2% to 1.5% chances of malignancy. Other common complications are infertility, bleeding, and recurrence <sup>1, 3</sup>. In modern medicine, there is no medicinal treatment for polyps; the main line of treatment is the surgical removal of polyps <sup>10</sup>.

The present case report supports the earlier studies conducted on cervical polyps, which were treated with homeopathy <sup>4</sup>. This case is presented for the further scope of homeopathy in managing cases of cervical polyp and to be considered as an alternative method of treatment in such cases.

<p><b>QUICK RESPONSE CODE</b></p> 	<p><b>DOI:</b> 10.13040/IJPSR.0975-8232.14(11).5526-31</p> <hr/> <p>This article can be accessed online on <a href="http://www.ijpsr.com">www.ijpsr.com</a></p>
<p><b>DOI link:</b> <a href="https://doi.org/10.13040/IJPSR.0975-8232.14(11).5526-31">https://doi.org/10.13040/IJPSR.0975-8232.14(11).5526-31</a></p>	

**Patient Information:** This is a known case of a cervical polyp of a 26-year-old married woman pre-diagnosed by gynecologists who came to the Outdoor Patient Department on 28/09/21 with complaints of abnormal bleeding post menses for 2 months. Profuse white discharge before menses irritating the parts. Pain after coition. Other associated complaints were heavy flow during menses, <at night. Throbbing headache, which was worse in the morning. Frequent episodes of headache since complaints.

**Past History:** H/o urticaria 10yrs back treated with homoeopathy. H/o hematuria 6 months back. Took allopathic treatment for same.

**Family History:** Father–Diabetes Mellitus for 2 years.

**Personal History:** Appetite - Adequate.

**Desire:** She has a habit of eating bit of salty food.

**Sleep:** Disturbed due to irregular routine sleep after 2- 3.00 am.

**Menstrual History:**

**Age of Menarche:** 13 years.

**L.M.P:** 06/09/21.

**Menses:** Regular.

**Duration and Cycle:** 8-10 days / 28days

**Bleeding:** Heavy flow since 2 months (3-4 pads/day).

**Clots:** Intermittent clots.

**Complaints during Menses:** Cramps during menses ++ with low back pain. Sometimes, it is associated with nausea and vomiting. Takes Tab. Meftal Spas on the first day of menses. Leucorrhea before menses.

**Obstetric History -P0:** No major past Gynecological history. H/O repeated vaginal infection.

**Mental Symptoms:** She belongs to a middle-class family working in an IT company. When enquired about her nature according to her, she becomes easily angry. Angry, especially when consoled. Cannot tolerate any consolation. Cries when alone

thinking of past events. She gets very irritable, especially after menses and coition. There has been emotional turmoil in the patient since she got married and shifted to Pune from Mumbai. She is not able to adapt to the culture of her current place, and constant minor health issues make her much more irritable. According to her, she has gone through many adverse events in the past that she was not willing to reveal.

**Clinical Findings:** P/A – Soft. Mild tenderness in the lower abdomen. P/S – Erosion on the anterior lip of the cervix with polyp protruding the cervix. White discharge +++. Redness of vulva +

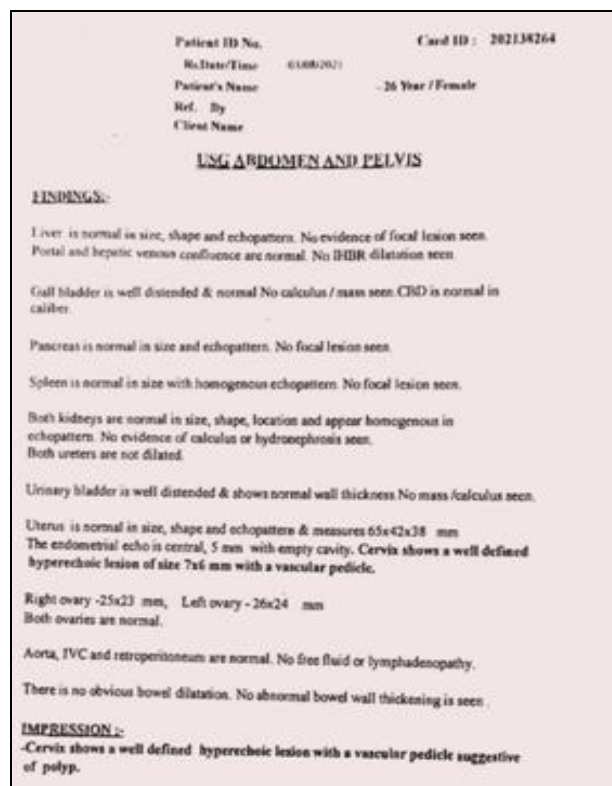
**Laboratory Investigations:** CBC (04/08/21): Hb – 13.4%; WBC – 8,500; Platelet – 339 10<sup>3</sup>/ul

**Glucose Random:** 81mg/dl; T3 – 129 ng/dl, T4 – 7.88 microgram/dl, TSH – 3.38 uIU /mL

**USG Abdomen and Pelvis:** Refer to Fig. 1.

**Uterus Normal:** ET- 5MM. Cervix shows a 7 x 6 mm hyperechoic lesion with a vascular pedicle suggestive of the polyp.

**Diagnosis:** Cervical Polyp.



**FIG. 1: ULTRASONOGRAPHY ABDO-PELVIS (BEFORE TREATMENT)**

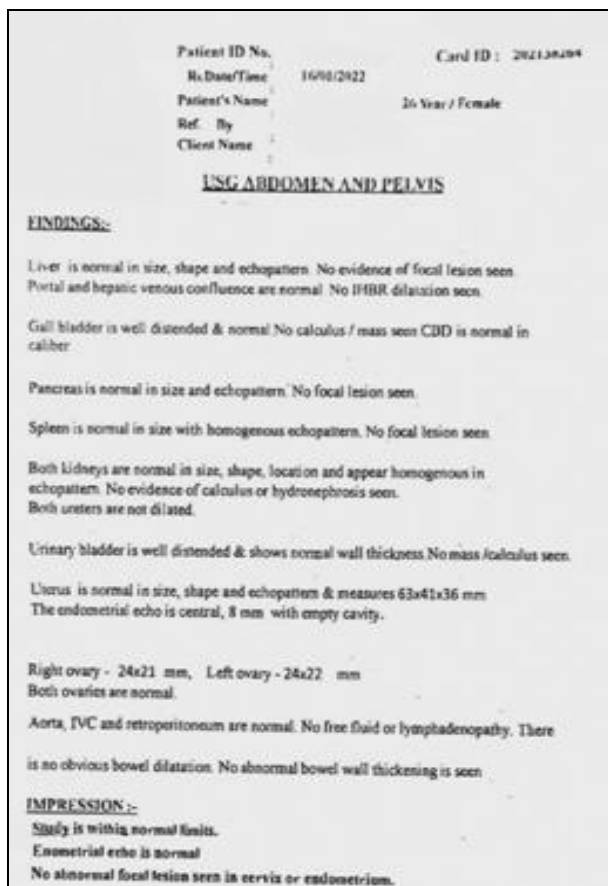


FIG. 2: ULTRASONOGRAPHY ABDO-PELVIS (AFTER TREATMENT)

**Therapeutic Intervention:**

**Totality of Symptoms:** The symptoms arrived in totality were as follows-

- Ailments from anger+++
- Irritable after coition++
- Irritable after menses ++
- Weeps when alone.
- Desire salty food.
- Sleepless till 2 am.
- White discharge acrid, excoriating.
- White discharge <after menses.
- Abnormal bleeding post-menses
- Profuse bleeding during menses<night.
- Pain during coition.
- Pulsating headache <before menses.

**MATERIALS AND METHODS:** Repertorisation – Repertorisation of the case was done by using Homopath Zomeo Basic Lan version 1.0 software, in which a complete repertory was used. Natrum Muriaticum scored the highest, scoring of 35 and covered all 13 symptoms.

Remedy	Nat-m	Sep	Calc	Sil	Phos	Puls	Nit-ac	Sulph	Chin	Lyc	Ferr	Cham	Merc	Carb-v	Mag-s
<b>Totality</b>	35	29	27	27	26	26	25	25	24	24	22	22	21	21	21
<b>Symptoms Covered</b>	13	8	8	8	8	7	8	7	8	7	8	6	8	7	7
[Complete] [Mind]Anger:Ailments from, agg:	4	4	4	4	4	4	3	4	3	4	3	4	1	3	3
[Complete] [Mind]Irritability:Coition:Agg:	3	4	4	4	3	0	1	0	3	0	0	0	0	0	0
[Complete] [Mind]Irritability:Menses:After:	1	0	0	0	0	0	0	0	0	0	1	0	0	0	0
[Complete] [Mind]Weeping, tearful mood:Alone, being:Agg:	3	0	0	0	0	0	0	0	0	3	0	0	0	0	0
[Complete] [Generalities]Food and drinks:Salt or salty food:Desires:	4	3	3	1	4	0	4	3	3	0	0	0	1	4	3
[Complete] [Sleep]Sleeplessness:Midnight:Before:Two am., urine:	1	0	1	3	1	3	0	0	0	0	0	3	3	0	0
[Complete] [Female Genitalia]Leucorrhoea:Acrid, corrosive, excoriating:	4	4	3	4	4	4	4	4	3	4	4	4	4	3	3
[Complete] [Female Genitalia]Leucorrhoea:Menses:After:	3	4	4	3	3	3	3	3	3	3	3	3	4	3	3
[Complete] [Female Genitalia]Hemorrhage, uterine, metrorrhagia:	4	4	4	4	4	4	4	4	4	4	4	4	4	4	3
[Complete] [Female Genitalia]Hemorrhage, uterine, metrorrhagia:Dark, black:	1	2	0	0	0	4	2	3	4	3	3	4	3	3	2
[Complete] [Female Genitalia]Menses:Profuse:Night:	1	0	0	0	0	0	0	0	0	0	1	0	0	0	4
[Complete] [Generalities]Pain:Coition, after:	3	4	4	4	3	4	4	4	1	3	3	0	1	1	0
[Complete] [Head]Pain, headache:Pulsating, throbbing:Menses:Before:	3	0	0	0	0	0	0	0	0	0	0	0	0	0	0

FIG. 3: REPERTORISATION TABLE: REPERTORISATION OF CASE USING HOMPATH ZOMEO SOFTWARE

**Prescription:** Natrum muriaticum 30C, twice a day (B.D.) was given for 5 days and Sac Lac thrice a day (T.D.S) for 15 days on Day 1 of the visit – 28/09/2021. The patient was asked to follow up after 15 days.

TABLE 1: REMEDY DIFFERENTIATION <sup>5,9,7</sup>

Natrum Muriaticum	Calcarea Carbonicum	Sepia
thermal – Hot patient	Thermal - Chilly patient	Thermal – Chilly patient
Ailments From: Disappointment, Grief, Anger, Fright, Profuse Menses	Ailments From: Alcohol, Mental Strain, Suppressed Sweat, Suppressed Eruptions.	Ailments From: Anger, Laundry Work, Getting Wet, Falls, Or Injury.

<p>Mental Symptom: Psychic causes of illness. Very Irritable and gets into a passion for trifles. Any idea in mind prevents sleep. Consolation aggravates. Wants sympathy but is worse from it</p> <p>Female Complaints: Menses profuse with dryness of genital region. White discharge which is acrid and irritating. Coition painful. Sensation of bearing down pain in the lower abdomen. Prolonged menses</p>	<p>Especially Diseases Arising From Mal-Assimilation</p> <p>Mental Symptom: Hardworking, over-working, over-responsible. Practical, down to earth. Timid restless with marked fear. Fear of impending diseases, poverty, insanity, and high places</p> <p>Female Complaints: Least mental exertion causes the profuse flow of blood. Milky white discharge. Menses are early and profuse</p>	<p>Mental Symptom: Weepy while narrating complaints. Indifferent to near ones. Aversion to family and work. Fear to stay alone</p> <p>Female Complaints: Yellow, green discharge from the vagina. Menses are late, scanty, and irregular. Bearing down with sensation as if everything would escape from the vulva</p>
---	--	--

**TABLE 2: FOLLOW-UP VISITS WITH DETAILED SYMPTOMS, USG REPORT, AND TREATMENT**

Date	Symptoms	Treatment
12/10/21 (1 <sup>st</sup> follow-up)	Abnormal bleeding in between menses++, White discharge ++ pain after coition ++ Headache worse on exertion++ Could sleep well. Mentals -Irritability 2+ L.M.P- 5/10/21Duration-6 days. Flow-Red in color with profuse intermittent clots. Quantity -3pads/day. No pain during menses	Sac Lacx TDS x15 days
28/10/21 (2 <sup>nd</sup> follow-up)	Abnormal bleeding < after coition -SQ. Pain after coition + Headache <on exertion+ Leucorrhea - White thick,acrid with burning in vulva++	Sac Lac x TDS x 15 days
15/11/21 (3 <sup>rd</sup> follow-up)	Intermenstrual bleeding + Headache better no pain for 1 week Mental Symptoms: Irritability + L.M.P-3/11/21 Duration-5 days Flow- Red in color with mild intermittent clots. Quantity - 2 pads/day. Noticed Eruption on the genital region before menses which she suffered previously. Leucorrhea -Scanty white with mild burning.	Natrum Muriaticum 200C x 1dose Sac Lacx BDx 15 days
30/11/21 (4 <sup>th</sup> follow-up)	Occasional Intermenstrual bleeding. Eruptions on and off. Leucorrhea - Scanty white discharge. Mentally she is better. Have started involving herself in her hobby of dancing.	Natrum muriaticum 1M x 1dose Sac Lac x BD x 15 days.
15/12/21 (5 <sup>th</sup> follow-up)	G.C. is much better.No new c/o. No intermenstrual spotting in between periods. L.M.P - 1/12/21 O/E B.P - 110/80mm Hg P/V - Polyp not felt.Discharge+	Sac Lac x BD x 30 days. Advise reviewUSG abdomen and pelvis.
20/01/22 (6 <sup>th</sup> follow-up)	No intermenstrual bleeding. No new complaints. L.M.P - 30/12/21 Mentally stable. USG abdomen and pelvis (16/01/22) - No significant abnormality seen. The endometrium is Normal with no focal lesion in the cervix.(Refer to FIG.:2)	Sac Lac x BD x 1 month
15/02/22 (7 <sup>th</sup> follow-up)	G.C. better. No new complaints. Mentally stable	Sac Lac x BD x 15 days F/uS. O. S

**TABLE 3: RESPONSE OF PATIENT ASSESSED WITH MODIFIED NARANJO CRITERIA (MAXIMUM SCORE= +13 AND MINIMUM SCORE= -6)<sup>2</sup>**

S. no.	Criteria	Yes	No	Not sure	Agreed Score
1	Was there any improvement seen in the patient signs and symptoms for which the homeopathic medicine was prescribed?	+2	-1	0	+2
2	Did the improvement occur within the time frame relative to drug intake	+1	-2	0	+1
3	Was there any initial aggravation seen?	+1	0	0	0
4	Was there any change in other symptoms except the main symptoms	+1	0	0	+1
5	Did overall well-being occur?	+1	0	0	+1
6	a) Did some symptoms improve in the opposite order of development of symptoms b) Did the symptom go from a more important organ to a less important organ	+1	0	0	0
7	Did old symptoms appear temporarily during course of improvement	+1	0	0	+1
8	Was there any alternative cause	-3	+1	0	+1
9	Was any objective evidence seen in the improvement	+2	0	0	+2
10	Did repeating dose gave same result	+1	0	0	+1
	Total				+11

**RESULT AND DISCUSSION:** The above case report demonstrates the effectiveness of individualized homeopathic medicine in the treatment of cervical polyps. The patient was advised for Polypectomy. The patient responded to a single homeopathic remedy effectively, and a permanent cure was achieved. Based on the chronic totality of symptoms, the patient was prescribed Natrum Muriaticum 30C. The remedies taken for differentiation were Sepia and Calcarea Carbonicum as seen in **Table 1**. In this case, the mental symptoms of the patient were much marked wherein Irritability after Menses and Weeping When Alone were covered only by Natrum Muriaticum. Also, sleeplessness, which was most marked in the patient, was not covered by Sepia and Calcarea Carbonicum.

In **Fig. 3** Natrum Muriaticum has covered all the symptoms and scored 35 marks. Other remedies were Sepia, which scored 29 marks and Calcarea Carbonicum, which scored 27 marks. Natrum Muriaticum was given as the constitutional remedy best suited to the patient's constitution. Natrum Muriaticum is indicated in cases of psychic causes of illness, where there are ill effects of anger. The first dose of Natrum Muriaticum. 30C showed improvement in the general aspect of the patient. She could sleep well, and her menses were less profuse than before. Sac lac was prescribed to the patient in 1st follow-up in order not to disturb the action of the medicine. In 2<sup>nd</sup> follow-up, pain after coition was much better, and no other significant changes were noted.

In 3<sup>rd</sup> and 4<sup>th</sup> follow-ups, the patient noticed old symptoms that appeared after taking medicine with occasional intermenstrual bleeding. According to the Principles of Homoeopathy, there was an appearance of old symptoms, meaning the remedy selected was correct<sup>6</sup>. Natrum Muriaticum was prescribed in the higher potencies, that is in 200 C potency, followed by 1M. Mentally, the patient was much better there was no irritability and the patient had started engaging herself in her hobby of dancing and other daily activities. In 5<sup>th</sup> follow-up, intermenstrual bleeding was better. No new eruptions on genitals since 15 days, no pain after coition. On 1<sup>st</sup> day of menses, there was heavy flow followed by normal flow for the rest four days. On examination, as the polyp was not felt, the patient

was advised to do repeat Ultrasonography. Results of post-treatment USG are mentioned in **Fig. 2** and **Table 2**. In 6<sup>th</sup> follow-up, the patient had no intermenstrual bleeding and so Sac lac was prescribed, and in 7<sup>th</sup> follow-up, the patient was asked to follow up when needed. **Table 3** consists of the Naranjo Criteria Score, which assessed the patient's response to treatment. There was a score of +11 which indicates good improvement in the patient, and no adverse effects were seen in the patient during treatment<sup>2</sup>. The consistent follow-up revealed that the patient had improved not only in the physical aspect but also in her mental symptoms. This itself shows the compatibility of single individualized medicines in treating such cases with no need for surgical interventions.

**CONCLUSION:** In the Homoeopathic system of medicine, only disease is not treated, but the patient is treated as a whole; both the patient's mental and physical aspects are considered. With this, I conclude that this case has shown how a holistic method of treatment has given encouraging results in treating cervical polyps, as evident in USG results. So with further research, homeopathy can be thought of as an alternative treatment in such cases.

**ACKNOWLEDGEMENT:** I am thankful to Dr. D. Y. Patil, Homeopathic Medical College, and Research Centre and faculties for guiding us and for the opportunity to conduct various research and publish articles in reputed Journals.

**Informed Consent:** Informed consent was taken from the patient on 1<sup>st</sup> visit.

**Source of Funding:** Nil

**CONFLICTS OF INTEREST:** No conflict of interest.

#### REFERENCES:

1. Alkilani YG and Apodaca-Ramos I: Cervical Polyps, Treasure Island (FL), Stat Pearls Publishing, 2022 Jan[Updated 2022 Sep5].
2. Lamba CD, Gupta VK and van Haselen R: Evaluation of the Modified Naranjo Criteria for Assessing Causal Attribution of Clinical Outcome to Homeopathic Intervention as Presented in Case Reports, Homeopathy. 2020; 109(4): 191-197
3. Pegu B, Srinivas BH, Saranya TS, Murugesan R, Priyadarshini Thippeswamy S and Gaur BPS: Cervical polyp: evaluating the need of routine surgical intervention and its correlation with cervical smear cytology and

- endometrial pathology: a retrospective study. *Obstet Gynecol Sci* 2020; 63(6): 735-742.
4. Girish Gupta, Richa Singh and Asha Rani: Role of Homoeopathy in case of Cervical Polyp, *Advancements in Homoeopathic Research* 2016; 1(2): 16-24.
  5. William Boreicke: *Pocket Manual of Homoeopathic Materia Medica & Repertory*, B. Jain Publishers Pvt. Ltd, 56th Impression 2016.
  6. Samuel Hahnemann, *Organon of Medicine*, Indian Books and Periodicals Publishers, Reprint Edition: September 2012.
  7. Kent JT: *Lectures on Homoeopathic Materia Medica*, Edition 2009 39th impression 2013; 311-328.
  8. Dutta DC: *Textbook of Gynaecology*, Jaypee Brothers Medical Publishers, Edition 2013; 286-287.
  9. Robin Murphy, *Lotus Materia Medica and Jain B: Publishers Pvt. Ltd.*, Indian edition 2010; 408-414, 1356-1363, 1764-1773.
  10. Stamatellos I, Stamatopoulos P and Bontis J: The role of hysteroscopy in the current management of the cervical polyps, *Arch Gynecology Obstet* 2007; 276(4): 299-303.
  11. Blackwood AL: *A Manual of Materia Medica, Therapeutics and Pharmacology with Clinical Index*, B. Jain Publishers Pvt. Ltd 465- 467

**How to cite this article:**

Kadam S, Lamba P, Sharma DB, Chaphekar PA and Aphale P: Cervical polyp treated with individualized homoeopathic medicine - case report. *Int J Pharm Sci & Res* 2023; 14(11): 5526-31. doi: 10.13040/IJPSR.0975-8232.14(11).5526-31.

All © 2023 are reserved by International Journal of Pharmaceutical Sciences and Research. This Journal licensed under a Creative Commons Attribution-NonCommercial-ShareAlike 3.0 Unported License.

This article can be downloaded to **Android OS** based mobile. Scan QR Code using Code/Bar Scanner from your mobile. (Scanners are available on Google Playstore)