



Received on 24 April, 2012; received in revised form 14 May, 2012; accepted 21 July, 2012

THE EFFECT OF ASPIRIN ON REPRODUCTIVE ORGANS OF FEMALE ALBINO RAT

Neha Jain, Renu Shrivastava, Arun K. Raghuwanshi and Vinoy K. Shrivastava*

Laboratory of Endocrinology, Department of Biosciences, Barkatullah University, Bhopal- 462026, Madhya Pradesh, India

ABSTRACT

Keywords:

Aspirin (acetylsalicylic acid, ASA),
Enzymological estimations,
Histopathological variations,
Rattus norvegicus

The aim of present investigation is to study the effect of oral administration of drug acetylsalicylic acid (ASA, aspirin) on female albino rat, *Rattus norvegicus*. The female rats (n=24) were allocated into 2 groups as control (n=12) and treated (n=12). The treated rats were given oral dose of aspirin 100 mg/ kg body weight for 15 days (n=6) and 30 days (n=6). Tissues enzymological estimations such as ACP (Acid Phosphatase) and ALP (Alkaline Phosphatase) along with histopathological studies of reproductive organs (ovary and uterus) were done. The present investigation indicated that, aspirin significantly increased ACP and ALP content in reproductive tissues and also caused significant histopathological variations in reproductive organs such as ovary and uterus by modulating certain enzyme metabolism in female albino rats.

Correspondence to Author:

Prof. Vinoy K. Shrivastava

Dr. Zoology, Endocrinology Unit,
Department of Biosciences, Barkatullah
University, Bhopal-462026, Madhya
Pradesh, India

E mail: vinoyks2001@yahoo.com

INTRODUCTION: Aspirin (acetylsalicylic acid, ASA) has been used as one of the most famous, cheap, easily available and widely used Non Steroidal Anti Inflammatory Drug (NSAID). Aspirin is used in versatile purpose such as, anti-inflammatory (in joint diseases), anti-platelets (in cardiovascular disease), analgesic and antipyretic ¹.

Salicylic acid is metabolized via conjugation in the liver to form salicyluric acid and several other metabolites. It is also well known that, aspirin is rapidly absorbed from the stomach and small intestine, primarily by passive diffusion across the gastrointestinal (GI) tract which rapidly hydrolyzed to salicylic acid by esterase in the GI mucosa and blood plasma. It dispersed throughout the body after ingestion, with the highest concentrations found in the blood plasma, liver, renal cortex, heart and lungs ². Aspirin is a safe drug at low doses but also it has life-threatening side effects when administered at high doses.

Long-term therapeutic administration of aspirin is associated with nephrotoxicity, hepatotoxicity, gastrointestinal ulcerations, and even renal cell cancer due to its adverse effects on multiple organ systems ^{3, 4}. Aspirin can cause adverse affects in pregnancy ⁵.

In-vitro and *in-vivo* studies show that aspirin at high doses caused death of the blood vessel tissues ⁶. Aspirin inhibits continuous production of prostaglandin which causes unopposed constriction of arterioles resulting ischemia of tubules and cause epithelial cell death ⁷.

The inhibitory activity of aspirin also found on the endocrine hormones *viz.* ACTH, endorphin, cortisol, prolactin and growth hormone via possible stimulatory role of prostaglandin. Also, overdose of aspirin stimulate corticosteroid secretion by the adrenal cortex ⁴.

Aim of the work: The present work was planned to demonstrate side effects of the anti-inflammatory drug aspirin (100 mg/ kg body weight) on reproductive organs (ovary and uterus) of young albino female rats, *Rattus norvegicus*, with respect to histopathological studies of reproductive organs and enzymological studies by ACP (Acid Phosphatase) and ALP (Alkaline Phosphatase) estimation in reproductive tissue homogenate after 15 and 30 days treatments.

MATERIALS AND METHODS:

Material: Aspirin (acetylsalicylic acid) tablets (75 mg/tablet) as anti-inflammatory drug was purchased from the market, trade name Ecospirin-75 (manufactured by USV LTD, B.S.D. Marg, Govandi, Mumbai-400088) which were powdered gently.

Experimental animals: The above study was carried out on 24 adult female albino rats (body weight ranging between 150-200 gm) were taken from the animal house of Barkatullah University, Bhopal, India. The study was conducted in accordance with Ethical Commission on Animal Research of Barkatullah University. Year of experimentation were October-2010 to March-2011 and experimentation site were Laboratory of Endocrinology, Department of Biosciences, Barkatullah University, Bhopal.

The animals were kept into polypropylene cages and acclimatized to laboratory condition *i.e.* 23-25°C temperature with 14 hours light and 10 hours dark cycle at least for 7 days prior to initiating to the experiment. The animals were fed with standard rat feed and water *ad libitum*. A dose of aspirin (100mg/kg b. wt.) was daily administered orally, through gavage (administration of food or drugs by force, especially to an animal) for 15 and 30 days. The animals were divided into 3 groups as control (n=12) and treated (n=12).

- **Group 1:** Fed with normal diet and water *ad libitum* served as control.
- **Group 2:** Fed with normal diet and given aspirin orally (100mg/kg b. wt.) through gavage for 15 days.

- **Group 3:** Fed with normal diet and given aspirin orally (100mg/kg b. wt.) through gavage for 30 days.

After above treatments, the animals were weighed, sacrificed on 16th and 31st day and for enzymological analysis tissue homogenate of reproductive organs (ovary and uterus) were prepared and for histological study ovary and uterus were dissected out quickly, cleaned, dried with blotting paper and subsequently fixed in Bouin's fluid. Therefore, following parameters were done by appropriate methods.

Parameters estimated:

Tissues Enzymological Study: King and Kings Method was used for the determination of tissue homogenate Acid Phosphatase (ACP) and serum Alkaline Phosphatase (ALP) ⁸.

Histopathological study: For histopathological study of ovary and uterus classical paraffin sectioning (7μ thick) and Haematoxylin and Eosin staining method were applied to stain them and these were evaluated by light microscopy ⁹.

Statistical analysis: Standard error of mean (SEM) were calculated and p value of treated batches were estimated by correlating them with control batch. Student't'-test described between the mean values obtained ¹⁰.

RESULT AND DISCUSSION: The present study indicated that, aspirin (100mg/Kg b.w.) significantly increased ACP and ALP content in reproductive tissues of 15 and 30 days treated rats (**Table 1**). Authors also suggest that, aspirin elevates cell membrane associated phosphatase enzymes (ACP and ALP) of tissues which indicating pathological destructive process because these enzymes are involved in maintenance of the amino acid homeostasis ^{11,12}.

Our present findings showed that, the histopathological changes in both ovaries and uterus (**Fig. 1-6**) of treated rats may be due to the vascular properties of aspirin as well as it induced vasoconstriction and smooth muscle atrophy via inhibition of the synthesis of different prostaglandin *viz.* PGE2, PGD2, PGF2 and PGI2 which are potent vasodilators ^{1,13}.

Apart from this, aspirin (100mg/kg b.wt.) caused the structural ovarian changes such as highly atrophy, degeneration, vacuolization with less cytoplasmic material and reduced nuclei of cells (such as follicular cells, granulosa cells, thecal and stromal cells) of ovarian follicles. As well as, corpus luteum is clearly visible with hypertrophied cells and interstitial tissues are also atrophied in condition and showing areas of vasoconstriction (Fig. 2, 3).

Author suggests that, aspirin administration persistently arrest luteolysis and enhance the growth of intact and functional corpora lutea due to prolongation of the diestrous phase and delayed luteolysis via inhibition of prostaglandin F_{2α} by high level of progesterone hormone¹. Moreover, prolonged treatment of aspirin significant decrease in the number of growing follicles with complete absence of graffian follicles and significant increase in the number of

corpora lutea, diameter of the granulosa lutein cells and absence of regressed corpora luteal might be due to the strong anti-inflammatory effect of progesterone hormone which secreted by the active corpora lutea via suppression of the FSH and LH hormones^{14, 15}.

Also, aspirin (100mg/kg b.wt.) caused the structural uterine changes such as showing areas of vasoconstriction, smooth muscle atrophy, vacuolization, degenerative and atrophic changes in endometrium, myometrium and serosa, and degenerative epithelial layer of lumen in 15 and 30 days treated rat (Fig. 5, 6). Author suggests that, prolonged treatment of aspirin significant decrease endometrial lining cell height, endometrial thickness, diameter of endometrial glands, causes hemorrhagic spots at the site of uterine wall, vascularization and blood vessels weakness^{14, 15}.

TABLE 1: EFFECT OF ASPIRIN ON ENZYME CONSTITUENTS OF REPRODUCTIVE SYSTEM OF FEMALE ALBINO RAT

Parameters (mg/dl)	Control	15 days treated group	30 days treated group
ACP	7.93± 0.63	24.68± 0.53**	45.79± 0.38***
ALP	42.29 ± 0.63	59.94± 0.45***	86.76± 0.33***

Values are mean ± SEM, (n = 6), ***p< 0.001(Highly significant)

EXPLANATION OF FIGURES OF OVARY AND UTERUS

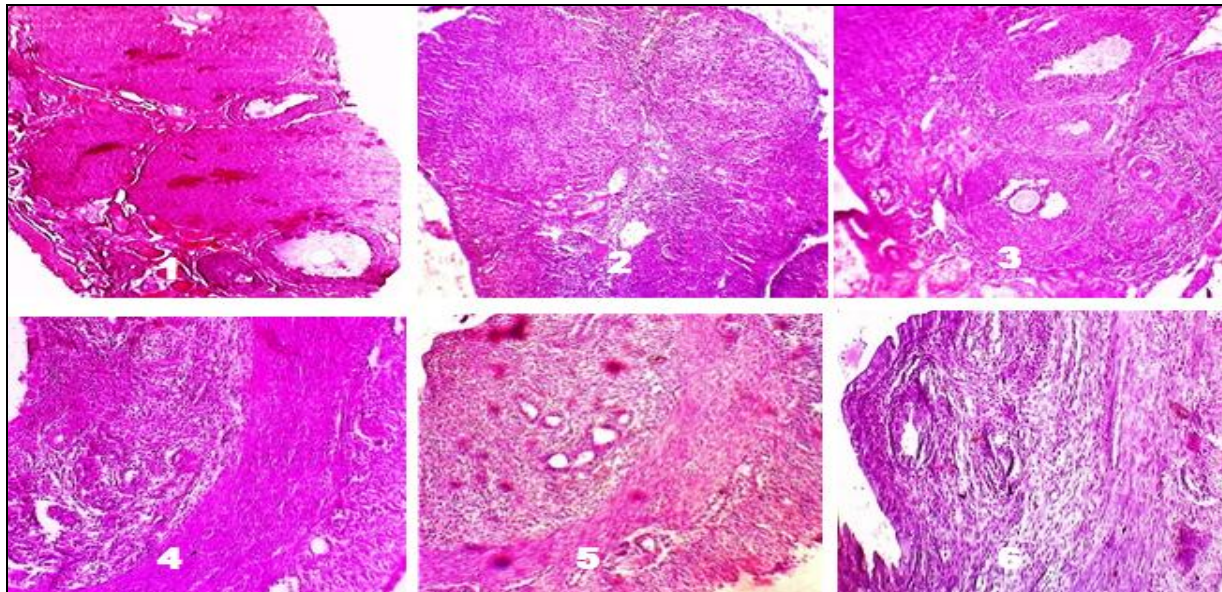


Fig. 1: Section of ovary of control *Rattus norvegicus* showing normal histo-architecture with well organized surface epithelium and different follicle : viz. primary, secondary, developing and mature graffian follicles. Stromal cells of ovarian follicles and corpus luteum are also well developed (H & E 100X).

Fig 2: Section of 15 days aspirin treated (100 mg/kg) ovary of *Rattus norvegicus* showing normal histo-architecture of ovary but hypertrophied cells found in corpus luteum. The interstitial tissues are also atrophied in condition and showing areas of vasoconstriction (H & E 100X).

Fig 3: Section of 30 days aspirin treated (100 mg/kg) ovary of *Rattus norvegicus* showing highly atrophic, degenerative, vacuolated changes with less cytoplasmic material, reduced nuclei of follicular cells, granulosa cells, thecal and stromal cells of ovarian follicles (H & E 100X).

Fig 4: Section of control uterus of *Rattus norvegicus* showing well organized outer layer of serosa, middle layer of myometrium with muscle layers and inner layer of endometrium with uterine gland. Endometrium is lined by simple columnar epithelium. Lumen is also well developed (H & E 40X).

Fig 5: Section of 15 days aspirin treated (100 mg/kg) uterus of *Rattus norvegicus* showing areas of vasoconstriction, smooth muscle atrophy, vacuolated endometrium with slightly degenerated epithelial cells and myometrium is atrophied with degenerative changes (H & E 100X).

Fig 6: Section of 30 days aspirin treated (100 mg/kg) uterus of *Rattus norvegicus* showing areas of vasoconstriction, smooth muscle atrophy and degenerative epithelial layer of lumen. Vacuolization, fibrosed, degenerative and atrophic changes found in endometrium, myometrium and serosa (H & E 100X).

CONCLUSION & SUMMARY: Finally, it may be concluded that aspirin at the dose of 100mg/kg b.wt. significantly caused histomorphological variations in reproductive organs such as ovary and uterus and increasing ACP and ALP content in reproductive tissues of young albino female rats, *Rattus norvegicus*. If it is taken continuously by patients; they may suffer from reproductive problems.

ACKNOWLEDGEMENTS: We express our sincere thanks and gratitude to Prof. VK Shrivastava, HOD, Bioscience Department Barkatullah University, Bhopal, Madhya Pradesh, India, for providing departmental infrastructural facilities.

REFERENCES:

1. Adnan S, Janabi AI, Ahmad M, Izohyri A, Fouad K and Rubayai: Pharmacological effects of low- dose of aspirin on corpus luteum functions in mature cycling female mice. *Institute of the Embryo Research and Infertility Treatment* 2005; 10 (suppl 2): 150-162.
2. Marcia LB: Use of Aspirin in Children with Cardiac Disease. *Pediatric Pharmacotherapy* 2007; 13 (suppl 2).
3. Gilman EA, Langman MJ, Cheng KK and Lancashire RJ: Effect of anti-inflammatory drugs on overall risk of common cancer: case-control study in general practice research database. *BMJ* 2000; 320: 1642-1646.
4. Luigi DL, Laura G, Francesco R, Carlo B, and Domenico C: Aspirin, exercise and pituitary hormones. *Official Journal of the American College of Sports Medicine* 2001; 2029-2035.
5. Collins E and Turner G: Maternal Fetal effects of regular salicylate ingestion during pregnancy. *Lancet* 1975; 2: 335-339.
6. Starke RD, Smith SC, Blair SN, Bonow RO, Brass LM *et al*: AHA/ACC guidelines for preventing heart attack and death in patients with atherosclerotic cardiovascular disease. *The American College of Cardiology* 2001; 104: 1577-9.
7. Talat Y, Farzana Y and Ghulam SQ: To evaluate the role of diclofenac sodium (a NSAID) on renal parenchyma of young albino rats. *Pak J Pharm Sci* 2008; 21(suppl 2): 98-102.
8. King PRN, King EJ: Colorimetric method for the determination of serum/ tissue homogenate Alkaline Phosphatase and Serum/ tissue homogenate Alkaline Phosphatase. *J Clin Path* 1954; 7: 132-136.
9. Durury RAB and Wallington EA: Histological technique. *Oxford Uni Press*, Fifth Edition 1980.
10. Fisher RA and Yates: Statistical tables for biological, agricultural and medical research. 1948; 3rd ed. 26-27.
11. Sherifa KA: Hepatic and renal biochemical responses to the toxicological interaction between acetylsalicylic acid and diazinon in albino Rats. *J Egypt Soc Toxicol* 2006; Vol.35, 1-6.
12. Kawar ME and Reham EM: Salicylate hepato-toxicity in a patient with systemic lupus erythematosus: a case report. *JRMS* 2010; 17 (suppl 1): 43-45.
13. Vane JR: Inhibition of prostaglandin synthesis as a mechanism of action of aspirin-like drugs. *Nat New Biol* 1971; 231: 232-235.
14. Tibbotts TA, Couneely OMO, Malley BW: Progesterone via its receptors antagonizes the pro-inflammatory activity of estrogen in the mouse uterus. *Biol Reprod* 1999; 65(suppl 5):1158- 65.
15. Schafer AI: Effects of non steroidal anti-inflammatory drugs on platelet function & systemic hemostasis. *J Clin Pharmacol* 1995; 35(suppl 3): 209-19.

How to cite this article:

Jain N, Shrivastava R, Raghuvanshi AK and Shrivastava VK. The Effect of Aspirin on Reproductive Organs of Female Albino Rat. *Int J Pharm Sci Res* 2012; Vol. 3(8): 2644-2647.