



Received on 03 February, 2015; received in revised form, 09 July, 2015; accepted, 30 July, 2015; published 01 September, 2015

EFFECT OF *CICHORIUM INTYBUS* LEAVES ON N- NITROSODIETHYLAMINE INDUCED HEPATOTOXICITY IN WISTAR RATS

Neha Mathur ¹, Vidhu Aeri ^{*2} and Deepshikha Pande Katare ^{*3}

Amity Institute of Pharmacy ¹, Amity University Uttar Pradesh, Lucknow, India.

Department of Pharmacognosy & Phytochemistry ², Faculty of Pharmacy, Jamia Hamdard University, New Delhi, India.

Amity Institute of Biotechnology ³, Amity University Uttar Pradesh, Noida, India.

Keywords:

Kasni, DEN, Diethylnitrosoamine, Carcinogen, Hepatoprotective, Antihepatotoxic

Correspondence to Author: Deepshikha Pandey Katare

Professor, Amity Institute of Biotechnology, J- III Block, Amity University Uttar Pradesh, Sector 125, Noida-201303, India.

E-mail: dpkatare@amity.edu

ABSTRACT: *Cichorium intybus* (Asteraceae) is used as traditional medicine in India for various liver related disorders. The present study evaluates the hepatoprotective potential of leaf extract on N- nitrosodiethylamine induced hepatotoxicity, which is commonly present in foods, beverages, tobacco smoke, herbicides, pesticides, drinking water, and industrial pollution. The leaves were sorted as per their size (short, medium, large) and subjected to extraction with ethanol, water and ethanol: water (1:1 w/w) by cold maceration and hot soxlation. The extract having the highest extractive value 80.7%w/w was selected for animal studies. Group I, II, III, served as control, toxic and standard. Group IV and V were post treatment receiving 400 mg/kg body weight and 800 mg/kg body weight respectively and group VI as pre treatment group receiving 800 mg/kg body weight of the extract before the induction of toxicity. The level of serum markers such as aspartate aminotransferase (AST), alanine aminotransferase (ALT), alkaline phosphatase (ALP) were significantly suppressed ($P < 0.0001$) in both the groups receiving 400 mg/kg body weight and 800 mg/kg body weight of extract as compared to the toxic group. Activities of enzymic (superoxide dismutase (SOD), catalase (CAT), glutathione peroxidase (GPx), glutathione-S-transferase (GST), and glutathione reductase (GR)) antioxidants were significantly increased ($P < 0.05$) on supplementation with the extract. Histopathological studies also evidenced the liver protective effect of the plant extract. The study results show that treatment with 800 mg/kg body weight *Cichorium intybus* extract before or after NDEA provides protection against the hepatotoxicity caused by NDEA.

INTRODUCTION: Liver disease is currently one of the major health problems worldwide. According to the report of World Health Organization 75 % of the world population relies on the traditional medicines of plant origin¹. Liver is the major site of metabolic activities. The detoxification of harmful chemicals occurs in the liver which in turn results in various hepatic diseases.

The general population may possibly be exposed to unknown quantities of N- nitrosodiethylamine (NDEA) present in foods, beverages, tobacco smoke, herbicides, pesticides, drinking water and industrial pollution. N-Nitrosodiethylamine is present in a variety of foods, including cheese at concentrations of 0.5 to 30 $\mu\text{g}/\text{kg}$, soybeans at 0.2 $\mu\text{g}/\text{kg}$, soybean oil at 4 $\mu\text{g}/\text{kg}$, various fish at 1 to 147 $\mu\text{g}/\text{kg}$, salt-dried fish at 1.2 to 21 mg/kg, cured meats at up to 40 $\mu\text{g}/\text{kg}$, and alcoholic beverages at 0.1 $\mu\text{g}/\text{kg}$ ².

N-Nitrosodiethylamine has been detected in tobacco smoke condensate at concentrations of 1.0 to 28 ng/cigarette. Upto 8.3 ng/cigarette were found in mainstream smoke and 8 to 73 ng/cigarette were

<p>QUICK RESPONSE CODE</p>	<p>DOI: 10.13040/IJPSR.0975-8232.6(9).3861-71</p> <p>Article can be accessed online on: www.ijpsr.com</p>
<p>DOI link: http://dx.doi.org/10.13040/IJPSR.0975-8232.6(9).3861-71</p>	

found in sidestream smoke. An analysis of indoor air polluted with tobacco smoke indicated levels of up to 0.2 ng/L of *N*-nitrosodiethylamine³. The compound has also been found at a concentration of 10 ng/m³ in the smoking compartment of a train⁴.

Many Indian ancient medicinal texts emphasize on the hepatoprotective capacity of certain plants⁵ such as kalmegh (*Andrographis paniculata*), bhuia amla (*Phyllanthus niruri*), indian bearberry (*Berberis aristata*), turmeric (*Curcuma longa*), kutki (*Picrorhiza kurroa*), mulethi (*Glycyrrhiza glabra*), punarnava (*Boerhavia diffusa*), tulsi (*Ocimum sanctum*), bhunga Raja (*Eclipta alba*), kanak champa (*Pterospermum acerifolium*), guduchi (*Tinispora cordifolia*), chirayata (*Swertia chirata*) besides chicory (*Cichorium intybus*). To validate the same various pharmacological and biological studies were previously performed on *Cichorium intybus* different plant parts like seeds, roots, leaves, stem etc.

For example (a) the alcoholic extract of seeds at the dose of 69.6 mg/kg bodyweight demonstrated hepatoprotective effect in chlorpromazine-induced hepatic damage in rats⁶, (b) it is one of the herbal components of Liv-52, a traditional Indian tonic used widely for hepatoprotection. In a randomized, double blind clinical trial conducted on cirrhotic patients, Liv-52 medication reduced the serum levels of hepatic enzymes, namely alanine amino transferase and aspartate amino transferase⁷, (c) another polyherbal formulation jigrine, contains the leaves of *C. intybus* as one of the 14 constituents. Jigrine was evaluated for its hepatoprotective activity against galactosamine induced hepatopathy in rats. The pretreatment of male Wistar albino rats with jigrine, significantly reduced the levels of alanine amino transferase and aspartate amino transferase, and urea and increased the levels of blood and tissue glutathione. Histopathological examination of the liver revealed that the jigrine pretreatment prevented galactosamine toxicity and caused a marked decrease in inflamed cells⁸.

The effect of *N*-nitroso compound was analyzed and it was found to cause breaking in the DNA strand of liver cells and also several enzymatic changes which induces hepatocellular carcinoma in

experimental animals^{9, 10}. Oxidative stress is considered as critical mechanism contributing to NDEA-induced hepatotoxicity and so the use of antioxidants reduces liver damage¹¹. NDEA is used either alone or in combination with other carcinogens like 2-acetylaminofluorene (2-AAF), phenobarbital benzopyrene, orotic acid, *N*-amyl-*N*-methylnitrosoamine and carbon tetrachloride^{12, 13}.

To get an insight into the progression of the disease, hepatotoxicity can be assessed at three levels (i) alanine amino transferase (ALT) that is glutamyl oxaloacetic acid transaminase level which increases three fold in the serum. (ii) serum alkaline phosphates (ALP) level increases two fold and (iii) serum bilirubin (SBLN) level elevated two fold¹⁴.

Researchers have investigated plant's seed extract against acetaminophen and carbon tetrachloride-induced liver damage in mice¹⁵. In analogous studies, the antihepatotoxic activity of the alcoholic extract of the seeds and aqueous extracts of the roots and root callus of *C. intybus* was estimated. The oral administration of these extracts in albino rats led to a marked decrease in the levels of hepatic enzymes. Also, histopathological examination of the liver showed no fat accumulation or necrosis after the treatment^{16, 17}. The carbon tetrachloride and paracetamol-induced liver toxicities were also found to be counteracted by intraperitoneal administration of crude extracts and fractions of *C. intybus*. In the same study, toxicity was induced in rat hepatocytes by incubation with galactosamine and thioacetamide¹⁸.

The hepatoprotective activity of *C. intybus* has been correlated to its ability to inhibit the free radical mediated damage. A fraction prepared from the ethanolic extract of the leaves was assessed for preventive action on the free radical mediated damage to the deoxyribose sugar of the DNA (obtained from calf thymus) when a dose dependent decrease in the DNA damage was observed^{19, 20}.

In the present paper we tried to evaluate and validate the hepatoprotective effects of *Cichorium intybus* leaves on the basis of its size on NDEA induced toxicity in male wistar rats, so that in

future an effective formulation could be developed with reduced dose which will be specific for imparting hepatoprotection during such toxicities.

MATERIALS AND METHODS:

Collection of Plant Material:

The seeds of *Cichorium intybus* were procured from khari bawli market, Delhi, India and was sown in the botanical garden Hamdard university, New Delhi. The leaves were collected and segregated as per three sizes viz. short, medium, long. They were identified by the head, raw materials herbarium and museum, NISCAIR, New Delhi and a voucher specimen number NISCAIR/RHMD/Consult/-2010-11/1603/201 was deposited at the herbarium of national institute of science communication and information resources, New Delhi.

Animals:

Male wistar rats (130±10 g, 4–6-week old) were obtained from central animal house of hamdard university, New Delhi. They were housed in polypropylene cages in groups of six rats per cage and kept in a room maintained at 25±2°C with a 12-h light/dark cycle. They were allowed to acclimatize for 1 week before the experiments and were given free access to standard laboratory feed (amrut laboratory, rat and mice feed, navmaharashtra chakan oil mills ltd., pune, India) and water *ad libitum*. Animal experimentation approval was granted from the Institutional animal ethics committee registered under the Committee for the Purpose of Control and Supervision of Experimental Animals (173/CPCSEA)

Chemicals and reagents:

DEN and 2-AAF were purchased from sigma chemical company, USA, silymarin was purchased from Micro Labs, all other chemicals and reagents were of analytical grade, supplied by s.merck (India).

Preparation of Leave extract:

The leaves were collected from the herbal garden in the month of January and were segregated as per three sizes viz short (5 mm), medium (5-7 mm) and large (7 mm & above). They were washed with distilled water and dried away from direct light, and then powdered. The powder was kept in three

different closed container at 4°C. The powdered material (500 g) was extracted three times in three different solvents viz. water, ethanol, water-ethanol(1:1,v/v) by two methods viz hot soxlation and by cold maceration, the cold extracts were vacuum dried while the hot extracts were concentrated under reduced pressure. The dried extract was then suspended in three solvents mentioned above and the volume adjusted to 500 ml. (1 g plant powder per ml). All the eighteen concentrated extract was divided in 25 ml aliquots, labeled properly and kept at -20 °C for further investigation.

Preliminary Phytochemical Screening of the extract:

Preliminary phytochemical screening of all the eighteen extracts of *Cichorium intybus* leaves were performed to detect the presence of saponins, sterol, triterpines, alkaloids, coumarins, and Flavonoids. Phenolic acids tests were carried by various chemical tests as mentioned in I.P (1966) and by thin layer chromatography²¹. Determination of total Flavonoid content²² was performed in the three extracts whose extractive values was found to be highest, amongst the eighteen extracts from the three sized leaves viz short , medium and large as prepared above.

Animal Study Protocol:

Rats were randomly divided into six groups with six animals in each group. The extract having the highest extractive value was codified as 'NCP 72' for use in animal studies. The experimental design and treatment protocol were as follows:

Group I (Normal Control):

Orally administered only CMC 1% solution

Group II (Toxic Control):

Received i.p.100 mg/kg body weight NDEA

Group III (Standard Control):

Received a single dose of NDEA (100 mg/kg body weight, i.p.) followed by orally administered silymarin (25 mg/kg body weight for 10 days) Received a single dose of NDEA (100 mg/kg body weight, i.p.) followed by orally administered plant extract 'NCP72' (400 mg/kg body weight for 10 days)

Group V (800 mg/kg Post Treatment)

Received a single dose of NDEA (100 mg/kg body weight, i.p.) followed by orally administered plant extract 'NCP72' (800 mg/kg body weight for 10 days)

Group VI (800 mg/kg Pre Treatment)

Orally administered plant extract 'NCP72' (800 mg/kg body weight for 10 days) followed by a single dose of NDEA (100 mg/kg body weight, i.p.) Rats were then sacrificed by cervical decapitation at the end of treatment and blood samples were collected. Serum was then separated by centrifugation at 1,200×g for 10 min and stored at –80°C for 12 hrs before analysis. Liver was removed and washed in ice cold normal saline and divided into 2 pieces; one piece is stored in 10% formalin solution at room temperature for histopathological analysis and second is preserved in 0.1N phosphate buffer, pH 7.4 at -70°C for biochemical studies. Liver homogenate was made in ice cold 0.15 M KCl solution using motor driven teflon pestle. The supernatant was further centrifuged at 10,000×g for 20 min at 4°C to get the post-mitochondrial supernatant (PMS), which was used for various biochemical assays.

Biochemical estimations:**Assay for serum AST and ALT activity:**

The serum enzymes were assayed using diagnostic kits provided by Span, and the AST and ALT activity was determined²³.

Assay for alkaline phosphatase activity:

Alkaline phosphatase (ALP) activity was determined²⁴ using the Span diagnostic kit.

Liver TBARS and Protein estimation:

TBARS was used as a measure of lipid peroxidation and measured by the modified method²⁵. Total protein in the tissue homogenate was also estimated²⁶. The levels of TBARS were expressed as nmol MDA/mg protein.

Determination of reduced glutathione:

Blood and liver glutathione were estimated by 5, 5-dithiobis-2-nitrobenzoic acid (DTNB)²⁷ and expressed as mg% and μmol/g of protein respectively.

Assay for catalase:

Catalase (CAT) activity was analyzed²⁸. The assay mixture consisted of 0.05 M phosphate buffer (pH 7.0), 0.019 M hydrogen peroxide (H₂O₂) and 0.05 ml PMS in a total volume of 3.0 ml. Changes in absorbance were recorded at 240 nm. CAT activity was expressed as nanomoles H₂O₂ consumed per minute per milligram protein.

Assay for superoxide dismutase:

Superoxide dismutase (SOD) activity was measured²⁹ with some modifications. The reaction mixture contained 0.8 ml of 50 mmol/l glycine buffer (pH 10.4), and 0.2 ml PMS. The reaction was initiated by the addition of 0.02 ml of a 20mg/ml solution of (-) epinephrine. Absorbance was recorded at 480 nm in a spectrophotometer. SOD activity was expressed as nanomoles of (-) epinephrine protected from oxidation by the sample as compared with the corresponding readings in the blank cuvette. The molar extinction coefficient of 4.02×10³ M⁻¹ cm⁻¹ was used for calculations.

Histological studies:

Liver sections from various groups were stained with haematoxylin and eosin and were preserved in buffered formalin (10%). Histological liver sections were prepared as described by³⁰.

Data Analysis:

Results are expressed as mean ± SEM. Statistical analysis of the data was obtained via analysis of variance, followed by Turkey's test. P<0.05 was considered statistically significant.

RESULTS:**Extractive values:****TABLE 1: EXTRACTIVE VALUES (%w/w) OF CICHORIUM INTYBUS LEAVES**

	Water	Ethanol-water	Ethanol
	Short leaves		
Hot	17.54	44.45	64.32
Cold	15.34	27.91	48.35
	Medium leaves		
Hot	66.71	80.7	71.83
Cold	35.02	49.81	65.16

Large leaves			
Hot	58.15	62.32	68.56
Cold	48.32	52.35	60.21

The extract prepared from medium sized leaves by hot soxlation yielded highest extractive value 80.7%w/w and so was chosen for administration to rats for animal studies. It was codified as ‘NCP 72’. Total flavonoid content in 1mg/ml sample of the extract ‘NCP 72’ was found to be 39.2 mg of Quercetin equivalent/gm of extract.³¹ (Mathur et al., 2014)

Morphological Changes:

Body weights of control group rats were slightly higher than those in NDEA-treated group. Body weight of the groups, control, NDEA-treated and protected was measured weekly to assess the effect of NDEA & efficacy of plant extract NCP72 against NDEA on general metabolism of experimental animals.

Usually NDEA administration causes weight loss in rats but in rats it was observed that although the body weight increased in all the groups, but the increase in weight in NDEA treated group was slow as compared to the control & protected, who gained their body weight throughout 3 weeks time (Fig. 1). At the start of experiment it was seen that the body weight was 140g and 150g for control and treated respectively. Within the course of experiment the body weight of control increased to 190 g and that of treated was 170 g.

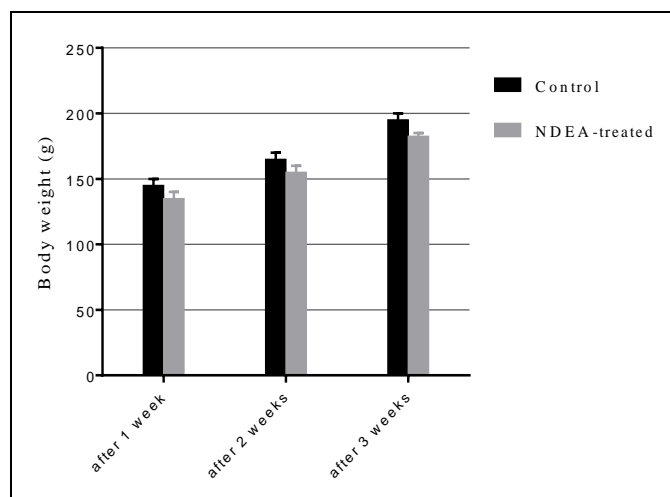


FIG. 1: EFFECT OF CHANGE IN THE BODY WEIGHT (g) OF MALE WISTAR RATS AFTER INTOXICATION WITH NDEA AT DIFFERENT TIME INTERVALS.

Biochemical parameters:

Rats treated with NDEA showed significant hepatic damage as observed from increase in serum enzymes (SGOT, SGPT, and ALP) and lipid peroxidation Fig.3–5 and glutathione reductase, SOD and catalase Fig. 6-8. However, pretreatment of rats with NCP72 extract (800mg/kg dose) followed by NDEA, afforded protection by lowering the serum enzymes. In addition, pretreatment of extract normalized the level of antioxidant enzymes Fig. 6-8. Protection was observed maximally with the highest dose of the extract.

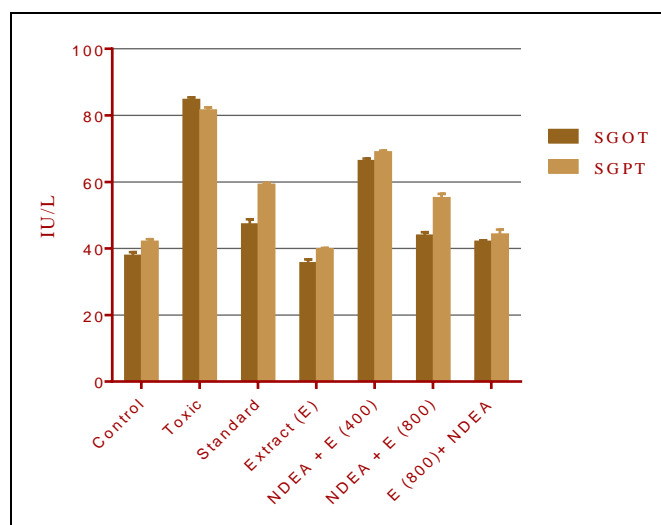


FIG. 2: SERUM SGPT/SGOT LEVEL IN DIFFERENT ANIMAL MODEL GROUPS.

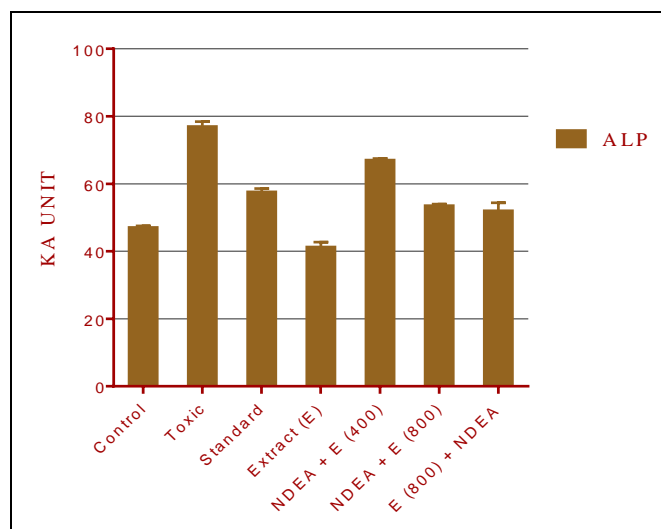


FIG. 3: SERUM ALP (ALKALINE PHOSPHATASE) LEVEL IN DIFFERENT ANIMAL MODEL GROUPS.

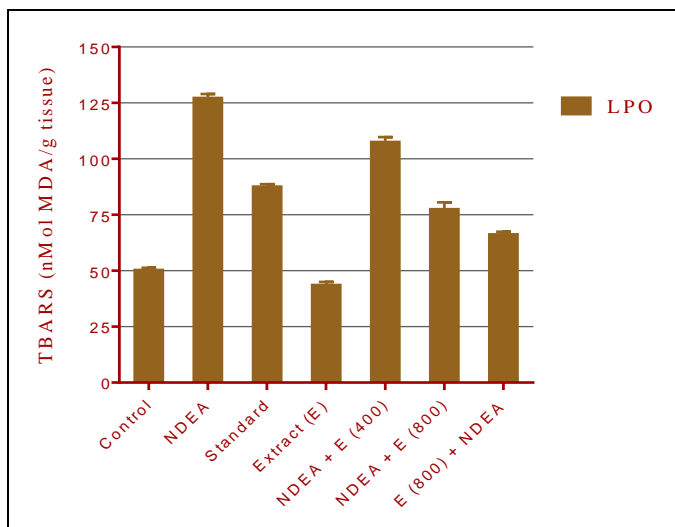


FIG.4: LIPID PEROXIDATION (TBARS) ESTIMATION IN DIFFERENT ANIMAL GROUPS.

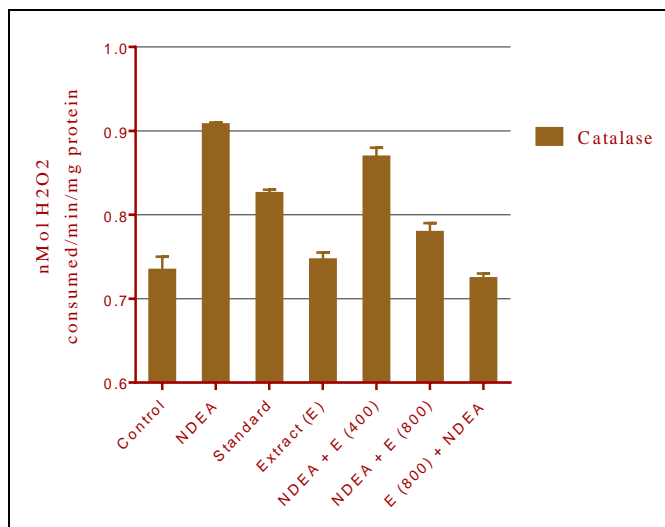


FIG. 7: CATALASE ACTIVITY (nMol H₂O₂ CONSUMED/min/mg PROTEIN) IN DIFFERENT ANIMAL MODEL GROUPS.

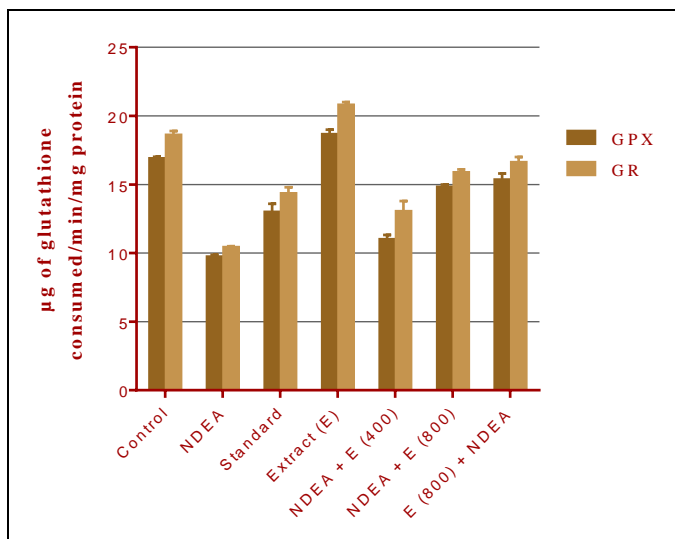


FIG.5: GLUTATHIONE PEROXIDASE (GPx) & GLUTATHIONE REDUCTASE (GR) LEVELS IN DIFFERENT ANIMAL MODEL GROUPS.

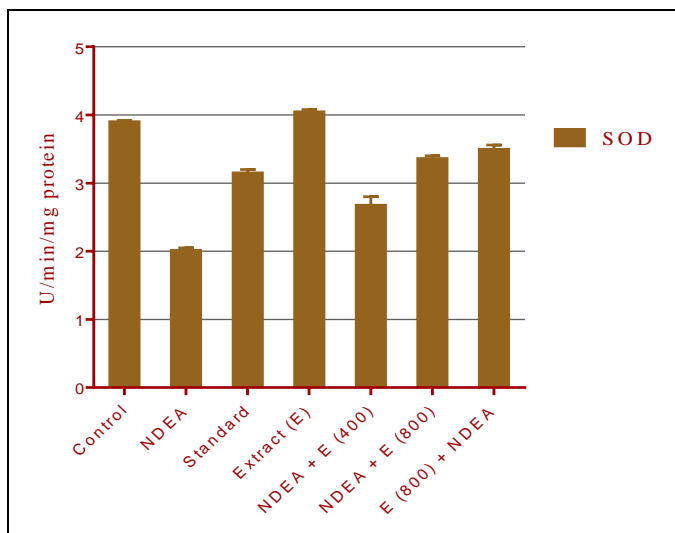


FIG. 6: SUPEROXIDE DIMUTASE (SOD) ACTIVITY IN DIFFERENT ANIMAL MODEL GROUPS.

Note: - Fig. 2, 3 Values are expressed as mean \pm SEM (n=12). Diseased group showed a significant increase in AST, ALT, ALP levels as compared to the control group.

[P<0.0001 disease vs. control group].

Fig. 4, 5, 6, 7 Analysis of hepatic oxidative stress parameters like lipid peroxidation, SOD, CAT

[P<0.05 disease vs. control group].

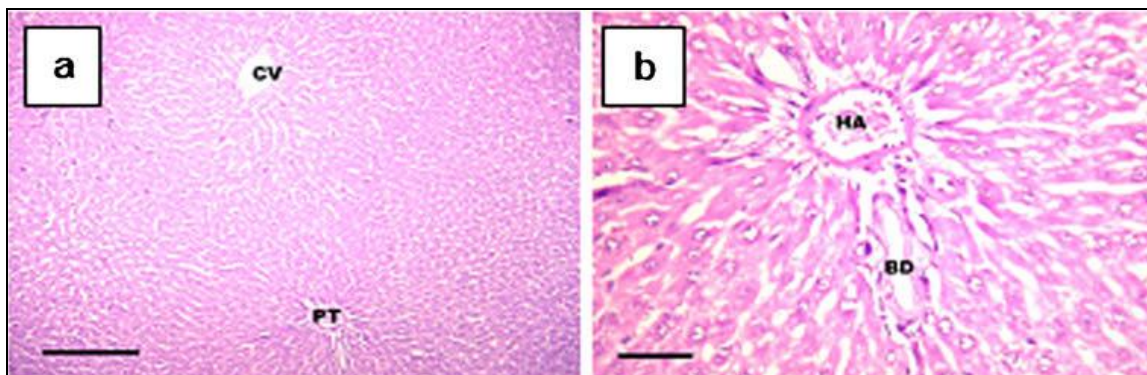
Histopathological observations:

Sections from all the six groups were examined. The histological examination of H&E –stained control liver sections showed normal architecture of hepatocytes (Fig.9a, b). The NDEA followed by 400 mg *Cichorium intybus* extract group showed moderate sinusoidal dilatation (Fig.9e, f).

The groups that received silymarin (Fig.9c, d) after NDEA or 800 mg *Cichorium intybus* extract (Fig.9g, h) and the pre-treatment group showed nearly normal liver tissue (Fig.9i). The post-treatment group also shows the centrizonal area with no sinusoidal dilatation in the liver section (Fig. 9j).

These results show that treatment with 800 mg *Cichorium intybus* extract before or after NDEA provides protection against the hepatotoxicity caused by administration of NDEA similar to that achieved by use of silymarin.

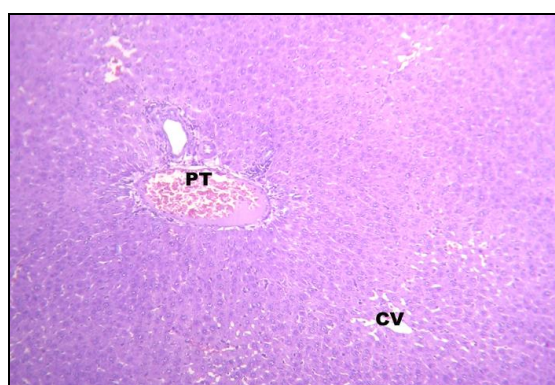Histopathological sections:



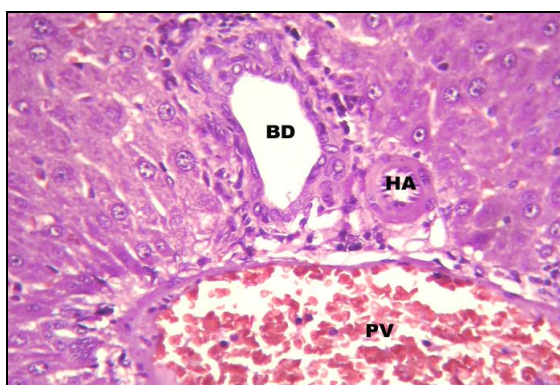
Normal Control

100X

400X

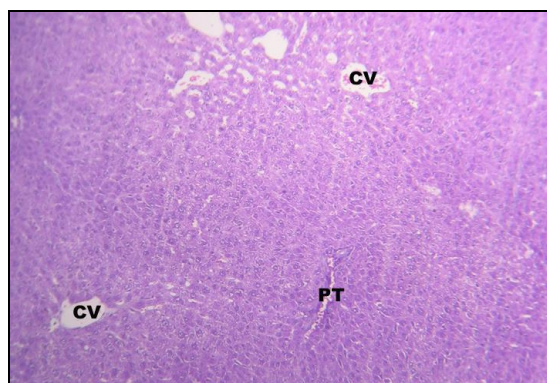


(c)10X

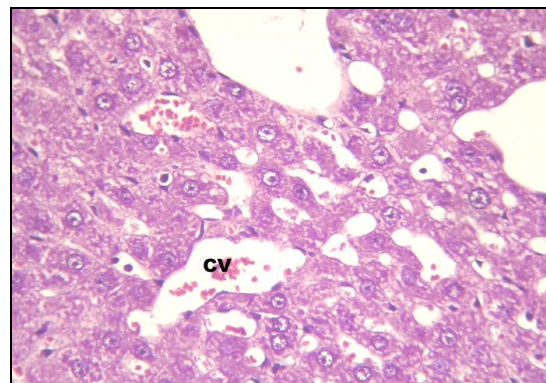


(d) 40X

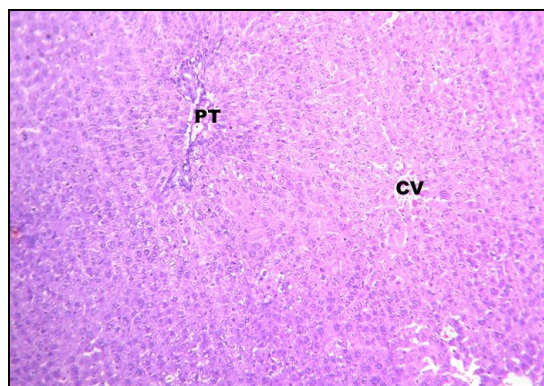
Standard Control



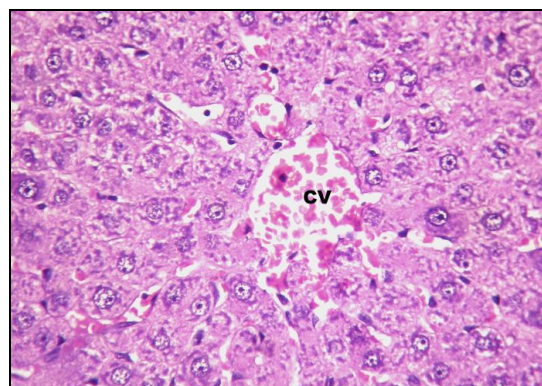
(e) NDEA + 400mg extract (10X)



(f) 40X



(g) NDEA + 800mg extract (10X)



(h) 40X

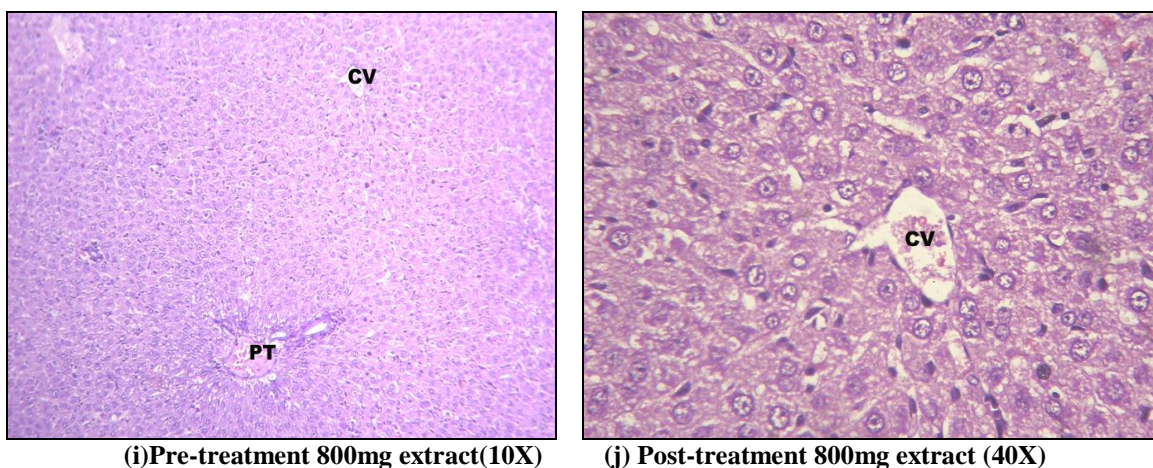


FIG. 8: HISTOPATHOLOGICAL OBSERVATIONS OF THE EFFECT OF *CICHORIUM INTYBUS* LEAF EXTRACT ON NDEA INTOXICATED MALE WISTAR RATS.

Captions:

- (a)-Liver 10x. Control group showing normal liver architecture, PT portal triad, CV central vein. (HE x 100X).
- (b)-Liver 40x Same section showing details of a normal PT; PV portal vein, BD bile duct, HA hepatic artery (HE x 400X).
- (c)-Liver 10x Low power photomicrograph of liver from animal in NDEA followed by Silymarin group showing normal arrangement of cells in the liver lobule. PT = Portal Triad and CV = Central vein. (HE x 100X).
- (d)-Liver 40x High power photomicrograph of liver from animal in NDEA followed by Silymarin group showing a portal triad. PV=Portal Vein, HA=Hepatic Artery, BD=Bile Duct (HE x 400X).
- (e)-Liver 10x Low power photomicrograph of liver from animal in NDEA followed by 400 mg C.I Extract group showing normal arrangement of cells in the liver lobule. There is moderate sinusoidal dilatation seen. PT = Portal Triad and CV = Central vein. (HE x 100X).
- (f)-Liver 40x High power photomicrograph of liver from animal in NDEA followed by 400 mg C.I Extract group showing the centrizonal area with sinusoidal dilatation seen. CV=Central Vein.(HE x 400X).
- (g)-Liver 10x Low power photomicrograph of liver from animal in NDEA followed by 800 mg C.I Extract group showing normal arrangement of cells in the liver lobule. There is no sinusoidal dilatation seen. PT = Portal Triad and CV = Central vein. (HE x 100X).
- (h)-Liver 40x High power photomicrograph of liver from animal in NDEA followed by 800 mg C.I Extract group showing the centrizonal area with no sinusoidal dilatation seen. CV=Central Vein.(HE x 400X).
- (i)-Liver 10x Low power photomicrograph of liver from animal in 800 mg C.I Extract followed by NDEA (Pre-Treatment) group showing normal arrangement of cells in the liver lobule. There is no sinusoidal dilatation seen. PT = Portal Triad and CV = Central vein. (HE x 100X).
- (j)-Liver 40x High power photomicrograph of liver from animal in NDEA followed by 800 mg C.I Extract group (Post-Treatment) showing the centrizonal area with no sinusoidal dilatation seen. CV=Central Vein.(HE x 400X).

DISCUSSION: The ethnobotanical studies of *Cichorium intybus* have proven its uses in skin diseases, calculus, enlargement of liver^{32, 33}, as stomachic, digestive, tonic, mild diuretic. Leaves are specifically used to cure jaundice³⁴ & liver disorders³⁵. Leaves and roots are also effective in curing swelling of joints³⁶. A study was conducted to determine the suitable age of harvest of green tops of chicory for extraction of edible leaf protein

by³⁷, the age of 150 to 155 d was found suitable for obtaining optimum yield of leaf protein from green tops of chicory. The study also revealed that the level of antioxidants was maximal between 40 and 50 d after sowing, indicating the optimal period of harvesting³⁸.

These studies have initiated the idea that the collection of leaves at different time intervals and

thus grading them according to their sizes (short, medium, large) may influence its activity as a hepatoprotective agent. Three different solvent system viz. water, ethanol-water (1:1 %v/v), ethanol, and two extraction process viz. hot and cold were chosen to extract all possible bioactive ingredients in the leaves in this range of solvent system. Thus eighteen extracts were prepared. Amongst these eighteen extracts, the extract having the highest extractive value was chosen for preliminary phytochemical studies and was used further for animal and histopathological studies. Our results have shown that the highest extractive value was found in the extract prepared from medium sized leaves by hot soxlation process using water-ethanol (1:1, v/v) as a solvent. Further, this extract was used for animal and histopathological studies. Two doses were selected for study based on previous research work conducted on chicory³⁹.

In our study we selected NDEA (N-nitrosodiethylamine) toxicity as NDEA is a major environmental carcinogen responsible for increasing the generation of reactive oxygen species (ROS) resulting in oxidative stress and cellular injury⁴⁰. NDEA is found in a wide variety of foods such as cheese, soybeans, salted and dried fish, cured meat and alcoholic beverages⁴¹. Metabolism of certain therapeutic drugs is also reported to produce N-nitrosodiethylamine⁴². Since liver is the main site of NDEA metabolism, the production of ROS in the liver may be responsible for its carcinogenic effects⁴³. For the assessment of drug induced hepatotoxicity, new powerful *in vitro* models are being developed, besides the *in vivo* models to study carcinogenesis in liver^{44, 45, 46, 47}.

Research Literature shows that NDEA can be administered via different routes like oral, subcutaneous, and intraperitoneal etc. We have selected intraperitoneal route for NDEA administration to rats on the basis of our previous research work⁴⁸. However, plant extract was administered orally, as based on these findings we aim to develop an oral formulation for future use.

ALT, AST, ALP are liberated into blood whenever liver cells are damaged and their increased levels in the blood are index of liver damage⁴⁹. Thus, by measuring the activities of serum marker enzymes

one can make assessment of liver function^{50, 51}. While NDEA has carcinogenicity, it is also potent alkylating agent and shows toxicity. Our results have shown that the elevated levels of ALP, AST and ALT after NDEA administration in rats, confirming the liver damage caused by this compound. Other parameters assayed were lipid peroxidation (TBARS), reduced glutathione level, Catalase (CAT), superoxide dismutase (SOD) activity. Literature review has revealed that oxidative stress is one of the key factors during carcinogenesis⁵² and Lipid peroxidation is one of the most studied biologically relevant free radical chain reactions which is initiated by the attack of a free radical on a fatty acid or fatty acyl side chain of any chemical species that has sufficient reactivity to extract a hydrogen atom from a methylene carbon side chain.

Lipid peroxidation may lead to the formation of several toxic byproducts such as malondialdehyde and 4-hydroxynonenal, which can attack cellular targets including DNA, inducing mutagenicity and carcinogenicity^{52, 53}. Administration of NDEA has been reported to generate lipid peroxidation products in general⁵⁴ and the same was also reported in the NDEA treated animals. Chemically induced liver carcinoma is associated with changes in oxygen radical metabolism in liver. The changes in hepatic oxygen radical metabolism were demonstrated by measurement of antioxidant enzymes such as SOD and catalase⁵⁵.

Tumor cells show a decrease in the activities of SOD and CAT though the mechanism is still unclear. As CAT and SOD are the two major scavenging enzymes that remove radicals *in vivo*, a decrease in activity of these antioxidants can lead to an excess availability of superoxide anion (O_2^-) and hydrogen peroxide (H_2O_2), which in turn generate hydroxyl radicals ($\cdot OH$), resulting in initiation and propagation of lipid peroxidation. SOD catalyzes dismutation of $O_2\cdot$ to H_2O_2 , which is then deactivated to H_2O by CAT^{56, 57}.

In the present study, we report that the levels of these antioxidative enzymes were also decreased in experimental groups with the progression of disease as compared to control groups, suggesting

the protective effect of the *Cichorium intybus* leaf extract in liver.

CONCLUSION: Our study aimed at identifying that particular leaf extract of *Cichorium intybus* which is effective against NDEA induced toxicity in male wistar rats. Literature review has revealed that *Cichorium intybus* (family Asteraceae) contains coumarins and sesquiterpene lactones^{58, 59}, further they can be isolated and characterized for future formulation of this extract for easy and effective dose management.

ACKNOWLEDGEMENT: The authors are grateful to Dr. Ashok K. Chauhan, Hon'ble Founder President, Amity University Uttar Pradesh, Noida for providing facilities for conducting the research.

REFERENCES:

- Rai LK, Punjak P, Sharma E: Conservation threats to some important plants of the Sikkim Himalayas. *Biological Conservation* 2000; 93:27-33.
- IARC. Some *N*-Nitroso Compounds. IARC Monographs on the Evaluation of Carcinogenic Risk of Chemicals to Humans, 17. Lyon, France: International Agency for Research on Cancer, 1978: 365.
- Brunnemann, KD, Yu L, Hoffmann D: Assessment of carcinogenic volatile *N*-nitrosamines in tobacco and in mainstream and sidestream smoke from cigarettes. *Cancer Res* 1977; 37(9): 3218-22.
- Brunnemann KD, Hoffmann D: Chemical studies on tobacco smoke LIX: analysis of volatile nitrosamines in tobacco smoke and polluted indoor environments. *IARC Sci Publ* 1978; 19: 343-56.
- Kshirsagar AD, Mohite R, Aggrawal AS, Suralkar UR: Hepatoprotective medicinal plants of ayurveda a review. *Asian J Pharm Clin Res* 2011; 4: 1-8.
- Pandey VN: Evaluation of the effects of indigenous drugs-*kutaki* (*Picrorhiza kurroa*), *Kalamaci* (*Solanum nigrum* Linn), *Kasni* (*Cichorium intybus* Linn.) and *Rohitaka* (*Tecomella undulate* G. Don. Seem) against experimentally induced chlorpromazine damage in albino rats. *J Res Ayur Siddha* 1981; 2: 77-105.
- Huseini Fallah H, Alavian SM, Heshmat R, Heydari MR, Abolmaali K: The efficacy of Liv-52 on liver cirrhotic patients a randomized, double-blind, placebo-controlled first approach. *Phytomedicine* 2005; 12(9): 619-624.
- Najmi AK, Pillai KK, and Pal SN, Aqil M: Free radical scavenging and hepatoprotective activity of jigrine against galactosamine induced hepatopathy in rats. *Journal of Ethnopharmacology* 2005; 97(3): 521-525.
- Bhosale P, Motiwale L, Ingle AD, Gadre RV, Rao KVK: Protective effect *Rhodotorula glutinis* NCIM3353 on the development of hepatic preneoplastic lesions. *Curr Sci* 2002; 83: 303-308.
- Mihael V, Christoph R, Kira B, Frank T, Mathias H, and Christian T, Tom L: Mouse models of hepatocarcinogenesis: what can we learn for the prevention of human hepatocellular carcinoma. *Oncotarget* 2010; 1: 373-378.
- Vitaglione P, Morisco F, Caporaso N: Dietary antioxidant compounds and liver health. *Crit Rev Food Sci Nutr* 2004; 44: 575-86.
- Scherer E: Neoplastic progression in experimental hepatocarcinogenesis. *Biochem Biophys Acta* 1984; 738: 219-236.
- Tamano I, Shirai ST : A medium-term rat liver bioassay for rapid *in vivo* detection of carcinogenic potential of chemicals 2003; *Cancer Sci*; 94: 3-8.
- Navarro VJ, Senior JR: Drug-related hepatotoxicity. *N Engl J Med* 2006; 354: 731-9.
- Gilani AH, Janbaz KH: Evaluation of the liver protective potential of *Cichorium intybus* seed extract on acetaminophen and CC1₄ induced damage. *Phytomedicine* 1994; 1(3): 193-197.
- Ahmed B, Howiriny TA, Siddiqui AB: Antihepatotoxic activity of seeds of *Cichorium intybus*. *Journal of Ethnopharmacology* 2003; 87: 237-240.
- Zafar R, Mujahid AS: Anti-hepatotoxic effects of root and root callus extracts of *Cichorium intybus* L. *Journal of Ethnopharmacology* 1998; 63(3): 227-231.
- Gadgoli C, Mishra SH: Antihepatotoxic activity of *Cichorium intybus*. *Journal of Ethnopharmacology* 1997; 58 (2): 131-134.
- Sultana SS, Perwaiz MI, Athar M: Crude extracts of hepatoprotective plants, *Solanum nigrum* and *Cichorium intybus* inhibit free radical-mediated DNA damage. *Journal of Ethnopharmacology* 1995; 45(3): 189-192.
- Renee AS, Sidana J, Prinsloo G: *Cichorium intybus*: Traditional Uses, Phytochemistry, Pharmacology, and Toxicology. *Evidence-Based Complementary and Alternative Medicine* 2013; 13.
- Wagner H, Bladt S: *Plant Drug Analysis: A thin Layer Chromatography Atlas*. Springer, Verlag, Berlin, 1983: 223-236, 309-313.
- Woisky R, Salatino A: Analysis of Propyls: Some parameters and procedures for chemical quality control. *J. Agri Res* 1998; 37: 99-105.
- Reitman S, Frankel S: A colorimetric method for the determination of serum oxaloacetic and glutamic pyruvic transaminases. *Am J Clin Pathol* 1957; 28: 53-56.
- Kind PRN, King EJ: Estimation of plasma phosphatase by determination of hydrolyzed phenol with amino antipyrine. *J ClinPath* 1954; 7: 322-326.
- Ohkawa H, Ohishi N, Yagi K: Assay for lipid peroxides in animals tissues by thiobarbituric acid reaction. *Analytical Biochemistry* 1979; 95:351-358.
- Lowry OH, Rosebrough NJ, Farr AL, Randall RJ. Protein measurement with the Folin phenol reagent. *J Biol Chem* 1951; 193: 265-275.
- Ellman GL: Tissue sulphhydryl groups. *Archives of Biochemistry and Biophysics* 82, 1959: 70-77.
- Claiborne A: Catalase Activity In Green Wald RA. *Handbook of methods for oxygen radical research*. CRC Press, Boca Raton, 1985: 283-284.
- Stevens MJ, Obrosova I, Cao X, Van HC, Greene DA: Effects of DL α -lipoic acid on peripheral nerve conduction, blood flow, energy metabolism, and oxidative stress in experimental diabetic neuropathy. *Diabetes* 2000; 49: 1006-1015.
- Luna LG : *Methods of Histology, Staining Methods of Armed Forces Institute of Pathology*, McGraw Hill Book Co. New York 1968: 43.

31. Mathur Neha, Pande Katare Deepshikha, Aeri Vidhu, Kishore Amitesh, Joshi Vidhushi, Madaan Alka, Verma Ritu: Determination of Antioxidants and Hepatoprotective ability of Flavonoids of *Cichorium intybus*. International Journal of Pharmacological and Toxicological Research 2014; 6(4): 107-112.
32. Shrivastava TN, Rajasekharan S, Badola DP, Shah DC : An index of the available medicinal plants, used in Indian system of medicines from Jammu and Kashmir State. Ancient Sci Life 1986; 6: 49-63.
33. Singh PB, Aswal BS: Medicinal plants of Himachal Pradesh used in Indian Pharmaceutical Industry. Bull Med Ethnobot Res 1992; 13:172-208.
34. Singh VK: Selected Indian folk medicinal claims and their relevance in primary health care programme. Glimpses Plant Res 1993; 10:147-153.
35. Bhalla S, Patel JR, Bhall NP: Ethnomedicinal observations on some asteraceae of Bundelkhand region, Madhya Pradesh. J Econ Tax Bot Addl Ser 1996; 12: 175-178.
36. Sharma A, Chakraborti KK, Handa SS: Antihepatotoxic activity of some Indian herbal formulations as compared to Silymarin. Fitoterapia 1991; 62: 229-235.
37. Mahadeviah S, Singh N: Leaf protein from the green tops of *Cichorium intybus* (Chicory). Indian J Exp Biol 1968; 6:193-194.
38. Saroja, S, Padma PR, Radha P, Thilagavathy P: Enzymic and non-enzymic antioxidants in *Cichorium intybus*, J Med Aromat Plant Sci 2001; 22(4A), 23(1A): 37-41.
39. Butt Kiran, Yunas Sana and Sheikh Maqsood Romana : Hepatoprotective effect of *Cichorium intybus* on paracetamol induced liver damage in albino rats. Libyan Agriculture Research Center Journal International 2012; 3(2): 60-63.
40. Bartsch H, Hietanen E, Malaveille C: Carcinogenic nitrosamines: free radical aspects of their action. Free Radic Biol Med 1989; 7: 637-44.
41. Liao DJ, Blanck A, Eneroth P, Gustafsson JA, Hallstrom IP: Diethylnitrosamine causes pituitary damage, disturbs hormone levels, and reduces sexual dimorphism of certain liver functions in the rat. Environ Health Perspect 2001; 109: 943-7.
42. Akintonwa DA: The derivation of nitrosamines from some therapeutic amines in the human environment. Ecotoxicol Environ Saf 1985; 9: 64-70.
43. Bansal AK, Bansal M, Soni G, Bhatnager D: Protective role of Vitamin E pre-treatment on N-nitrosodiethylamine induced oxidative stress in rat liver. Chem Biol Interact 2005; 156: 101-11.
44. Solt DB, Medline A, Farber E: Rapid emergence of carcinogen induced hyperplastic lesions in a new model for the sequential analysis of liver carcinogenesis. Am J Pathol 1977; 88: 595-61.
45. Goldsworthy TL, Hanigan MH, Pitot HC: Models of hepatocarcinogenesis in the rat contrasts and comparisons. Crit Rev Toxicol 1986; 17: 61-89.
46. Dragan YP, Campbell HA, Xu XH, and Henry CP: Quantitative stereological studies of a 'selection' protocol of hepatocarcinogenesis following initiation in neonatal male and female rats. Carcinogenesis 1997; 18: 149-158.
47. Tamano I, Shirai ST: A medium-term rat liver bioassay for rapid *in vivo* detection of carcinogenic potential of chemicals. Cancer Sci 2003; 94: 3-8.
48. Malik Shabnam, Bhatnagar Shilpa, Chaudhary Naveen, Pande Katare Deepshikha, Jain S.K: DEN +2-AAF-induced multistep hepatotumorigenesis in Wistar rats supportive evidence and insights. Protoplasma 2012; 250(1): 175-183.
49. Drotman R. and G. Lawhan: Serum enzymes are indications of chemical induced liver damage. Drug Chem. Toxicol 1978; 1: 163-171.
50. Venukumar MR, Latha MS: Hepatoprotective effect of the methanolic extract *Curculigo orchioides* in CCl₄ treated male rats. Indian J. Pharmacol 2002; 34: 269-275.
51. Christopher RW, Edwards Ian AD, Davidsons B: Principles and practice of medicine. Edinburgh, 16' 1991: 493-494.
52. Banaker MC, Paramacivan SK, Chattopadhyay MB, Datta S, Chakraborty P, Chatterjee M, Kannan K, Thygarajan E: 1 α , 25-dihydroxyvitamin D3 prevents DNA damage and restores antioxidant enzymes in rat hepatocarcinogenesis induced by diethylnitrosamine and promoted by phenobarbital. World J Gastroenterol 2004; 10: 1268-1275.
53. Zawart LL, Meerman JH, Commandeur JN, Vermeulen NP: Biomarkers of free radical damage applications in experimental animals and humans. Free Radic Biol Med 1999; 26: 202-226.
54. Hietnen E, Ahotupa M, Bartsch H : Lipid peroxidation and chemically induced cancer in rats fed lipid rich diet. In: Lapis K, Kharst SK (eds) Carcinogenesis and tumor progression 1987; 4. Akademiai kiado, Budapest: 9-16.
55. Halliwell B, Gutteridge JMC: Protection against oxidants in biological system: the superoxide theory of oxygen toxicity. In: Cheeseman KH, Slater TF (eds) Free radicals in biology and medicine 1989; Clarendon, Oxford: 144-147.
56. Aebi H : Catalase *in vitro*. Methods Enzymol 1984; 105: 121-126.
57. Kumuhekar HM, Katyane SS: Altered kinetic attributes of Na⁺-K⁺ ATPase activity in kidney, brain and erythrocyte membrane in alloxan diabetic rats. Indian J Exp Biol 1992; 30: 26-32.
58. Kisiel, W. and Michalska, K: A new coumarin glucoside ester from *Cichorium intybus*. Fitoterapia 2002; 73: 544-546.
59. Deng, Y.H., Scott, L., Swanson, D., Snyder, J.K., Sari, N. and Dogan H.Z: Guaianolide sesquiterpene lactones from *Cichorium intybus* (Asteraceae) Z. Naturforsch B. Chem. Sci. 2001; 56: 787-796.

How to cite this article:

Elhadi IM, Abd El Maged MAM and El Imam YM Mathur N, Aeri V and Katare DP: Effect of *Cichorium Intybus* Leaves on N- Nitrosodiethylamine Induced Hepatotoxicity in Wistar Rats. Int J Pharm Sci Res 2015; 6(9): 3861-71. doi: 10.13040/IJPSR.0975-8232.6(9).3861-71.

All © 2013 are reserved by International Journal of Pharmaceutical Sciences and Research. This Journal licensed under a Creative Commons Attribution-NonCommercial-ShareAlike 3.0 Unported License.

This article can be downloaded to **ANDROID OS** based mobile. Scan QR Code using Code/Bar Scanner from your mobile. (Scanners are available on Google Playstore)