



Received on 20 October, 2015; received in revised form, 03 December, 2015; accepted, 21 January, 2016; published 01 April, 2016

## PHYTOCHEMICAL, PHARMACOLOGICAL EVALUATION OF *SAPINDUS EMARGINATUS* VAHL. BARK EXTRACT FOR NEPHROPROTECTIVE ACTIVITY

H. D. Jedage \* and K. P. Manjunath

Department of Pharmacognosy, K.L.E. University, College of Pharmacy, Vidyanagar, Hubli - 580031, (Karnataka) India.

### Key words:

*Sapindus emarginatus* Vahl.,  
Ethanol extract, Ethyl acetate  
fraction, Gentamicin, Silymarin,  
Nephroprotective

### Correspondence to Author:

**H. D. Jedage**

Research Scholar,  
Department of Pharmacognosy,  
K.L.E. University, College of  
Pharmacy, Vidyanagar, Hubli -  
580031, (Karnataka) India.


**Email:** haribajedage@gmail.com

**ABSTRACT:** Gentamicin causes kidney cellular damage by alterations in biological functions. This study evaluated the nephroprotective potential of the ethanolic extract and its fraction originating from *Sapindus emarginatus* Vahl. (Sapindaceae) bark against the Gentamicin - induced nephrotoxicity in rat. **Objective:** To evaluate the nephroprotective effect of ethanol extract and its organic solvent fraction of *S. emarginatus* Vahl. in gentamicin-induced acute renal failure in rats. **Materials and Methods:** Nephrotoxicity was induced in wistar rats by intraperitoneal administration of gentamicin 100 mg/kg/day for ten days. The treatment was done with silymarin 50 mg/kg, ethanol extract 200 mg/kg/p.o. and its ethyl acetate fractions 100 mg/kg/p.o. bark of *S. emarginatus* was determined using parameters serum creatinine, urea, uric acid, blood urea nitrogen, albumin, protein, other parameters are kidney weight, body weight, urine volume and histopathology of kidney. **Results:** It was observed that the ethanol extract and its ethyl acetate fractions bark of *S. emarginatus* has brought back the altered levels of biochemical markers to the near normal levels in the dose dependent manner. In histopathological study the gentamicin-induced glomerular congestion, peritubular inflammation, tubular desquamation, tubular congestion, interstitial haemorrhage and odema of the kidney cells were found to be reduced in the group receiving the bark extracts of *S. emarginatus* along with gentamicin. **Conclusion:** The present study that ethanol and its ethyl acetate fraction possessed nephroprotective activity. The isolated fraction was found to exhibit greater nephroprotective activity than the ethanol extract

**INTRODUCTION:** Nephrotoxicity can be defined as renal disease or dysfunction that arises as a direct or indirect result of exposure to medicines and industrial or environmental chemicals. Still, aminoglycosides are useful to treat life - threatening infections in human and animals <sup>1</sup>. Gentamicin has nephrotoxic potential. Unfortunately, 30% of patients treated with gentamicin for more than 7 days show some signs of nephrotoxicity <sup>2</sup>.

It has been reported that Gentamicin - induced nephrotoxicity characterized by direct tubular necrosis that is localized mainly in the proximal tubule is followed by renal failure with an increase plasma creatinine, urea, uric acid and other plasma proteins etc <sup>3</sup>. And reactive oxygen species (ROS) generation in kidneys <sup>4, 5, 6</sup>.

Approximately, 19 million adults have chronic kidney disease and an estimated 80,000 persons have chronic kidney failure diagnosed annually in India. Kidney disease is the 9<sup>th</sup> leading cause of death in India <sup>7</sup>. According to WHO, about 75 – 80% of the world populations still rely mainly on herbal remedies; because of it is safe and without any side effects etc <sup>8</sup>. *Sapindus emarginatus* Vahl belonging to family Sapindaceae, commonly

QUICK RESPONSE CODE	DOI: 10.13040/IJPSR.0975-8232.7(4).1564-71
	Article can be accessed online on: <a href="http://www.ijpsr.com">www.ijpsr.com</a>
DOI link: <a href="http://dx.doi.org/10.13040/IJPSR.0975-8232.7(4).1564-71">http://dx.doi.org/10.13040/IJPSR.0975-8232.7(4).1564-71</a>	

known as Soap nut tree (Ritha) <sup>9</sup>. *Sapindus emarginatus* is reported to have cosmetic and medicinal potential in various literatures. In the present context, the in vivo nephroprotective activity of ethanol extract and its ethyl acetate fraction of *Sapindus emarginatus* Vahl was evaluated in wistar rats.

## MATERIALS AND METHODS:

**Collection:** The bark of *Sapindus emarginatus* Vahl were collected from Western ghat regions of (Satara -District) Maharashtra and (Belgaum - District) Karnataka state.

### Authentication:

The plant material is identified and authenticated by the Botanist Dr. Harsha Hegde, Scientist 'C' Regional Medical Research Centre, Indian Council of Medical Research, Belgaum. The voucher specimen has been deposited at the same herbaria with accession no: RMRC - 989.

### Extraction:

The ethanol extract of dried powder 1 kg. of the bark was prepared by using Soxhlet apparatus for ethanol extraction <sup>10, 11</sup>. The extracts a solvent was evaporated in rota evaporator and this extract concentrated on water bath <sup>12</sup>. The ethanol extract dried product to give yellowish – brown, sticky mass. The ethanol extract part of was named EESe. This successive extract shows presence of carbohydrate, proteins, amino acids, sterol, triterpenoids, glycosides, saponins, tannins, flavonoids, phenolic, oils and fats etc. phytoconstituents <sup>13</sup>.

### Fractionation:

The 0.5 gm. ethanol extract insoluble residue was removed by filtration and the solubles in the filtrate 100 ml. were fractionated into petroleum ether, chloroform, ethyl acetate, n – butanol and remain water <sup>14, 15, 16, 17, 18</sup>. The ethyl acetate fractions of ethanol extract (EESe) on concentrated. Finally a ethanol extract - ethyl acetate fraction light yellow solid was giving positive chemical tests for flavonoids, tannins and phenols etc. given in **Table 1** <sup>19, 20</sup>.

TABLE 1: CHEMICAL IDENTIFICATION TEST FOR ETHYL ACETATE FRACTION.

Sr. no.	Phytoconstituents	Chemical tests	Ethyl acetate fraction
01	Flavonoids	Shinoda test	+ ve
		Ferric chloride test	+ ve
		Phenazone test	- ve
02	Tannins	Gelatin test	+ ve
03	Phenols	Zinc - hydrochloride reduction test	+ ve

Where, (+ ve) = Present (- ve) = Absent

### Chromatography analysis:

The EESe and ethyl acetate fraction was separated and isolated fraction compound by column chromatography with 100 gm. of aluminium oxide active - neutral and thin layer chromatography of isolated compound fraction was performed using the mobile phase ethyl acetate : n - butanol : formic acid : water (5:3:1:1) for EESe silica gel - G. The R<sub>f</sub> value was 0.53 isolated fraction part of was named ISLTD se – A <sup>10, 14, 21, 22, 23</sup>.

### Pharmacological evaluation:

#### Drugs and chemicals:

Gentamicin, Silymarin was obtained from Abbott and Microlabs, India. The kits for all biochemical estimations were purchased from Transasia Biomedicals Ltd., India. The solvents and other chemicals used were of analytical grade.

### Animals:

Wistar rats (150 – 200 gm.) of male sex obtained from Sri Venkateshwara Enterprises, Bangalore were kept in standard environment conditions, fed with rodent diet and with water libitum. Approval from the institutional animal ethical committee for the usage of animals in the experiments was obtained. (Proposal No: 09/Mar-2014).

### Acute toxicity studies:

The acute oral toxicity study was carried out as per the guideline 423 set by Organization for Economic Cooperation and Development received from Committee for the purpose of control and supervision of Experiments on Animals <sup>24</sup>.

**Experimental design:** Animals were randomly divided in to five groups of six animals each for 10

days. Group I normal with vehicle (distilled water, p.o.) was kept as normal. Group II toxicant was received of gentamicin (100 mg/kg/i.p.). Group III standard was received silymarin (50 mg/kg/p.o.) with toxicant. Group IV treatment was received isolated fraction ethyl acetate compound (100 mg/kg/p.o.) with toxicant. Group V treatment was received ethanol extract of *Sapindus emarginatus* Vahl. (200 mg/kg/p.o.) With toxicant. On the 11<sup>th</sup> day after 2 hrs. Respective treatments the blood samples were collected for the estimation of biochemical marker enzymes. Then animals under ether anesthesia were sacrificed.

#### Histopathological study:

After collection of blood for biochemical estimation, the rats were sacrificed and the kidney was carefully dissected, cleaned of extraneous tissue, and fixed in 10% formalin for at least 24 hrs. Then the paraffin sections were prepared (automatic tissue processor Autotechnique) and cut into 5  $\mu$ m. thick sections, using a rotary microtome. The sections were stained with Haematoxylin - Eosin dye and studied for histopathological changes<sup>25</sup>.

#### Statistical analysis:

Results are given as mean  $\pm$  SEM, ( $N = 6$ ). Data was analyzed using one – way ANOVA followed by Dunnett's test. The statistical significance of difference was taken as  $P < 0.05$ . The analysis was performed by Prism software.

#### RESULTS AND DISCUSSION:

##### Acute toxicity study:

In the acute toxicity assay it was found that no mortality was observed up to doses of 2000 mg/kg, orally and hence it was considered as safe. Also there were no signs of any toxic reaction found till the end of the study period. 1/10<sup>th</sup> of the median lethal dose 50 was taken as an effective dose.

##### Nephroprotective activity:

Effect bark of ethanol extract *Sapindus emarginatus* Vahl (EESe) and isolated ethyl acetate fraction compound (ISLTD se–A) with standard silymarin on biochemical parameters in gentamicin – induced kidney toxicity in rats shows **Table 2**.

**TABLE 2: NEPHROPROTECTIVE ACTIVITY OF ETHANOL EXTRACT AND ISOLATED ETHYL ACETATE FRACTION COMPOUND IN GENTAMICIN INDUCED TOXICANT.**

Treatment	Group 1	Group 2	Group 3	Group 4	Group 5
Kidney weight	0.486 $\pm$	0.681 $\pm$	0.508 $\pm$	0.521 $\pm$	0.633 $\pm$
	0.004	0.003 <sup>###</sup>	0.003 <sup>***</sup>	0.003 <sup>***</sup>	0.003 <sup>***</sup>
Body weight	177.2 $\pm$	153.2 $\pm$	173.4 $\pm$	168.1 $\pm$	167.6 $\pm$
	1.227	0.455 <sup>###</sup>	1.077 <sup>***</sup>	0.570 <sup>***</sup>	2.256 <sup>***</sup>
Urine volume	2.917 $\pm$	2.083 $\pm$	2.700 $\pm$	2.600 $\pm$	2.317 $\pm$
	0.030	0.030 <sup>###</sup>	0.025 <sup>***</sup>	0.025 <sup>***</sup>	0.030 <sup>***</sup>
Creatinine	0.676 $\pm$	1.742 $\pm$	0.763 $\pm$	0.808 $\pm$	1.418 $\pm$
	0.006	0.011 <sup>###</sup>	0.004 <sup>***</sup>	0.007 <sup>***</sup>	0.007 <sup>***</sup>
Urea	40.58 $\pm$	146.3 $\pm$	45.25 $\pm$	41.44 $\pm$	114.4 $\pm$
	0.155	0.257 <sup>###</sup>	0.015 <sup>***</sup>	7.317 <sup>***</sup>	0.178 <sup>***</sup>
Uric acid	4.347 $\pm$	12.13 $\pm$	5.183 $\pm$	5.228 $\pm$	9.550 $\pm$
	0.013	0.008 <sup>###</sup>	0.098 <sup>***</sup>	0.014 <sup>***</sup>	0.140 <sup>***</sup>
Blood Urea Nitrogen	18.25 $\pm$	59.53 $\pm$	22.43 $\pm$	25.57 $\pm$	46.37 $\pm$
	0.071	0.128 <sup>###</sup>	0.117 <sup>***</sup>	0.133 <sup>***</sup>	0.190 <sup>***</sup>
Albumin	3.850 $\pm$	1.487 $\pm$	3.218 $\pm$	2.930 $\pm$	2.200 $\pm$
	0.015	0.004 <sup>###</sup>	0.005 <sup>***</sup>	0.017 <sup>***</sup>	0.112 <sup>***</sup>
Protein	6.553 $\pm$	3.335 $\pm$	5.420 $\pm$	5.283 $\pm$	4.115 $\pm$
	0.013	0.011 <sup>###</sup>	0.005 <sup>***</sup>	0.079 <sup>***</sup>	0.080 <sup>***</sup>

The aminoglycosides induce nephrotoxicity in observed 10 - 20% of therapeutic courses. The widespread therapeutic use of the gentamicin is limited because of its nephrotoxic side effect and oxidative damage which can lead to acute renal failure<sup>26, 27, 28</sup>.

Gentamicin is one of the effective antibiotics used in the treatment of gram negative bacterial infection. A major complication of the use of these drugs is nephrotoxicity. The pathogenesis of aminoglycosides nephrotoxicity is a two – step process. The first step entails the transportation and

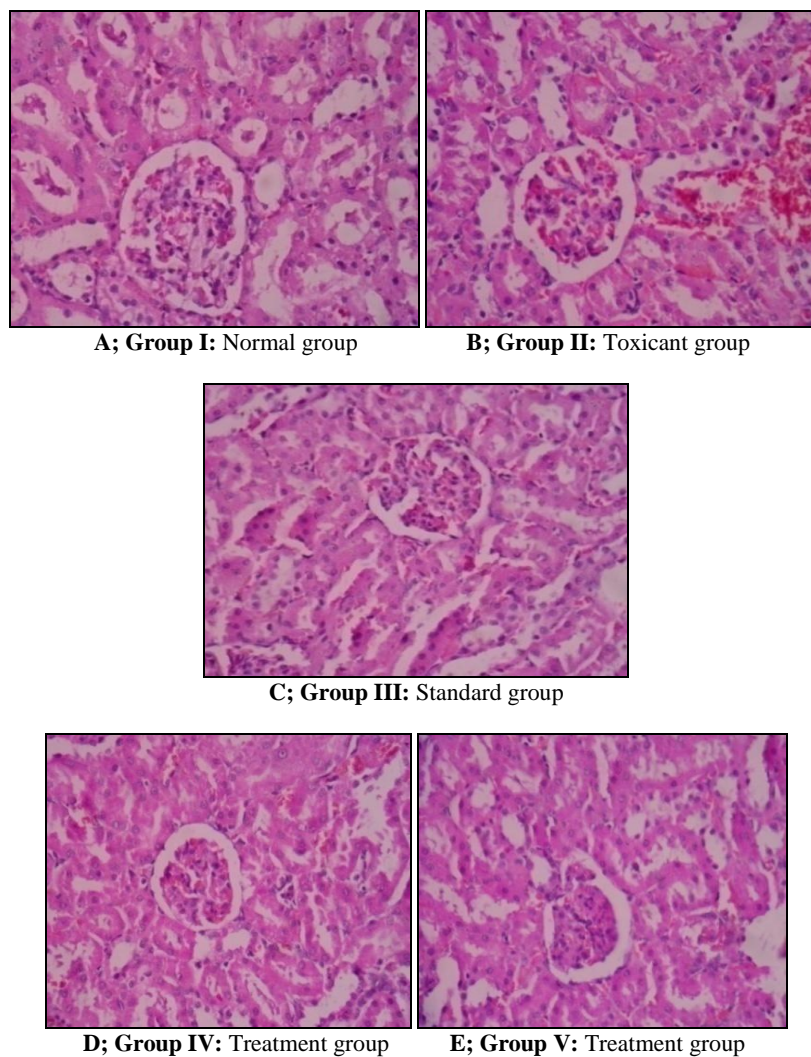
accretion of antibiotics in high concentration by renal proximal tubular cells. The second step involves the adverse interaction between these polycationic drugs leading to cellular damage<sup>29, 30, 31</sup>. A direct interstitial haemorrhage is also observed during nephrotoxicity. Data from recent studies showed that the cationic proteins and peptides, inhibit the uptake of a nephrotoxic drug, gentamicin, which is highly accumulated in the kidneys. The mechanism underlying gentamicin – induced renal cellular damage by generation of superoxide anion, hydrogen peroxide (H<sub>2</sub>O<sub>2</sub>), hydroxyl radicals and reactive oxygen species (ROS) generation in kidneys and finally this has been attributed to its deleterious effect on the kidney<sup>32, 33</sup>.

An association between nephrotoxicity and oxidative stress has been confirmed in many experimental models<sup>34, 35, 36</sup>.

In our experiment it is observed that a gentamicin induced group increased kidney weight, serum creatinine, urea, uric acid, blood urea nitrogen decreased body weight, urine volume, albumin, protein. All in the toxicant group it is also clearly indicates kidney damage due to gentamicin.

Treatment with silymarin, ethanol extract *Sapindus emarginatus* Vahl (EESe) and isolated ethyl acetate fraction compound (ISLTD se–A) has decreased in the levels of various biochemical markers of kidney i.e. serum creatinine, urea, uric acid, blood urea nitrogen, kidney weight and increased albumin, protein, body weight, urine volume. All parameters in serum and others observed to the near healthy levels or normal values of rat.

Histopathological profiles of rat kidney shows in **Fig. 1** also reveal a major damage in the same groups.

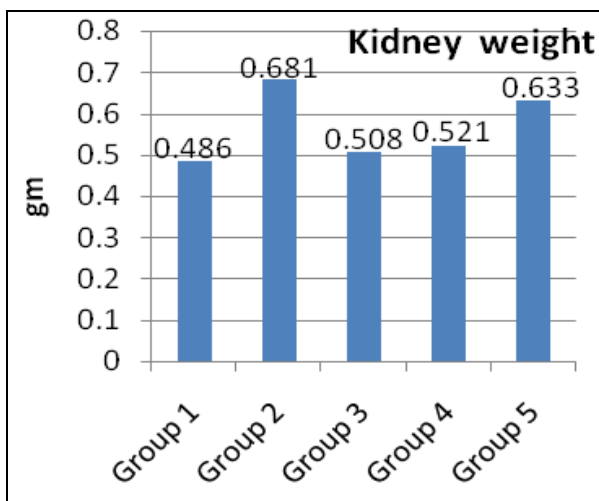


**FIG.1: HISTOPATHOLOGY OF KIDNEY RAT.**

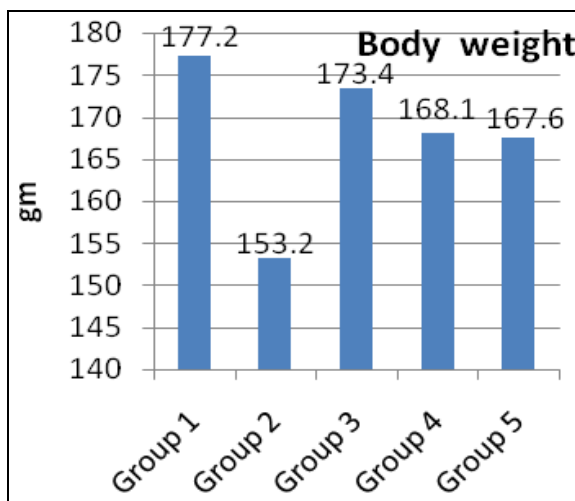
The observable fact was proved by kidney biopsy **Fig.1 (A)**; Group: I the kidney cell of normal (vehicle) Tubular congestion, Peritubular inflammation, Glomerular congestion, Interstitial odema, Loss of brush border, Tubular desquamation, Tubular cast, Tubular degeneration, Interstitial haemorrhage etc. is normal. **Fig.1 (B)**; Group: II The kidney necrosis is occurred in Tubular congestion, Peritubular inflammation, Glomerular congestion, Interstitial odema, Loss of brush border, Tubular desquamation, Tubular cast, Tubular degeneration, Interstitial haemorrhage observed gentamicin received group. **Fig. 1 (C)**; Group: III Standard silymarin treatment group shows Tubular congestion, Tubular degeneration, Peritubular inflammation, Interstitial odema, Loss of brush border, Tubular desquamation, Tubular cast, Interstitial haemorrhage is similar to that normal group. **Fig.1 (D)**; Group: IV Treatment with isolated ethyl acetate fraction compound

(ISLTD se-A) shows Tubular congestion, Tubular degeneration, Tubular desquamation, Peritubular inflammation, Interstitial odema, Loss of brush border, Tubular cast, Interstitial haemorrhage. **Fig. 1 (E)**; Group: V Treatment with ethanol extract of bark *Sapindus emarginatus* Vahl (EESe) shows central Tubular congestion, Glomerular congestion, Tubular desquamation, Peritubular inflammation, Interstitial odema, Loss of brush border, Tubular cast, Interstitial haemorrhage. All treatments groups of kidney rat is repaired minimal injuries & better protection.

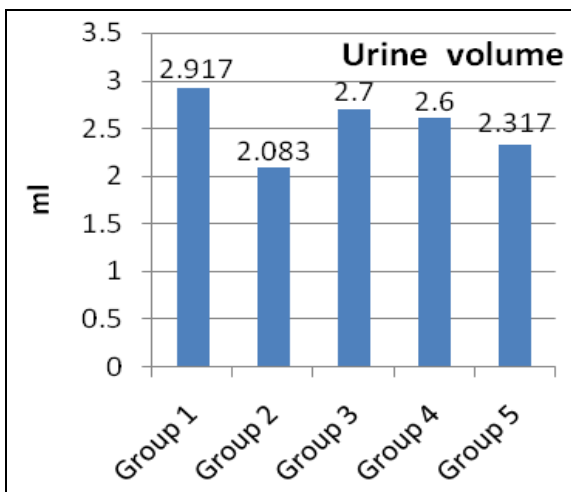
The graphical presentation nephroprotective activity of ethanol extract (EESe), isolated ethyl acetate fraction compound (ISLTD se-A) is compared with standard silymarin in gentamicin induced toxicant; all data shows in bar type **Graphs 1**.



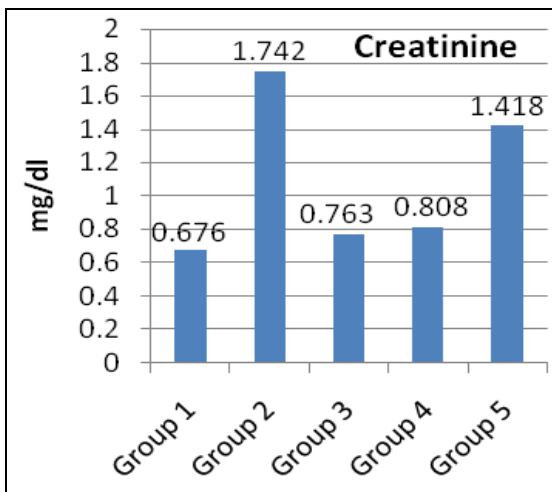
a. KIDNEY WEIGHT



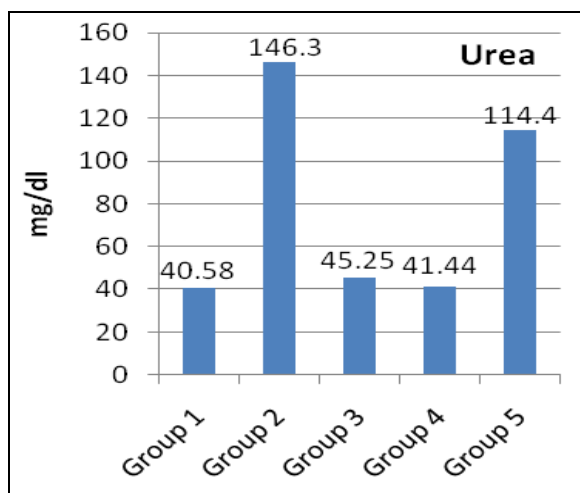
b. BODY WEIGHT



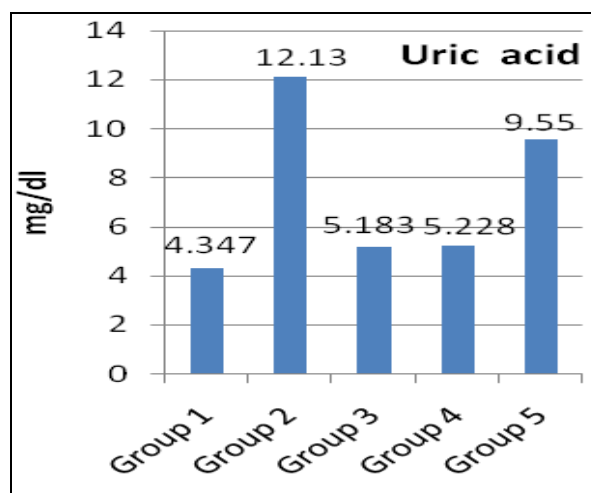
c. URINE VOLUME



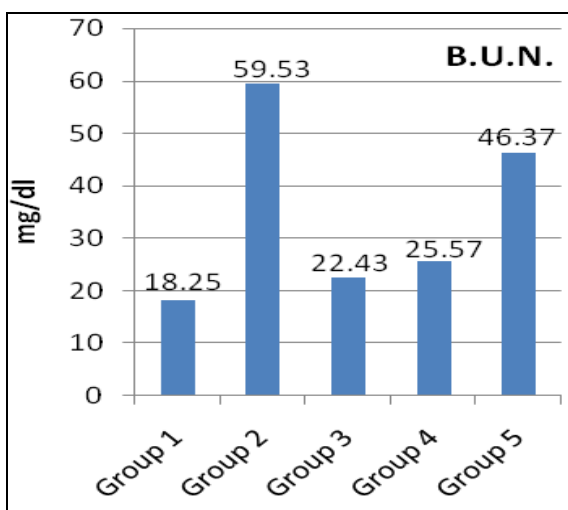
d. CREATININE



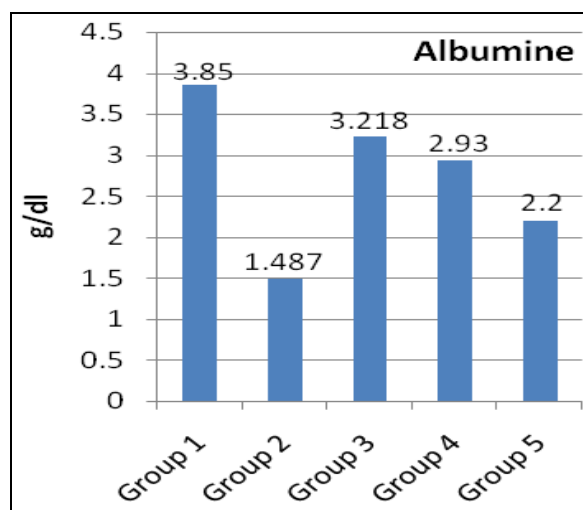
e. UREA



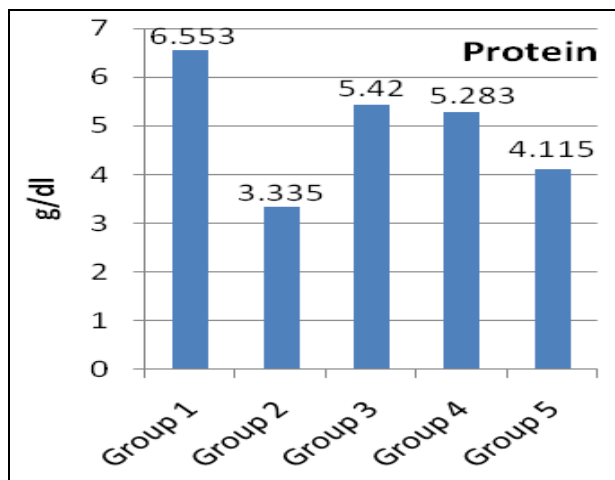
f. URIC ACID



g. BLOOD UREA NITROGEN



h. ALBUMIN



i. PROTEIN

GRAPH 1: THE GRAPHS PRESENTS NEPHROPROTECTIVE ACTIVITY OF ETHANOL EXTRACT AND ITS ISOLATED ETHYL ACETATE FRACTION COMPARED WITH STANDARD SILYMARIN IN GENTAMICIN INDUCED TOXICANT.

**CONCLUSION:** This nephroprotective activity of the *Sapindus emarginatus* Vahl ethanol extracts and ethyl acetate fraction may be due to antioxidant activity which may be due to the presence of

flavonoids and phenolic compounds. The results of our study demonstrate the nephroprotective activity of ethanol extract of *S. emarginatus* Vahl is less effective than ethyl acetate fraction of ethanol

extract of *S. emarginatus* Vahl. The mechanism for its protection against cellular damage may be due to its presence of flavonoids (rutin), tannins and phenolic compounds etc. having good antioxidant activity. All data is justifying the use of this plant for treatment of nephroprotective. Further clinical investigation is warranted.

**ACKNOWLEDGEMENTS:** The authors are thankful to K.L.E. University Belgaum and Principal, K.L.E. University's College of Pharmacy Hubli - 31 (Karnataka) India, for providing the necessary facilities to carry out the work.

## REFERENCES:

- Kakalij RM, Alla CP, Kshirsagar RP, Kumar BH, Mutha SS and Diwan PV: Ameliorative effect of *Elaeocarpus ganitrus* on gentamicin - induced nephrotoxicity in rats. *Indian Journal of Pharmacology* 2014; 46 (3): 298-302.
- Reiter RJ, Tan DX, Sainz RM, Mayo JC and Lopez - Burillo S: Melatonin: Reducing the toxicity and increasing the efficacy of drugs. *Journal of Pharmacy and Pharmacology* 2002; 54 (10): 1299-1321.
- Walker PD and Shah SV: Gentamicin enhanced production of hydrogen peroxide by renal cortical mitochondria. *American Journal Physiology* 1987; 253 (4 pt 1): C495-499.
- Cuzzocrea S, Mazzon E, Dugo L, Serraino I, Di Paola R, Britti D and et al: A role for superoxide in gentamicin - mediated nephropathy in rats. *European Journal Pharmacology* 2002; 450 (1): 67-76.
- Al-Majed AA, Mostafa AM, Al-Rikabi AC and Al-Shabanah OA: Protective effects of oral *Arabic gum* administration on gentamicin - induced nephrotoxicity in rats. *Pharmacology Research* 2002; 46 (5): 445-451.
- Baliga R, Ueda N, Walker PD and Shah SV: Oxidant mechanisms in toxic acute renal failure. *Drug Metabolism Reviews* 1999; 31 (4): 971-997.
- Priyadarsini G, Kumar A, Anbu J, Anjana A and Ayyasamy S: Nephroprotective activity of decoction of *Indigofera tinctoria* against Cisplatin - induced nephropathy in rats. *International Journal of Life Science and Pharma Research* 2012; 2 (4): 56-62.
- Sharma SK, Sharma SM, Saini V and Mohapatra S: Hepatoprotective effect of *Abutilon indicum* on Carbon tetra chloride induced hepatotoxicity. *The Global Journal of Pharmaceutical Research* 2013; 2 (1): 1608-1612.
- Nadkarni KM: *Indian Materia Medica*. Popular Prakashan Pvt. Ltd, Mumbai, Edition 3, Vol. I, 1976: 1102-1103.
- Anonymous: *Phytochemical Reference Standards of Selected Indian Medicinal Plants*. Indian Plants Unit, Indian Council of Medical Research, New Delhi, Edition 1, Vol. 1, 2003: Appendix - II- 343.
- Agrawal SS and Paridhavi M: *Herbal Drug Technology*. Universities press, Hyderabad, Edition 2, 2012: 324-326.
- Anonymous: *World Health Organization. Quality Control Methods for Medicinal Plant Materials* Geneva. APTBS Publisher and Distributor, New- Delhi, Edition 1, 1998: 56.
- Jedage HD and Manjunath KP: Pharmacognostic and preliminary phytochemical evaluation on bark of *Sapindus emarginatus* Vahl. *Indian Journal of Natural Products* 2015; 29 (1): 89-94.
- Houghton PJ and Raman A: *Laboratory Handbook for the Fractionation of Natural Extracts*, Thomson publication, London, Edition 1, 1998: 54-65.
- Dinnimath BM and Jalalpure SS: Spectral analysis of fractions of *Aerva lanata* L. *Indian Journal of Natural Products* 2012; 28 (2): 14-19.
- Rajesh R, Chitra K and Prakash PM: *Aerva lanata* (Linn) Juss. ex Schult - An overview. *Indian Journal of Natural Products and Resources* 2011; 2 (1): 5-9.
- Kane SR, Apte VA, Todkar SS and Mohite SK: Diuretic and laxative activity of ethanolic extract and its fractions of *Euphorbia thymifolia* L. *International Journal of Chem Tech Research* 2009; 1 (2): 149-152.
- Hossain MA, Nagooru MR and Gansau JAB: New flavones from the leaves of local medicinal plant *Corydiline terminalis* Kunth. *International Journal of Biology and Plant Research* 2012; 3 (2): 223-226.
- Khandelwal KR: *Practical Pharmacognosy and Experimental Techniques*. Edited by Sethi V. Nirali Prakashan, Pune, Edition 22, 2012: 25.1- 25.9.
- Kokate CK, Purohit AP and Gokhale SB: *Text Book of Pharmacognosy*. Nirali Prakashan, Pune, Edition 41, 2008: A5-A6.
- Harborne JB: *Phytochemical methods- A Guide to Modern Techniques of Plant Analysis*. Chapman and Hall, London, Edition 3; 2004: 40-96.
- Stahl E: *Thin Layer Chromatography, A Laboratory Handbook*. In: Kurt E. Hydrophilic plant constituents and their Derivatives. Springer - Verlag Berlin, Heidelberg, New York, Edition 2, 1969: 687-705.
- Wagner H and Bladt S: *Plant Drug Analysis, A Thin Layer Chromatography Atlas*. In: Rickl V, Colored photograph. Springer - Verlag Berlin Heidelberg, New York, Edition 2, 1996: 195-244.
- Anonymous; OECD [Organization for Economic Co-operation and Development]. *Guideline - 423 Acute Oral Toxicity - Fixed dose procedure*, Paris: OECD; 2001.
- Dixit VK and Gupta NK: Evaluation of hepatoprotective activity of *Cleome viscosa* Linn. extract. *Indian Journal of Pharmacology* 2009; 41 (1): 36-40.
- Balakumar P, Rohilla A and Thangathirupathi A: Gentamicin - induced nephrotoxicity: Do we have a promising therapeutic approach to blunt it? *Pharmacology Research* 2010; 62 (3): 179-86.
- Martinez Salgado C, Lopez Hernandez FJ and Lopez Novoa JM: Glomerular nephrotoxicity of aminoglycosides. *Toxicology and Applied Pharmacology* 2007; 223 (1): 86-98.
- Stojiljkovic N, Mihailovic D, Veljkovic S, Stoilkovic M and Jovanovic I: Glomerular basement membrane alterations induced by gentamicin administration in rats. *Experimetal and Toxicologic Pathology* 2008; 60 (1): 69-75
- Mohammed TB and Sadeghnia HR: Protective effect of safranal against gentamicin - induced nephrotoxicity in rat. *Iranian Journal of Medical Sciences* 2009; 34 (4): 285-288.
- Kaloyanides GJ: Aminoglycosides induced functional and biochemical defects in the renal cortex. *Fundamental and Applied Toxicology* 1984; 4 (6): 930-943.
- Sonkar N, Ganeshpurkar A, Yadav P, Dubey S, Bansal D and Dubey N: An experimetal evaluation of nephroprotective potential of *Butea monosperma* extract in

- albino rats. Indian Journal of Pharmacology 2014; 46 (1): 109-112.
32. Baliga R, Ueda N, Walker PD and Shah SV: Oxidant mechanisms in toxic acute renal failure. American Journal of Kidney Diseases 1997; 29 (3): 465-477.
33. Walker PD, Barri Y and Shah SV: Oxidant mechanisms in gentamicin nephrotoxicity. Renal Failure 1999; 21 (3-4): 433-442.
34. Ghaznavi R, Faghihi M, Kadkhodae M, Shams S and Khastar H: Effects of nitric oxide on gentamicin toxicity in isolated perfused rat kidneys. Journal of Nephrology 2005; 18 (5): 548-552.
35. Ozbek E, Turkoz Y, Sahna E, Ozugurlu F, Mizrak B and Ozbek M: Melatonin administration prevents the nephrotoxicity induced by gentamicin. British Journal of Urology International 2000; 85 (6): 742-746.
36. Bashan I, Bashan P, Secilmis MA and Singirik E: Protective effect of L-arginine on gentamicin-induced nephrotoxicity in rats. Indian Journal of Pharmacology 2014; 46 (6): 608-612.

**How to cite this article:**

Jedage HD and Manjunath KP: Phytochemical, Pharmacological Evaluation of *sapindus emarginatus* Vahl. Bark Extract for Nephroprotective Activity. Int J Pharm Sci Res 2016; 7(4): 1564-71. doi: 10.13040/IJPSR.0975-8232.7(4).1564-71.

All © 2013 are reserved by International Journal of Pharmaceutical Sciences and Research. This Journal licensed under a Creative Commons Attribution-NonCommercial-ShareAlike 3.0 Unported License.

This article can be downloaded to **ANDROID OS** based mobile. Scan QR Code using Code/Bar Scanner from your mobile. (Scanners are available on Google Playstore)