



Received on 30 May, 2016; received in revised form, 11 July, 2016; accepted, 27 July, 2016; published 01 November, 2016

EVALUATION OF ANTI-DIABETIC AND HEPATOPROTECTIVITY OF *CORIANDRUM SATIVUM* IN ALLOXAN INDUCED EXPERIMENTAL ANIMALS: A HISTOPATHOLOGY STUDY

Bhaskar Sharma¹, Suresh C Joshi² Nakuleshwar Dut Jasuja¹, Sunil Kumar Singh³ and Gaurav Sharma^{*1}

School of Science¹, Suresh Gyan Vihar University, Jagatpura, Jaipur- 302017, Rajasthan, India.

Reproductive Toxicology Unit², Center for advanced studies, Department of Zoology, University of Rajasthan, Jaipur, India.

Department of Pharmacognosy³, United Institute of Pharmacy, Allahabad, Uttar Pradesh India.

Keywords:

Alloxanized Diabetes,
SGOT, SGPT, ALP
and Bilirubin, *Coriandrum sativum*

Correspondence to Author:

Dr. Gaurav Sharma (Ph.D)

Head & Associate Professor
School of Science, Suresh Gyan
Vihar University, Jaipur- 302017
(Rajasthan), India


E-mail: jai_gaurav06@rediffmail.com

ABSTRACT: Objective: Diabetes mellitus is metabolic disorder and day by day number of people increased across the world. The aim of the present study was to evaluate the antidiabetic and hepatoprotectivity of ethanolic extracts of *Coriandrum sativum* in alloxan induced diabetic rat and find out the harmonious activity of the extract. **Methods:** The alloxan (150 mg/kg, *i.p*) used for induction of diabetes after making diabetic model the ethanolic extract of *Coriandrum sativum* leaves used at a dose of 200 and 400 mg/kg b.w. respectively for single extract treatment for four weeks including metformin (200mg/kg b.w) as a reference drug. The statistical analyses were carried out by one- way ANOVA with post-hoc by Dunnett's Multiple Comparison Test. **Results:** After 28 days treatment the extracts significantly ($p < 0.001$) reduces serum glucose level and recovered liver function tests ($p < 0.001$) (SGOT, SGPT, ALP and bilirubin) as well glycosylated haemoglobin ($p < 0.001$). Histopathological study showed amelioration in alloxan treated groups. **Conclusions:** The result suggested that anti-antidiabetic and hepatoprotectivity potential of *Coriandrum sativum*.

INTRODUCTION: Diabetes mellitus (DM) is a metabolic disorder which is characterized by hyperglycemias and disturbance of carbohydrate and glycogenolysis and gluconeogenesis fat and protein metabolism. According to WHO, number of people increased from 171 million to 300 million in 2030. DM is associated with chronicle higher risk including heart attacks, blindness, kidney failure and neuropathy¹.

A medicinal plant is being used from ancient time for the treatment of diabetes. In harmony with to ethno botanical information, more than 800 medicinal plants are beneficial for curing of diabetes. But in which few are effective for curing. Herbal medicine are widely used by the people, throughout 80 % population in world used it due to its lesser side effect, efficacy and in expensive².

In the present investigation, *Coriandrum sativum* leaves were tested for their antidiabetic efficacy. *Coriandrum sativum* (family: Umbelliferae) is a herb which is widely found across the world and cultivated for its nutritional value³. Phytochemical analysis of *C. sativum* have contain DPPH radical scavenging activity, lipoxygenase inhibition,

QUICK RESPONSE CODE 	DOI: 10.13040/IJPSR.0975-8232.7(11).4510-15
Article can be accessed online on: www.ijpsr.com	
DOI link: http://dx.doi.org/10.13040/IJPSR.0975-8232.7(11).4510-15	

phospholipid peroxidation inhibition, iron chelating activity, hydroxyl radical scavenging activity, superoxide dismutation, glutathione reduction and antilipid peroxidation. Extraction of *C. sativum* contain huge amount of total phenolic, tannin, saponin, pyrogallol, caffeic acid, glycitin⁴. It was shown that coriander extracts have phenolic compounds with anti-oxidative activity⁵. Coriander has been stated that a great pharmacological effects such as anti peroxidative⁶, antihyperglycaemic⁷ hypolipidemic⁸ antioxidant⁹.

MATERIALS AND METHODS:

Collection and Preparation of *Coriandrum sativum* ethanolic extract: Fresh leaves of *Coriandrum sativum* were collected from company garden, Allahabad were identified by Dr. S.L. Gupta, scientist-E & Head, Botanical survey of India, Allahabad (BSI/CRC/BS-2/2014-2015). The fresh leaves of *Coriandrum sativum* (1000gm) were washed thoroughly with distilled water, dried without exposure of sun light and powdered used for extraction. It was kept in 70% ethanol for four days. The resulted extract was filtered with Whatmann filter paper no-1 and concentrated by soxhlet apparatus for 12 hr at 30° C. Ethanol was evaporated using rotary evaporator under reduced pressure and low temperature it is stored in air tight containers at 10° C. The yield was 12.21 %.

Animals:

Albino Wistar rats either same sex and body weight of 150–200 gm were selected for the experiments. The animals were kept under standard condition, fed with pellet diet and water *ad libitum*. Permission for the experiment was approved by Institutional Animal Ethics Committee Guidelines (UIP/IAEC/APRIL-2015/08).

Induction of diabetes:

12 hr fasted rats were made diabetic by injecting alloxan monohydrate (was taken up in NaCl) at a dose of 150 mg/kg body weight. After alloxan induction, rats with hyperglycemia were made likely by tail vein blood glucose level with the help of glucometer.

Animal model and Measurement of Biochemical parameters: The rats divided into following groups with six rats in each.

Group I (Control) served as normal and received the vehicle alone.

Group II (DM) animals received alloxan (150 mg/kg b.w) by intraperitoneal injection.

Group III (DM+C.S₂₀₀) *Coriandrum sativum* at a dose of 200 mg / kg b.w for four weeks.

Group IV (DM+C.S₄₀₀) *Coriandrum sativum* at a dose of 400 mg / kg b.w for four weeks.

Group V (DM+MET₂₀₀) metformin at a dose of 200mg/kg b.w for four weeks.

After the 28 days, animals were sacrificed and blood was collected by the orbital sinus puncture method of Herck, *et al.*, 1998¹⁰. Blood was collected in a dried centrifuged tube and allowed to clot. Blood was centrifuged at 3000 rpm for 15 min at room temperature. The serum was collected carefully and kept at -20° C until analysis biochemical analysis. Meanwhile, other biochemical parameters (SGOT, SGPT, ALP, total bilirubin, glucose and glycosylated) were estimated according to the protocol of the manual of diagnostic kits.

Histopathology

At the completion of experiment all groups animal sacrificed under using mild anesthesia (Diethyl ether) and liver dissected out from the animal for histopathology. Liver tissue fixed at 10% formalin. The tissues were dehydrated in 30% to 100% absolute alcohol for 15 minute. The tissues were cleaned in absolute alcohol with xylene (1:1) and then in pure xylene for one hour. Then after passing through a mixture of xylene and molten wax (1:1) for one hour, it was embedded in molten paraffin wax. The Blocks were made using L- moulds and staining with Hematoxylin - eosin.

Statistical analysis:

All results were expressed as mean ± standard deviation (N=6). A statistical analysis was analysed by one way analysis variance (ANOVA) with the help of Dunnett's Multiple Comparison Test using graph pad In Stat version 5. At significant value is p<0.001.

RESULT:**Antihyperglycemic activity:**

Diabetic was made by alloxan and anti-diabetic activity of ethanolic extract of C.S leaf on alloxan induced rats was presented in **Fig.1**. The activity of serum glucose level (304.5 ± 4.42 mg/dl) was significantly increased ($p < 0.001$) in alloxan treated group compared to normal level (85.96 ± 5.37 mg/dl). Whereas oral administration with ethanolic extract of *Coriandrum sativum* leaf at different dose (200 and 400 mg/kg b.w) significantly decreased ($p < 0.001$) was observed in alloxan induced diabetic rats. Which were showing prominent antidiabetic role of C.S leaf extract. On the other hand standard drug (metformin) showing decline the blood glucose level (179.7 ± 4.70 mg/dl) as compared to alloxan treated group.

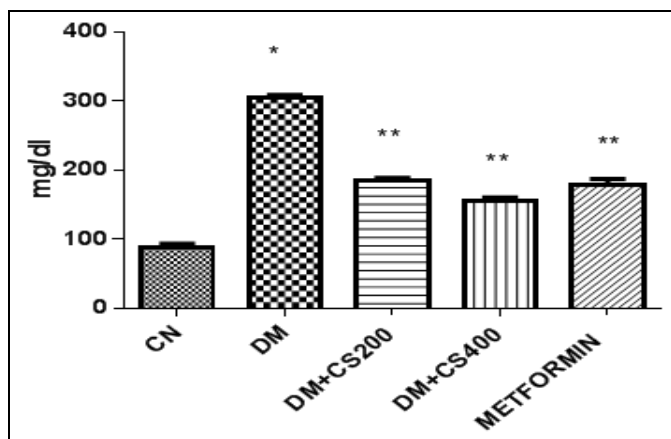


FIG.1: EFFECT OF CORIANDRUM SATIVUM ON THE SERUM GLUCOSE IN ALLOXAN INDUCED DIABETIC MODEL. VALUES ARE STATISTICALLY SIGNIFICANT AT $p < 0.001$. * COMPARED TO CONTROL GROUP AND ** COMPARED TO DIABETIC MODEL.

Liver marker enzymes activity:

Significant ($p < 0.001$) increased SGOT (85.40 ± 3.55 IU/ml), SGPT (62.29 ± 2.70 IU/ml), ALP (211.1 ± 8.67 IU/ml) and bilirubin (1.08 ± 0.11 mg/dl) was observed compared control group (**Fig.2**). Oral feeding of *Coriandrum sativum* (200 and 400 mg/kg b.w) for 28 days caused significant ($p < 0.001$) reversal SGOT (79.36 ± 2.29 ; 65.09 ± 2.70 IU/ml), SGPT (57.51 ± 3.78 ; 40.63 ± 2.40 IU/ml), ALP (167.7 ± 7.21 ; 136.6 ± 5.86 IU/ml) and bilirubin (0.81 ± 0.09 ; 0.67 ± 0.09 mg/dl) level. However, treatment with metformin in alloxan treated group the activity of SGOT (76.97 ± 2.79 IU/ml), SGPT (60.29 ± 3.85 IU/ml), ALP (138.8 ± 6.08 IU/ml) and bilirubin (0.69 ± 0.10 mg/dl) were observed downturn.

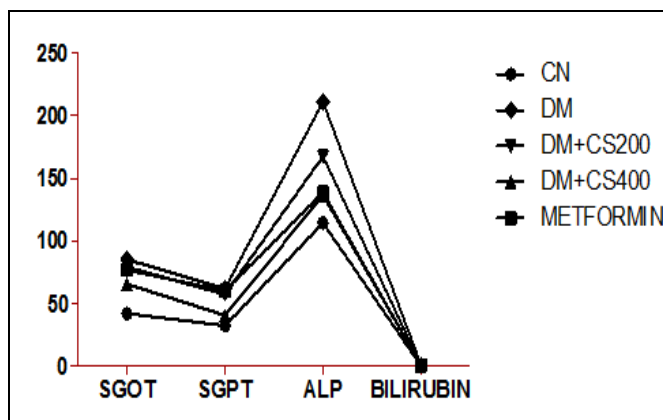


FIG.2: EFFECT OF CORIANDRUM SATIVUM ON LIVER MARKER ENZYMES IN ALLOXAN INDUCED DIABETIC MODEL. VALUES ARE STATISTICALLY SIGNIFICANT AT $p < 0.001$.

Effect of Coriandrum sativum on glycosylated haemoglobin

The level of glycosylated haemoglobin were increased ($p < 0.001$) in alloxan treated rat (11.43 ± 1.35 g/dl) as compared to control group (6.77 ± 1.42 g/dl). Oral administration of at the different dose of C.S extract (200 and 400 mg/kg b.w) on alloxan treated group showed decline (8.22 ± 1.05 ; 6.00 ± 1.04 g/dl) and metformin treated group significantly ($p < 0.001$) reversed (8.01 ± 1.05 g/dl) in alloxan treated group. (**Fig.3**)

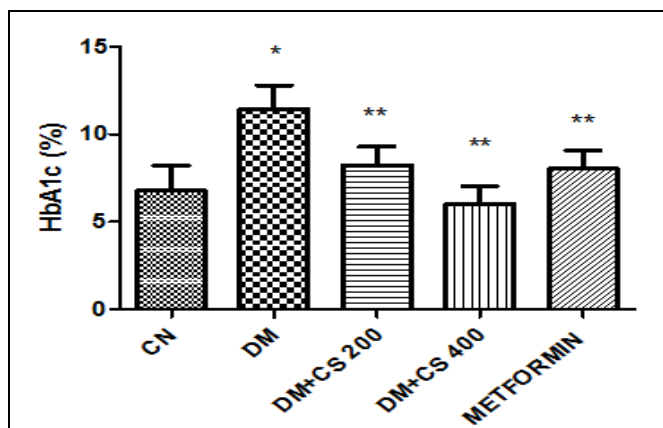


FIG. 3: EFFECT OF CORIANDRUM SATIVUM ON THE GLYCOSYLATED HAEMOGLOBIN IN ALLOXAN INDUCED DIABETIC MODEL. VALUES ARE STATISTICALLY SIGNIFICANT AT $P < 0.001$. * COMPARED TO CONTROL GROUP AND ** COMPARED TO DIABETIC MODEL.

Histopathology:

In **Fig.4** showed normal structure of liver tissue, where as **Fig.5** revealed change due to alloxan induce in rats, structure of central vein and hepatocytes were abnormal. Oral feeding of

ethanolic extract of *Coriandrum sativum* leaf on diabetic rats, its showed towards to normal (Fig.6-

7). However, standard drug treated group, there was slightly changes its structure (Fig.8).

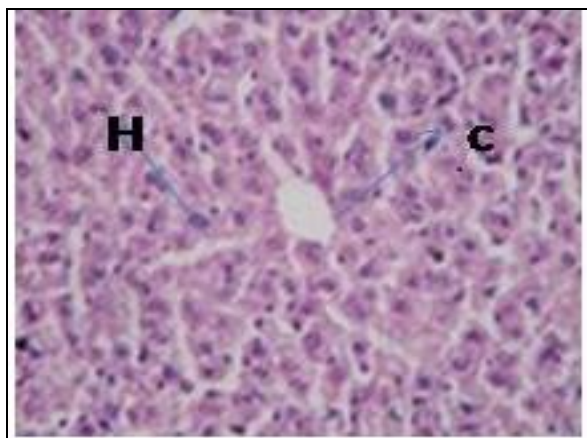


FIG. 4

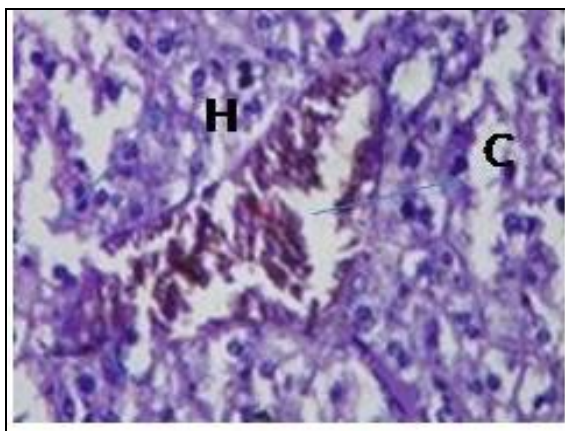


FIG.5

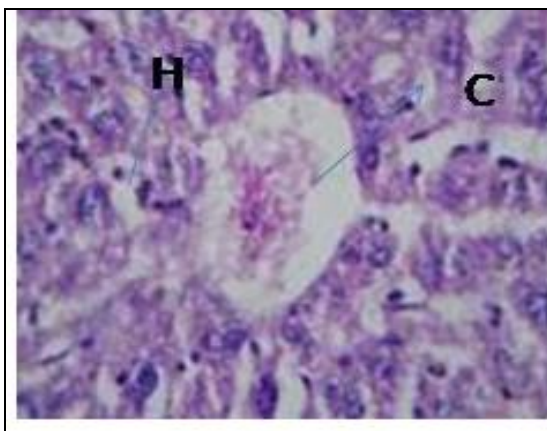


FIG.6

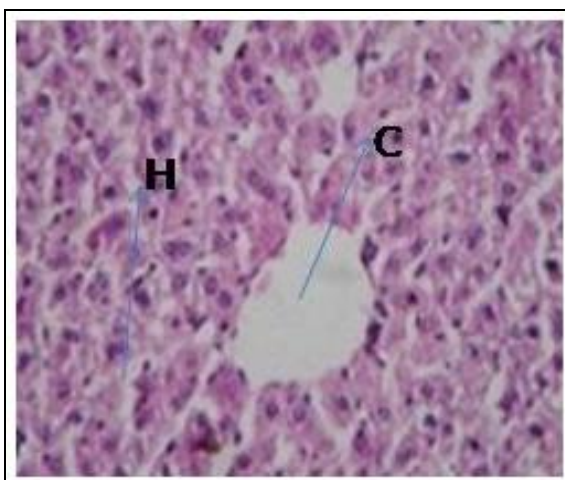


FIG.7

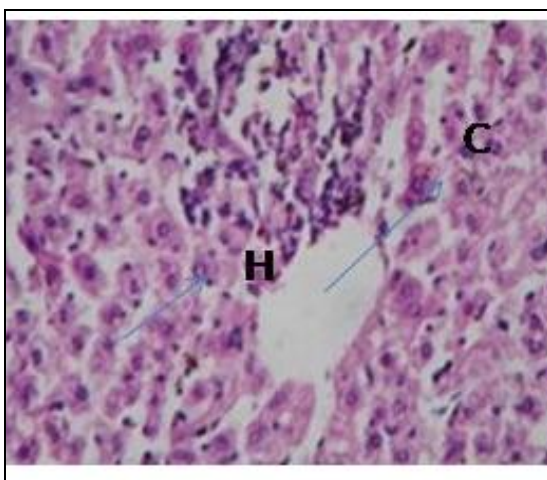


FIG.8

PHOTOMICROGRAPHS SHOWING THE LIVER OF THE EXPERIMENTAL RATS (FIG. 4 CONTROL , FIG. 5- ALLOXAN TREATED, FIG. 6 -ALLOXAN +ETHANOLIC EXTRACT OF C.S LEAF AT A DOSE 200 mg/ kg B.W. FIG. 7- ALLOXAN+ ETHANOLIC EXTRACT OF C.S LEAF AT A DOSE 400 mg/ kg B.W., FIG. 8- ALLOXAN+ METFORMIN TREATED) H- SINUSOID , C-CENTRAL VEIN.(H &E X 200)

DISCUSSION: Medicinal herbs are used widely for curing of diabetes mellitus, these herbs have

contained prominent biochemical constitute which can act as precursor of diabetes and antioxidant.

In the present investigation alloxan (150 mg/kg b.w) was used to prepare diabetic model and serum glucose level was found to be significantly higher than in normal albino rats¹¹. Alloxan is a diabetogenic agent which destructs β -cells of the islets of Langerhans and increased hyperglycemia¹².

On the other hand, treatment of ethanolic extract of *Coriandrum sativum* leaves on diabetic induced rats for four weeks, the elevated level of serum glucose were decreased. Our finding is in agreement with that of Sreelatha and Inbavalli, 2012¹³. The treatment of *Coriandrum sativum* leaves on alloxan-induced diabetic rats was found to significantly lower blood glucose levels. Such hypoglycaemic effect has also been reported in various medicinal plants¹⁴⁻¹⁷. Significantly decreased the blood glucose level in alloxan induced diabetic rats by an ethanolic extract due to decrease intestinal glucose absorption and regain extra pancreatic activity including the invigoration of peripheral glucose utilization or incitement of glycolytic glucose utilization process with concomitant decrease in glycogenesis¹⁸.

Liver plays an important role in monitoring and stabilizing glucose level so it may be considered glucostat monitor. The present results showed that injection of alloxan induces a hepatocellular damage, which is indicated by a significant increase in AST, ALT and ALP in the diabetic group as compared to control groups. Elevated level showed that AST, ALT and ALP impaired liver function¹⁹. Similarly, many scientists have reported that alloxan increased the activities of transaminases in the liver, which leads to gluconeogenesis and ketogenesis metabolism in diabetics²⁰. In addition Rangachari et al²¹., reported that these liver marker enzymes increased in plasma due to leakage from the liver cytosol into the blood stream.

However, treatment with extract for 28 days the increased serum marker enzyme levels were declining and that revealed have vital role in curing. In diabetes, glycosylated haemoglobin act as marker which help for the estimation of protein glycation in diabetes mellitus. In diabetic condition, high amount of glucose present in the blood reacts with haemoglobin to form glycosylated

haemoglobin²². In present study, level of glycosylated haemoglobin is significantly increased as compared to normal group, which is associated with high risk of retinopathy and renal complication. On the other hand, daily repeated oral administration of herbal medicine, significantly decreased the level of glycosylated haemoglobin, it may be normal hyperglycemia²³.

Our findings related to increased level of bilirubin in diabetic rats followed by subsequent decrease in its level on treatment with *Coriandrum sativum* leaves extract are consistent with the reports of other workers²⁴⁻²⁵. Further that, our results is similar to other workers whose finding with another plant²⁶⁻²⁸.

In conclusion, the present study revealed that ethanolic extract of *Coriandrum sativum* leaves significantly decline serum glucose level, anti-diabetic and shows hepatoprotective activity which has also confirmed with histopathological changes in liver tissues.

CONFLICT OF INTEREST STATEMENT: All authors have none to declare.

ACKNOWLEDGEMENT: The authors are legitimate thanks to Mr. Sunil Sharma (chancellor) and Dr. Sudhansu Sharma (chief mentor) of Suresh Gyan Vihar university, Jaipur India for valuable support for this work. Authors are also thanks Dr. Alok Mukerjee Principal of the United Institute of Pharmacy (Allahabad, India) for providing the animal housing facilities to perform the animal studies.

REFERENCES:

1. Hameed I, Masoodi SR, Mir SA, Nabi M, Ghazanfar K, Ganai BA: Type 2 diabetes mellitus: From a metabolic disorder to an inflammatory condition. *World J Diabetes*. 2015;6(4):598-612.
2. Baharvand-Ahmadi B, Bahmani M, Tajeddini P, Naghdi N, Rafieian-Kopaei M: An ethno-medicinal study of medicinal plants used for the treatment of diabetes. *J Nephropathol*. 2016;5(1):44-50
3. Mani V, Parle M, Ramasamy K, Abdul Majeed AB: Reversal of memory deficits by *Coriandrum sativum* leaves in mice. *J Sci Food Agric*. 2011; 15:91(1):186-92.
4. Laribi B, Kouki K, M'Hamdi M, Bettaieb T: *Coriander* (*Coriandrum sativum* L.) and its bioactive constituents. *Fitoterapia*. 2015;103:9-26.
5. Al-juhaimi fahad and Ghafoor Kashif: Total phenols and antioxidant activities of leaf and stem extracts from

- coriander, mint and parsley grown in Saudi Arabia. Pakistan Journal of Botany. 2011; 43(4): 2235-2237.
6. Chithra, V. Leelamma, S. Coriandrum sativum changes the levels of lipid peroxides and activity of antioxidant enzymes in experimental animals. Ind. J. Biochem. Biophys. 1999; 36: 59-61.
 7. Gray AM, Flatt PR. Insulin-releasing and insulin-like activity of the traditional anti-diabetic plant *C. sativum* (coriander). Br J Nutr. 1999;81:203-9
 8. Chithra V, Leelamma S. Hypolipidemic effect of coriander seeds (*C. sativum*): Mechanism of action. Plant Foods Hum Nutr. 1997;51:167-72
 9. Samojlik I, Lakić N, Mimica-Dukić N, Daković-Svajcer K, Bozin B. Antioxidant and hepatoprotective potential of essential oils of coriander (*Coriandrum sativum* L.) and caraway (*Carum carvi* L.) (Apiaceae). J Agric Food Chem. 2010; 11:58(15):8848-53.
 10. Herck, H. Van, V. Baumans, C.J.W. Brandt, A.P.M. Hesp, J.H. Sturkenboom, H.A. Van Lith, G. van Tintelen, and A.C. Beynen. Orbital sinus blood sampling in rats as performed by different animal technicians: The influence of technique and expertise. Laboratory Animals. 1998; 32 (4): 377-386
 11. Mona A. M. Ghoneim, Amal. Hassan, Manal G. Mahmoud and Mohsen S. Asker Effect of polysaccharide from *Bacillus subtilis* sp. on cardiovascular diseases and atherogenic indices in diabetic rats. BMC Complementary and Alternative Medicine 2016; 16:112
 12. Lenzen S. The mechanisms of alloxan- and streptozotocin-induced diabetes. *Diabetologia*. 2008; 51(2):216-26.
 13. Sreelatha S, Inbavalli R. Antioxidant, Antihyperglycemic, and Antihyperlipidemic Effects of *Coriandrum sativum* Leaf and Stem in Alloxan-Induced Diabetic Rats. J Food Sci. 2012; 77(7)
 14. Khandouzi N, Shidfar F, Rajab A, Rahideh T, Hosseini P, Mir Taheri M: The effects of ginger on fasting blood sugar, hemoglobin a1c, apolipoprotein B, apolipoprotein a-I and malondialdehyde in type 2 diabetic patients. . Iran J Pharm Res. 2015 ;14(1):131-40.
 15. Balamurugan K, Nishanthini A and Mohan VR: Antidiabetic and antihyperlipidaemic activity of ethanol extract of *Melastoma malabathricum* Lin n. leaf in alloxan induced diabetic rats. Asian Pac J Trop Biomed 2014; 4 : S442-S448
 16. Rajaei Z, Hadjzadeh MA, Moradi R, Ghorbani A and Saghebi A: Antihyperglycemic and antihyperlipidemic effects of hydroalcoholic extract of *Securigera securidaca* seeds in streptozotocin-induced diabetic rats. Adv Biomed Res. 2015; 4: 33.
 17. Asgary S, Rahimi P, Mahzouni P, Madani H :Antidiabetic effect of hydroalcoholic extract of *Carthamus tinctorius* L. in alloxan- induced diabetic rats. J Res Med Sci. 2012; 17(6): 386-92.
 18. Hua V. Lin and Domenico Accili : Hormonal Regulation of Hepatic Glucose Production In Health And Disease. Cell Metab. 2011 ;6; 14(1): 9-19.
 19. P. P. Preetha, V. Girija Devi, T: Rajamohan: Comparative effects of mature coconut water (*Cocos nucifera*) and glibenclamide on some biochemical parameters in alloxan induced diabetic rat. Revista Brasileira de Farmacognosia Brazilian Journal of Pharmacognosy. 2013; 23(3): 481-487,
 20. Baldi Ashish1, Goyal Swapnil: Hypoglycemic Effect of Polyherbal Formulation in Alloxan Induced Diabetic Rats *Pharmacologyonline*.,2011 ;3: 764-773
 21. Rangachari B, Savarimuthu I: Antidiabetic and Hypolipidemic effect of methanol extract of *Lippia nodiflora* L. in streptozotocin induced diabetic rats. Asian Pacific Journal of Tropical Biomedicine., 2011; S30-S36
 22. Alagammal M, Nishanthini A, Mohan VR: Antihyperglycemic and antihyperlipidaemic effect of *Polygala rosmarinifolia* Wright & Arn on alloxan induced diabetic rats. J Appl Pharm Sci 2012; 2: 143-148.
 23. Balamurugan, Antony N, Veerabahu RM: Antidiabetic and antihyperlipidaemic activity of ethanol extract of *Melastoma malabathricum* Linn. leaf in alloxan induced diabetic rats. Asian Pac J Trop Biomed 2014; 4: S442-S448
 24. Ikewuchi JC, Onyeike EN, Uwakwe AA, Ikewuchi CC: Effect of aqueous extract of the leaves of *Acalypha wilkesiana* 'Godseffiana' Muell Arg (Euphorbiaceae) on the hematology, plasma biochemistry and ocular indices of oxidative stress in alloxan induced diabetic rats. *J Ethnopharmacol*. 2011; 137(3):1415-24.
 25. Hossein A and Samad Z: Preventive Effects of Aqueous Extract of *Berberis integerrima* Bge. Root on Liver Injury Induced by Diabetes mellitus (Type 1) in Rat. Iranian Journal of Pharmaceutical Research 2015, 14 (1): 335-343
 26. Agarwal V, Sharma AK, Upadhyay A, Singh G, Gupta R: Hypoglycemic effects of *Citrullus colocynthis* roots. Acta Pol Pharm. 2012; 69(1):75-9.
 27. Fu J, Fu J, Yuan J, Zhang N, Gao B, Fu G, Tu Y, Zhang Y: Anti-diabetic activities of canthopanax senticosus polysaccharide (ASP) in combination with metformin. Int J Biol Macromol. 2012; 50(3):619-23.
 28. Hamden K, Allouche N, Damak M, Elfeki A: Hypoglycemic and antioxidant effects of phenolic extracts and purified hydroxytyrosol from olive mill waste in vitro and in rats. Chem Biol Interact., 2009; 180(3):421-32.

How to cite this article:

Sharma B, Joshi SC, Jasuja ND, Singh SK and Sharma G: Evaluation of anti-diabetic and hepatoprotectivity of *Coriandrum sativum* in alloxan induced experimental animals: a histopathology study. Int J Pharm Sci Res 2016; 7(11): 4510-15. doi: 10.13040/IJPSR.0975-8232.7(11).4510-15.

All © 2013 are reserved by International Journal of Pharmaceutical Sciences and Research. This Journal licensed under a Creative Commons Attribution-NonCommercial-ShareAlike 3.0 Unported License.

This article can be downloaded to **ANDROID OS** based mobile. Scan QR Code using Code/Bar Scanner from your mobile. (Scanners are available on Google Playstore)