



Received on 06 February, 2017; received in revised form, 21 April, 2017; accepted, 27 May, 2017; published 01 September, 2017

## TUBERCULOSIS OF THE BREAST - DIAGNOSIS, MANAGEMENT, AND TREATMENT

Nasib Al Shibli\*

Department of Surgery, Prince Mutaib Bin Abdulaziz Hospital, Sakaka, Aljuf Region, Saudi Arabia.

### Keywords:

Tuberculosis of the breast,  
Case presentation, Discussion,  
Conclusion

### Correspondence to Author:

**Dr. Nasib Al Shibli**

Senior Registrar in General Surgery,  
Department of Surgery, Prince  
Mutaib Bin Abdulaziz Hospital,  
Sakaka, Aljuf Region, Saudi Arabia.


**E-mail:** [nasib\\_kais@yahoo.com](mailto:nasib_kais@yahoo.com)

**ABSTRACT:** Tuberculosis is caused by *Mycobacterium tuberculosis* and affects primarily the lungs. Breast tissue is remarkably resistant to tuberculosis. This is due to fact that it gives infertile environment for survival and multiplication of tubercle bacilli like skeletal muscle and spleen. The breast may become infected by variety of ways *e.g.* haematogenous, lymphatic, spread from contiguous structures, direct inoculation and ductal infection. The path of spread of disease from lungs to breast tissue was traced *via* trachea-bronchial, Para tracheal, mediastinal lymph trunk and internal mammary nodes. Scrofulous swelling of the bosom is the description given by Sir Astley Cooper who recorded first ever Breast Tuberculosis. It is usually seen in lactating young multiparous women and presents as lump in the central or upper outer quadrant of breast. It is occasionally mistaken as Carcinoma Breast or Breast Abscess. The overall incidence of tuberculosis Mastitis is reported to be 0.1 % of all breast lesions while in developing countries it constituted approximately 3.0 % of surgically treated breast disease.

**INTRODUCTION:** Tuberculosis is caused by *Mycobacterium Tuberculosis* and affects primarily the lungs. Breast tissue is remarkably resistant to tuberculosis. This is due to fact that it gives infertile environment for survival and multiplication of tubercle bacilli like skeletal muscle and spleen<sup>1</sup>. The breast may become infected by variety of ways *e.g.* haematogenous, lymphatic, spread from contiguous structures, direct inoculation and ductal infection<sup>1</sup>. The path of spread of disease from lungs to breast tissue was traced *via* tracheobronchial, Para tracheal, mediastinal lymph trunk and internal mammary nodes<sup>2</sup>. Scrofulous swelling of the bosom is the description given by Sir Astley Cooper who recorded first ever Breast Tuberculosis<sup>3</sup>.

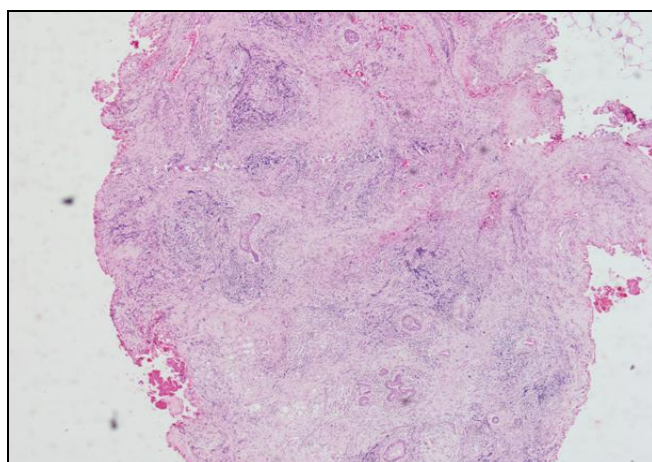
It is usually seen in lactating young multiparous women and presents as lump in the central or upper outer quadrant of breast<sup>4, 5</sup>. It is occasionally mistaken as Carcinoma Breast or Breast Abscess<sup>6, 7</sup>. The overall incidence of tuberculosis Mastitis is reported to be 0.1 % of all breast lesions while in developing countries it constituted approximately 3.0 % of surgically treated breast disease<sup>8</sup>.

**Case Presentation:** 42 years old Afghani, female patient recently arrived to Saudi Arabia presented to Surgical OPD (outpatient department) with palpable painful lump left breast since three months, with history of lactation since 4 months. Physical examination confirmed a palpable hemispherical lump of about 4 × 4 cm with no overlying skin changes located in upper outer quadrant of left breast. There were no clinical manifestations of the disease in nipple-areola area, or signs of nipple discharge, there were neither redness nor sinuses in overlying skin of the mass. Patient was afebrile. Laboratory Work-up revealed ESR 42 mm/1<sup>st</sup> hour, PPD test was positive, Hb=12 gm/dl, other lap chemistry were WNL.

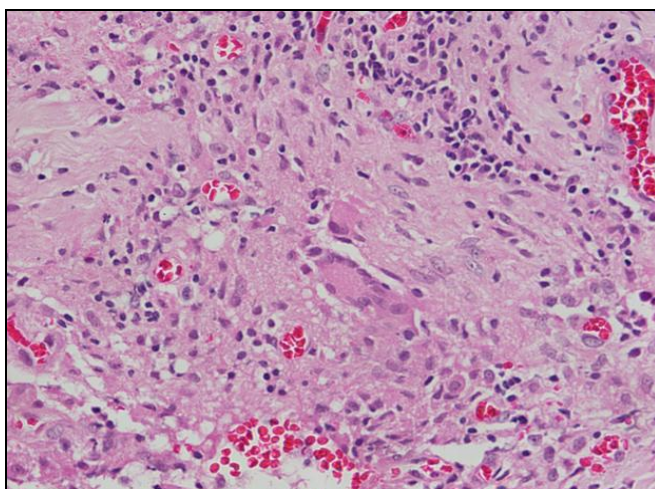
<p><b>QUICK RESPONSE CODE</b></p> 	<p><b>DOI:</b> 10.13040/IJPSR.0975-8232.8(9).3962-65</p> <p>Article can be accessed online on: <a href="http://www.ijpsr.com">www.ijpsr.com</a></p> <p>DOI link: <a href="http://dx.doi.org/10.13040/IJPSR.0975-8232.8(9).3962-65">http://dx.doi.org/10.13040/IJPSR.0975-8232.8(9).3962-65</a></p>
---	--

Aspiration yielded frank pus and Ultrasound suggested well-defined lymphochoic mass, multi-loculated in upper half of left breast, Mammography not done as pt refused, CXR was normal. Incision and drainage was done and pus sent for culture and sensitivity and AFB which finally proved negative for growth. Biopsy of wall abscess taken at the time of drainage for histopathology to rule out any malignancy. Wound kept open and left for daily dressing for 2 weeks However, no healing, no improvement seen and discharge continued.

Histopathology showed multinucleated langhans; Giant cells and prominent foamy macrophage, no malignancy seen; suggested granulomatous mastitis with abscess formation and tuberculosis of breast.



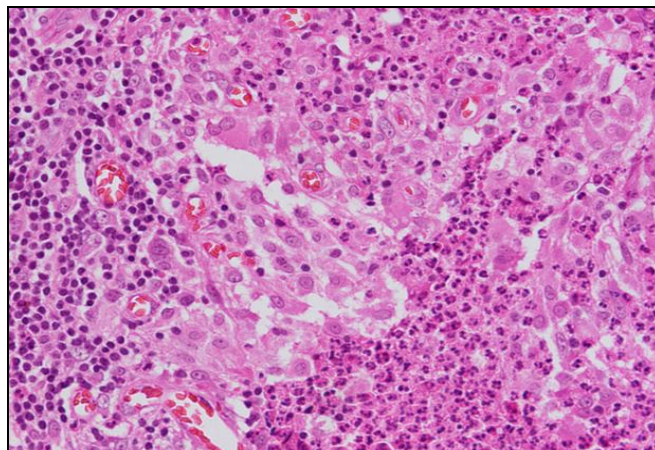
**FIG. 1: INFLAMMATION IN AND AROUND BREAST LOBULES EXTENDING INTO INTERLOBULAR TISSUE**



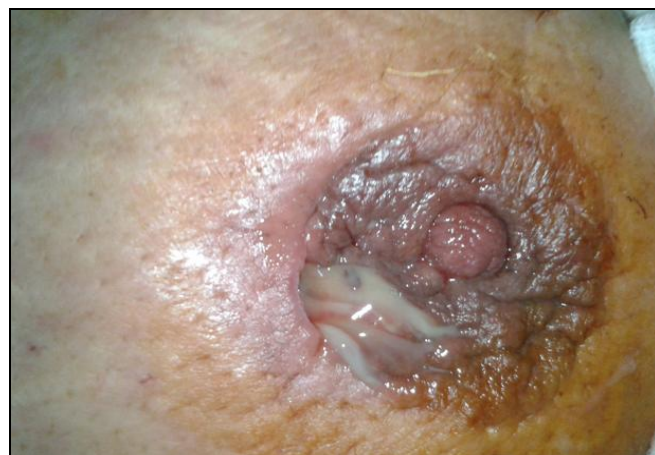**FIG. 2: GRANULOMA WITH MULTI-NUCLEATED (LANGHANS) GIANT CELL**

Patient was started with 4 drugs Anti-Tuberculosis treatment Isoniazid, Rifampicin, Pyrazinamide and

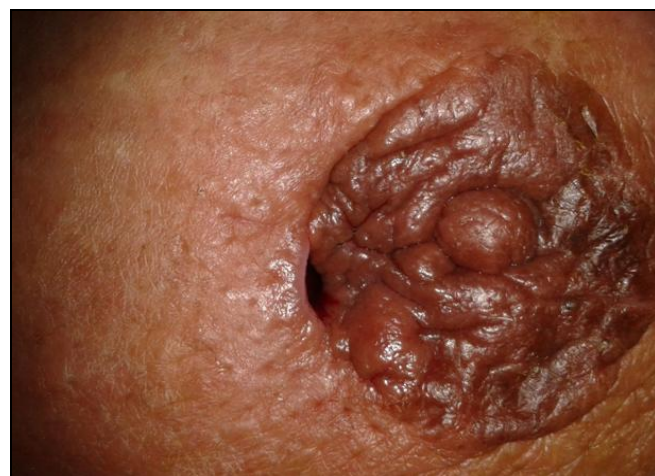Ethambutol, along with local wound care daily. After 3 weeks, discharge started reducing and stopped at 4 weeks of start of treatment. Now patient is on anti TB drugs and breast lesion completely resolved after 6 weeks of therapy and is with follow-up on OPD basis.



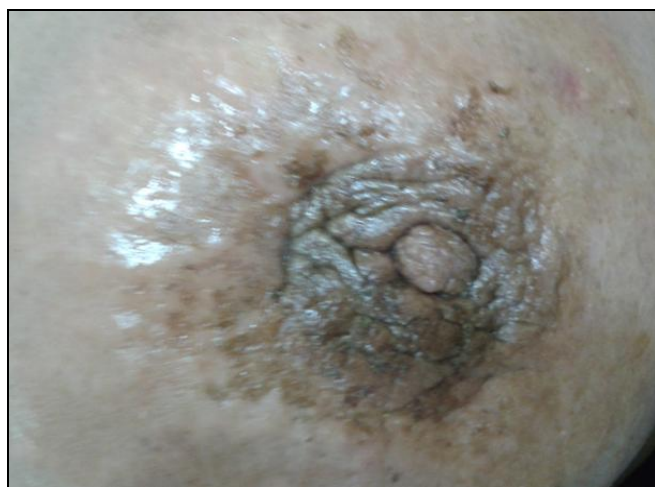**FIG. 3: CHRONIC INFLAMMATION WITH MICRO ABSCESES**



**FIG. 4: AFTER 13 DAYS FROM I AND D, CASEATING PUS**



**FIG. 5: AFTER 3 WEEKS TREATMENT OF ATB DRUGS**



**FIG. 6: COMPLETE HEALING**

**DISCUSSION:** Tuberculosis of the breast comprises 3% of surgically treatable breast condition in India, and uncommon in western population<sup>8</sup>, actually Afghanistan is considered as high incidence country with rate greater than 40 per 100,000 in 2013 estimated rate was 189 to 100,000 populations.

Tuberculosis of breast is a rare disease mostly because organs or tissues like the breast, skeletal muscle and spleen are more resistant to infection, making the survival and multiplication of tubercle bacilli difficult<sup>9, 10</sup>. Because of increased blood supply to breasts and dilated ducts in lactating women, they are at higher risk and more vulnerable to infection<sup>5</sup>.

There are three clinical varieties of mammary tuberculosis; nodular, disseminating and sclerosing<sup>11</sup>. Tuberculosis mastitis is mostly unilateral and rare in male patients however, an immunodeficiency state like HIV increase the risk<sup>6</sup>, patients has non-reactive to HIV screening. The commonest presentation is that of lump, painful or not and most often located in central or upper outer quadrant of the breast<sup>12, 13</sup> as it is seen in our patient.

Various tests are useful in diagnosis and evaluation of patient. Mantoux test does not help much for definitive diagnosis. At Ultrasonography; hypo echic mass may be seen in 60% of patients and one may identify fistula or sinus tract in cases of tuberculosis mastitis<sup>9-13</sup>.

Computerized tomography or MR may help to extension of disease beyond breast and gold

standard for diagnosis of breast tuberculosis in detection of mastitis tuberculosis on Z. N. staining or by culture<sup>9</sup> but they have own limitations like false negative results, but CT scan and MRI not done. Finally, histopathology of lesion identifies granulomatous inflammation with Caseation, necrosis and langhan's giant cells and it contributed to diagnosis in majority of cases.

The differential diagnosis is cancer breast, fat necrosis, plasma cell, mastitis, idiopathic granulomatous mastitis and infections like actinomycosis<sup>4, 9, 15, 16</sup>. Medical treatment of TB breast generally is similar to that used in active pulmonary tuberculosis, consisting of four drug therapy of INH, RIFA, pyrazinamide and Ethambutol for the initial 2 months of treatment and completed by 4 months of only INH and RIFA. Surgical intervention is reserved for drainage /aspiration of abscess, removal of residual sinuses and masses<sup>17</sup>. In refractory case, simple mastectomy may be considered.

**CONCLUSION:** Extra pulmonary tuberculosis occurring in breast is rare. It is often mistaken for cancer or pyogenic breast abscess because of nuclear clinical features. High index of suspicion is required, as radiological and microbiological tool often unyielding. Tissue diagnosis is helping to treat tuberculosis breast in surgical practice. Anti-TB drugs play vital role for cure of disease and surgery has its role to drain abscesses, take tissue for diagnosis and simple mastectomy in refractory cases which are rare.

**ACKNOWLEDGEMENT:** Nil.

**CONFLICT OF INTEREST:** None declared.

#### REFERENCES:

1. Mukerjee P, George M, Maheshwari HB and Rao CP: Tuberculosis of the Breast. J Indian Med Assoc 1974; 62: 410-2.
2. Mckeown KC and Wilkinson KW: Tuberculosis Disease of the breast. Br J Surg 1952; 39: 420.
3. Cooper A: Illustrations of the diseases of the breast. Longman, Rees, Orme, Brown and Green, London 1829.
4. Luh SP, Chang KJ, Cheng JH, Hsu JD and Huang CS: Surgical treatment for primary mammary tube – report of three octogenarian cases and review of literature. Breast Journal 2008; 14: 311-312.
5. Maroulis I, Spyropoulos C, Zolotaand V and Tzorakoleftheerakis E: Mammary tuberculosis mimicking breast .Case report. Journal of Medicine case reports. 2008; 2: 34.

6. Mirsaedi SM, Mansouri SD and Velayati AA: Tuberculosis of the breast: report of 4 clinics; and literature review. *East Mediterranean Health Journal* 2007; 13: 670-676,
7. Sriram K and Moffatt D: Tuberculosis infection of the breast mistaken for granulomatous mastitis, a case report. *Cases Journal* 2008; 1: 273.
8. Hamit HF and Ragsdale TH: Mammary tuberculosis. *J R Soc Med* 1982; 75: 764.
9. Da Silva BB, Lopes-Costa PV, Pires CG, Pereira-Filho JD and Dos Santos AR: Tuberculosis of the breast analysis of 20 cases and a literature review. *Transactions of the Royal Society of Tropical Medicine and Hygiene* 103: 559-563.
10. Madhusudhan KS and Gammanagatti S: Primary breast tuberculosis masquerading as carcinoma. *Singapore, Medical Journal* 2008; 49: e3-e5.
11. Goksoy E, Duren M and Durgun V: Tuberculosis of the breast. *Eur J Surg* 1995; 161: 471-3.
12. Jah A, Mulla R, Lawrence FD, Pittam M and Ravichandran D: Tuberculosis of the breast: experience of breast clinic serving na ethnically diverse population. *Annals of the Royal College of Surgeons of England* 20: 416-419.
13. Teo TH and Chaturverdi BK: Tuberculosis of the chest wall: unusual presentation as: lump. *Singapore Medical Journal* 2009; 50: e97-e99.
14. Akcay MN, Saglam L, Polat P, Erdogan F, Albayrak Y and Povoski SP: Mammary tuberculosis- recognition and differentiation from that of a breast malignancy: report of three cases and review of the Lit. *World Journal of Surgery and Oncology* 2007; 5: 67.
15. Da Silva BB, Dos Santos LG, Costa PV and Borges AS: Primary tuberculosis of the breast mimicking carcinoma. *American Journal of Tropical Medicine and Hygiene* 2005; 73: 975-976.
16. Del Agua C, Felipo J, Equizabal C and Delgado M: Tuberculosis of the breast as a pseudotum image. *Breast Journal* 2006; 12: 180.
17. Romero C, Carreira C and Cereceda C: Mammary tuberculosis: percutaneous treatment of mammary tuberculosis abscess. *EuR Radiol* 2000; 10: 531-3.

**How to cite this article:**

Al-shibli N: Tuberculosis of the breast - diagnosis, management, and treatment. *Int J Pharm Sci Res* 2017; 8(9): 3962-65.doi: 10.13040/IJPSR.0975-8232.8(9).3962-65.

All © 2013 are reserved by International Journal of Pharmaceutical Sciences and Research. This Journal licensed under a Creative Commons Attribution-NonCommercial-ShareAlike 3.0 Unported License.

This article can be downloaded to **ANDROID OS** based mobile. Scan QR Code using Code/Bar Scanner from your mobile. (Scanners are available on Google Playstore)