



Received on 26 February, 2017; received in revised form, 25 April, 2017; accepted, 03 May, 2017; published 01 October, 2017

HEPATOPROTECTIVE ACTIVITY OF AQUEOUS EXTRACT OF *PYRUS PASHIA* BUCH.-HAM. EX D. DON AGAINST CCl₄ INDUCED LIVER DAMAGE

Rojini Athokpam, Meenakshi Bawari* and Manabendra Dutta Choudhury

Department of Life Science and Bioinformatics, Assam University, Silchar - 788011, Assam, India.

Keywords:

Pyrus pashia,
Silymarin, CCl₄, Liver

Correspondence to Author: Dr. Meenakshi Bawari

Associate Professor,
Department of Life Science
and Bioinformatics, Assam
University, Silchar - 788011,
Assam, India.


E-mail: rojiniath@gmail.com

ABSTRACT: The study was to evaluate the hepatoprotective activity of aqueous extract of *Pyrus pashia* Buch.-Ham. ex D. Don against carbon tetrachloride-induced hepatotoxicity in mice. Hepatotoxicity was induced by CCl₄ 30% in olive oil (1ml/kg i.p.). Mice were treated with aqueous extract of *P. pashia* at doses of 250 and 500 mg/kg b.wt. orally for 14 days. There were two group pre-treatment (once daily for 14 days before CCl₄ intoxication) and post-treatment (2, 6, 24 and 48 hr after CCl₄ intoxication) groups. The observed effects were compared with a known hepatoprotective agent, silymarin. Pre-treatment and post-treatment groups of aqueous extract of *P. pashia* significantly reduced elevated serum levels of serum transaminases, alkaline phosphatase, and bilirubin and increased the level of total protein as compared to CCl₄ treated group. The histopathological study also confirms the hepatoprotection. Preliminary qualitative phytochemical analysis of the plant revealed the presence of carbohydrates, phenolic compounds, tannins, and saponins. The data are expressed as \pm S.E.M. one-way analysis of variance (ANOVA) followed by multiple comparisons with the Tukey post hoc test to compare different parameters between the groups.

INTRODUCTION: Liver is an important target organ for toxicity produced by drugs, xenobiotics and oxidative stress because of its unique metabolism. All over the world liver disorders have become serious health problem and a cause of morbidity and mortality due to limited prevention and treatment options¹. For the prevention of liver injury, a growing interest has emerged around the globe in rediscovering medicinal plants. To stimulate liver function and offer protection, many folk remedies of plant origin have been tested for their hepatoprotective activity².

In developing countries, herbal medicine is considered to be of great importance among different rural and indigenous communities and the therapeutic value of medicinal plants has been exploited for the management of various disease conditions. Herbal medicines have gained more attention and popularity because of their safety and efficacy³.

In recent years, due to the absence of efficient hepatoprotective drugs in modern medicine, a large number of studies have been done searching for hepatoprotective constituents from natural products and herbal medicines⁴. *Pyrus pashia* Buch.-Ham. ex D. Don (Rosaceae) is distributed in the forest of Himalayan region from North East India to Hindu Kush mountain. It is a medium size deciduous tree commonly known as wild pear. The plant has both nutritional and therapeutic importance, it possesses

QUICK RESPONSE CODE 	DOI: 10.13040/IJPSR.0975-8232.8(10).4195-00
	Article can be accessed online on: www.ijpsr.com
DOI link: http://dx.doi.org/10.13040/IJPSR.0975-8232.8(10).4195-00	

antimicrobial activities and is effective against *Klebsiella pneumonia*, *Shigella flexneri* and *Escherichia coli* ⁵. It is used as laxative and sedative. Fruits are used for the treatment of dehydration and various other ailments like gastrointestinal disorder, fever, headache, hysteria and epilepsy ⁶. The fruit juice is astringent and diuretic and is used to treat leishmaniasis, sore throat, abdominal pain, anemia and also used in the improvement of spleen. It also exhibited spasmolytic bronchodilator ⁷. *P. pashia* is used for treating jaundice and liver disorders as per the ethnobotanical knowledge obtained from local herbal practitioners, though literature regarding the effect and use of this plant for treating liver diseases are not available.

In the present study, we aimed to determine the hepatoprotective activity of aqueous extract of *Pyrus pashia* Buch.-Ham. ex D. Don in CCl₄ induced hepatotoxicity.

MATERIALS AND METHODS:

Plant Collection and Authentication: The aerial parts of *P. pashia* were collected from a village called Heingang, Imphal East district, Manipur, India. The plant material was identified and authenticated by Dr. S. K. Singh, Scientist-D, Botanical Survey of India (BSI), Eastern Regional Centre, Shillong, India.

Preparation of Extracts: The plant parts were shade dried, powdered with a mechanical grinder and passed through a sieve and were extracted with distilled water in the ratio of 1:10 w/v. The extract thus obtained was concentrated and dried in a vacuum desiccator. The aqueous extract of *P. pashia* was prepared fresh each time after triturating with distilled water immediately before the administration.

Preliminary Phytochemical Screening: Crude aqueous extract was subjected to preliminary qualitative phytochemical analysis to test for the presence of various chemical constituents such as alkaloids, carbohydrates, glycosides, saponins, proteins, amino acids, phytosterols, fixed oils, fats, phenolic compounds and flavonoids ⁸⁻¹⁵.

Experimental Animals: The Swiss albino male mice, 8-12 weeks old (weighing between 22-28 gm) were procured from Pasteur Institute, Shillong,

Meghalaya. The animals were housed in large, clean polypropylene cages in a temperature-controlled room (27 ± 3 °C) with 12 hr light and dark cycle, free access to water *ad libitum* and fed with standard pellet diet. All the experiments and protocols described in the present study were approved by the Institutional Ethical Committee (IEC) of Assam University, Silchar, (Reg. No. IEC/AUS/2013-045 dt-20/3/13).

Dose Selection: Dosage of the extract was determined after toxicity test (LD₅₀) median lethal dose described by Lorke ¹⁶. The 250mg/kg b. wt and 500mg/kg b. wt were taken as the low and medium doses.

Experimental Design: The experiment was designed following the method of Vuda *et al.*, ¹⁷. The mice were divided into eight groups of six mice each group. Group I served as a normal control for both pre-treatment and post-treatment and received distilled water orally for 14 days. Group II served as a toxic control and received distilled water orally for 14 days and on the 14th day they received 30% CCl₄ in olive oil (1ml/kg b. wt, i.p.). Group III and IV served as pre-treatment groups. They received an aqueous extract of *P. pashia* orally at a dose of 250 and 500mg/kg b. wt. for 14 days respectively, and on the 14th day, they received 30% CCl₄ in olive oil (1ml/kg b. wt, i.p.), 2 hr after administration of the last dose of the plant extract. Group V served as the standard for the pre-treatment group and they received standard drug silymarin 100mg/kg b. wt. orally for 14 days and on the 14th day they received 30% CCl₄ in olive oil (1ml/kg b. wt, i.p.), 2 hr after administration of the last dose of silymarin.

Group VI and VII served as post-treatment groups. They received distilled water orally for 14 days and on the 14th day received 30% CCl₄ in olive oil (1ml/kg b. wt, i.p.) followed by the aqueous extract of *P. pashia* orally at a dose of 250 and 500mg/kg b. wt. respectively at 2, 6, 24 and 48 hr after CCl₄ intoxication. Group VIII served as the standard for the post-treatment group and received distilled water orally for 14 days and on the 14th day received 30% CCl₄ in olive oil (1ml/kg b. wt, i.p.) followed by silymarin 100mg/kg b. wt. orally at 2, 6, 24 and 48 hr after CCl₄ intoxication. All the mice were sacrificed 50 hr after CCl₄ intoxication and

blood was collected and allowed to clot for 45 min at room temperature. Serum was separated by centrifugation at 2500 rpm for 15 min and used for biochemical estimations.

Measurement of Serum Biochemical Parameters: The activities of serum aspartate transaminase (AST), alanine transaminase (ALT), alkaline phosphatase (ALP), total bilirubin (TB), direct bilirubin (DB) and total protein (TP) were estimated with the standard methods¹⁸⁻²¹.

Histopathology: The liver was collected and fixed in 10% formalin, cleared in xylene and embedded in paraffin. Section of 4-5µm thickness was prepared and stained with haematoxylin and eosin (H-E) dye and observed under a microscope to examine histopathological changes in the liver.

Hepatoprotective Activity: Hepatoprotective activity (H) expressed as a hepatoprotective percentage was calculated according to the formula of Gad²².

$$H = \left\{ 1 - \frac{T-V}{C-V} \right\} \times 100$$

Where “T” is the mean value of plant extract and CCl₄, “C” is the mean value of CCl₄ alone and “V” is the mean value of control treated animals.

Statistical Analysis: The data are expressed as ± S.E.M. one-way analysis of variance (ANOVA) followed by multiple comparisons with the Tukey post hoc test to compare different parameters between the groups. Statistical analysis was performed using the SPSS statistical software package, version 21.0 for windows. The results were considered to be statistically significant at *p* value <0.05.

RESULTS: The qualitative phytochemical analysis of an aqueous extract of *P. pashia* showed the presence of carbohydrates, flavonoids, saponins, phenolic compounds and tannins. The effects of aqueous extract of *P. pashia* on serum biochemical parameters in CCl₄ intoxicated mice are shown in **Table 1**.

Mice of the toxic control (Group II) showed a significant increase in the levels of serum AST, ALT, ALP, bilirubin (total and direct) but decreased in TP levels compared to normal control

(Group I) reflecting the liver injury due to the toxic effect of CCl₄. The pre-treatment (Group III and IV) and the post-treatment (Group VI and VII) groups of both the doses 250 and 500mg/kg of *P. pashia* aqueous extract showed significant hepatoprotection in serum AST, ALT, ALP, bilirubin (total and direct) and TP levels compared to the toxic control group (Group II). The percentage protections were 15.26%, 14.49%, 34.47%, 32.86% and 37.45% respectively for AST, ALT, ALP, bilirubin respectively for Group III. Group IV percentage protections were 19.96%, 17.00%, 35.36%, 37.20% and 38.30% respectively. Groups VI percentage protection for serum levels AST, ALT, ALP and bilirubins were 22.51%, 21.57%, 35.84%, 38.30% and 38.39% respectively. The percentage protections offered by Group VII were 25.91%, 24.02%, 36.16%, 39.22% and 39.51% respectively.

The serum protein level of all the groups except the toxic control (Group II) showed no significant when compared with the normal control (Group I). The serum biochemical parameters were measured toward normalization in both the groups of pre- and post-treatment. The percentage protection offered by the silymarin (Group V) in AST, ALT, ALP and bilirubin levels were 37.37%, 37.47%, 41.32%, 42.98% and 42.66% respectively for the pre-treatment group. For post-treatment (Group VIII) the percentage protection were 43.74%, 40.94%, 47.30%, 46.87% and 44.50% respectively. The percentage protection of the groups at different serum levels and the overall percentage protection are shown in **Fig. 1** and **Fig. 2**.

Similar results were obtained supported by the histopathological study (**Fig. 2**). The normal control group showed cells with distinct hepatic cells and sinusoidal spaces (Gr. I). Liver sections of the toxic control group treated with CCl₄ showed disarrangement and degeneration of hepatocytes with intense centrilobular necrosis and vacuolization (Gr. II). In the group of animals treated with the aqueous extract of *P. pashia* at doses 250mg/kg and 500mg/kg in both the pre-treatment and post-treatment groups showed portal vein congestion, less disarrangement and degeneration of hepatocytes with less vacuolization and an absence of necrosis (Group III, IV, VI and VII). The liver sections of the silymarin treated

group at a dose 100mg/kg in both the treatment groups showed a cell damage protection (Group V and VIII). These histopathological studies

confirmed the hepatoprotective effect of aqueous extract of *P. pashia* against CCl₄ induced hepatotoxicity.

TABLE 1: EFFECTS OF AQUEOUS EXTRACT OF *PYRUS PASHIA* ON SERUM BIOCHEMICAL PARAMETERS IN CCl₄ IN TOXICATED MICE (PRE-TREATMENT AND POST-TREATMENT GROUPS)

Group	Treatment	AST (U/ml)	ALT (U/ml)	ALP (KA Units)	TB (mg/dl)	DB (mg/dl)	TP (g/dl)
Group I	Control	32.25±2.18	17.91±1.07	6.77±0.50	0.35±0.05	0.11±0.003	6.29±0.18
Group II	CCl ₄	125.33±5.3 ^{###}	157.33±8.75 ^{###}	29.67±2.23 ^{###}	1.25±0.16 ^{###}	1.085±0.18 ^{###}	4.58±0.33 ^{##}
Group III	PP 250mg/kg+CCl ₄	96.91±2.95 ^{**}	116.91±5.71 ^{**}	13.88±1.07 ^{**}	0.66±0.05 ^{**}	0.35±0.01 ^{**}	6.08±0.18 [*]
Group IV	PP 500mg/kg+CCl ₄	88.16±4.17 ^{**}	109.91±4.66 ^{**}	13.47±1.58 ^{**}	0.58±0.03 ^{**}	0.34±0.01 ^{**}	6.13±0.22 [*]
Group V	Silymarin 100mg/kg+CCl ₄	55.75±3.59 ^{**}	52.83±2.60 ^{**}	10.74±0.47 ^{**}	0.47±0.02 ^{**}	0.25±0.01 ^{**}	6.76±0.32 [*]
Group VI	CCl ₄ +PP 250mg/kg	83.41±3.47 ^{**}	97.16±3.58 ^{**}	13.25±1.09 ^{**}	0.56±0.05 ^{**}	0.32±0.02 ^{**}	6.39±0.57 ^{**}
Group VII	CCl ₄ +PP 500mg/kg+CCl ₄	77.08±4.05 ^{**}	90.33±4.63 ^{**}	13.11±1.41 ^{**}	0.54±0.02 ^{**}	0.31±0.01 ^{**}	6.50±0.38 ^{**}
Group VIII	CCl ₄ +Silymarin 100mg/kg	44.08±2.80 ^{**}	43.16±2.85 ^{**}	8.005±0.69 ^{**}	0.40±0.01 ^{**}	0.22±0.004 ^{**}	7.26±0.45 ^{**}

PP: *Pyrus pashia* Buch.-Ham. ex D. Don. Values are expressed as mean ± SEM (n = 6)

Data were analysed by one-way ANOVA followed by Tukey post hoc test.

$p < 0.05$, ## $p < 0.01$, ### $p < 0.001$ vs. normal control (Group I).

* $p < 0.05$, ** $p < 0.01$, *** $p < 0.001$ vs. toxic control group (Group II).

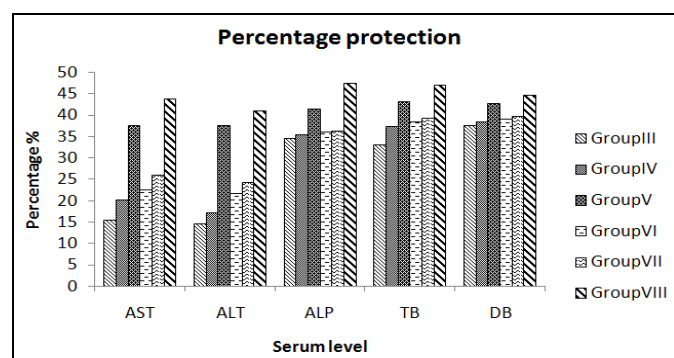


FIG. 1: PERCENTAGE PROTECTION PRODUCED BY THE AQUEOUS EXTRACT OF *P. PASHIA* AT DIFFERENT SERUM LEVELS

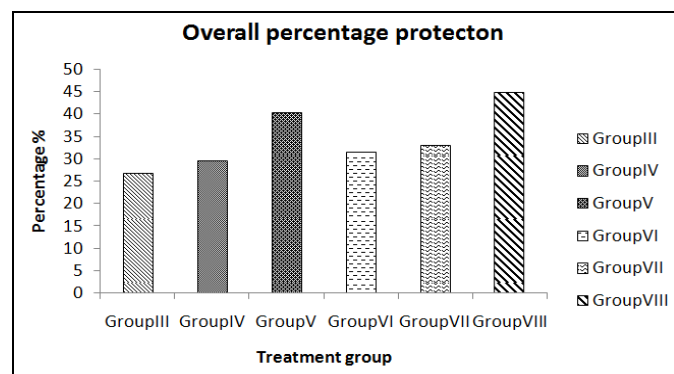


FIG. 2: OVERALL PERCENTAGE PROTECTION

Group VIII (44.65%) exhibited maximum efficacy in all parameters (AST, ALT, ALP, TB, DB) with overall hepatoprotection followed by Group V (40.36%), Group VII (32.96%), Group VI (31.44%), Group IV (29.56%), and Group III (26.91%).

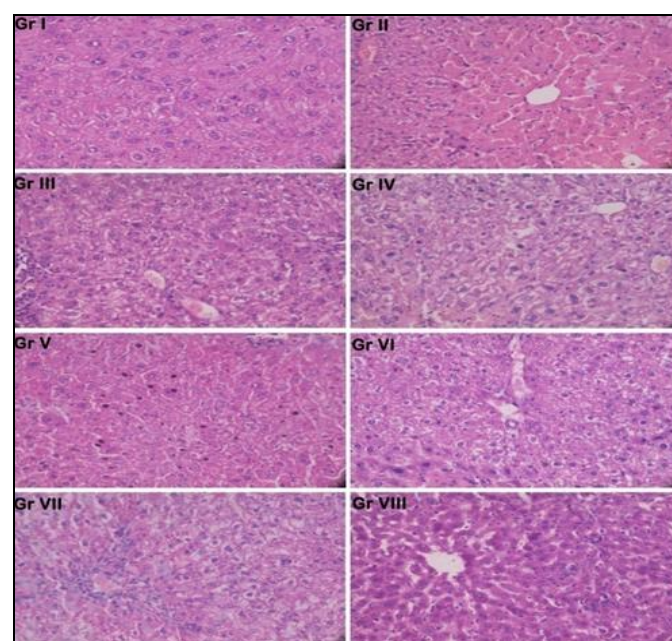


FIG. 3: EFFECTS OF *P. PASHIA* ON THE LIVER HISTOPATHOLOGICAL PHOTOMICROGRAPHS OF THE EXPERIMENTAL GROUPS OF MICE

The liver sections from the normal control animals (Group I) showed cells with distinct hepatic cells and sinusoidal spaces. The toxic control animals group (Group II) showed disarrangement of hepatocytes with intense necrosis and vacuolization. The pre- and post- treatment groups at 250mg/kg and 500mg/kg and silymarin at 100mg/kg (Group III - VIII) showed portal vein congestion, less disarrangement and degeneration of hepatocytes and also the absence of necrosis.

DISCUSSION: A large number of people especially the rural people depend on natural resources for their survival. The study of cultural uses of medicinal plant species is significant to contemporary medicine. Liver is responsible for detoxification of chemicals and drugs. This makes it the target organ for all toxic chemicals because of its vital and unique functions. Any injury or impairments of its function may lead to several implications on health. CCl_4 is the most common and extensively used hepatotoxin in the experimental study of liver diseases. Administration of CCl_4 causes acute liver damage that mimics the damage done to the liver due to natural causes. CCl_4 is bio transformed by cytochrome P_{450} to free radicals (trichloromethyl, $\text{Cl}_3\text{C}-\text{CCl}_3$ (hexachloroethane), COCl_2 (phosgene) which are to known to involve in the pathogenesis of liver.

This result in the necrosis of liver due to peroxidation of lipids, covalent binding of macromolecules, disruption of metabolic mechanisms in mitochondria, decrease in the levels of phospholipids, increase in triglycerides levels, inhibition of calcium pumps of microsomes²³. The results of the present study revealed that acute toxicity study (LD_{50}) of the aqueous extract of *P. pashia* was greater than 5000mg/kg implying that the extract was relatively safe²⁴.

The increase in the serum ALT and AST levels by CCl_4 is attributed to the hepatic structural damage because these enzymes are normally localized to the cytoplasm and released into the circulation after the cellular damage has occurred²⁵. The serum AST and ALT levels significantly decreased in the pre- and post-treatment groups of aqueous extract of *P. pashia* suggesting that it effectively ameliorates the hepatotoxicity induced by CCl_4 . Reduction in the AST and ALT levels indicates the stabilization of plasma membrane and restoration of hepatic tissue damages caused by CCl_4 .

Hepatic injury induced by CCl_4 results in the elevation of ALP and bilirubin levels which could reflect a pathological alteration in the biliary flow²⁶. *P. pashia* treated groups reduced the level of serum ALP with the concurrent depletion of bilirubin level suggesting that the extract was able to stabilize biliary dysfunction induced by CCl_4 .

The reduction in the level of total protein is attributed to the produced damage and is localized in the endoplasmic reticulum resulting in the loss of P_{450} leading to its functional failure. This leads to decrease in protein synthesis and accumulation of triglycerides²⁷. The present study demonstrates a decrease in serum protein levels in the CCl_4 treated group but increase in the *P. pashia* treated groups suggesting the stabilization of endoplasmic reticulum leading to protein synthesis. The aqueous extract of *P. pashia* possesses various phytochemicals including flavonoids, saponins, tannins and a polyphenolic compound which are natural antioxidants and can scavenge free radicals. So, the presence of these components may be attributed to the hepato-protective activity in the plant²⁸.

The extent of hepatic damage was also assessed by histological evaluation along with the level of various biochemical parameters. The slides of the liver of only toxic control mice group showed more extensive cell damage. Slides of the liver of mice treated with the plant extract showed the restoration of damage due to necrosis and inflammation and these were comparable with the reference drug slide indicating its possible anti-hepatotoxic action.

CONCLUSION: In the present study, aqueous extract of *P. pashia* restored the elevated serum enzyme levels suggesting that it has hepato-protective capacities in CCl_4 intoxicated mice. The protective effect observed could be attributed to the presence of various phytochemicals which are responsible for the restoration of liver damage. Further studies are required to identify and characterize the active principle responsible for the hepatoprotective activity of the plant.

ACKNOWLEDGEMENT: We express our sincere thanks to Silchar Medical College and Hospital, Silchar for the help and advice in histopathological examination. We are also thankful to the Biotech Hub, Department of Life Science and Bioinformatics, Assam University, Silchar for the photomicrograph. A special acknowledgment is owed to the Director, Botanical Survey of India, Shillong for identification of the plant *Pyrus pashia* Buch.-Ham. ex D. Don.

FINANCIAL SUPPORT AND SPONSORSHIP:
UGC Non-NET Fellowship.

CONFLICTS OF INTEREST: There are no conflicts of interest.

REFERENCES:

- Joshi BC, Prakash A and Kalia AN: Hepatoprotective potential of antioxidant potent fraction from *Urtica dioica* Linn. (whole plant) in CCl₄ challenged rats. *Toxicology Reports* 2015; 2: 1101-10.
- Agarwal G, Pant AK and Hore SK: The Hepatoprotective Effect of The Polyphenolic Compounds in the roots of *Trichilia comaroides* Wight and Arn. *Hygeia Journal of Drugs and Medicines* 2010; 2: 22-31.
- Sharma J, Gairola S, Gaur RD and Painuli RM: The treatment of jaundice with medicinal plants in indigenous communities of the Sub-Himalayan region of Uttarakhand. *Indian Journal of Ethnopharmacology* 2012; 143: 262-91.
- Pu X, Fan W, Yu S, Li Y, Ma X, Liu L, Ren J and Zhang W: Polysaccharides from *Angelica* and *Astragalus* exert hepatoprotective effects against carbon-tetrachloride-induced intoxication in mice. *Canadian Journal of Physiology and Pharmacology* 2015; 93: 39-43.
- Tsering J, Gogoi BJ and Tag H: Ethnobotany and Phytochemical analysis of *Pyrus pashia* Leaves. *International Journal of Pharmaceutical Sciences and Research* 2012; 3: 2721-5.
- Siddiqui SZ, Saima A, Rehman A, Rubab K, Abbasi MA, Ajaib M and Rasool ZG: *Pyrus pashia*: A persuasive source of natural antioxidants. *Pakistan Journal of Pharmaceutical Sciences* 2015; 28: 1763-72.
- Janbaz KH, Ahsan MZ, Saqib F, Imran I, Zia-Ul-Haq M, Rashid MA, Jaafar HJE, and Moga M: Scientific basis for use of *Pyrus pashia* Buch.-Ham. ex D. Don. fruit in gastrointestinal, respiratory and cardiovascular ailments. *PLoS One* 2015; 10: 1-14.
- Evans WC: Trease and Evans Pharmacognosy. Harcourt Brace and Company, Fourteenth Edition 1997.
- Ramakrishnan S and Rajan R: Textbook of Medical Biochemistry. Orient Longman, Second Edition 1994.
- Kokate CK: Practical Pharmacognosy. Vallabh Prakashan Publication, Fourth Edition 1999.
- Fisher DB: Protein staining of ribboned epon sections for light microscopy. *Histochemie*. 1968; 16: 92-6.
- Ruthman AC: Methods in Cell Research. Ithaca, New York: Cornell University Press, 1970.
- Gahan PB: Plant Histochemistry and Cytochemistry: An Introduction. Academic Press, U.S.A, 1984.
- Finar IL: Stereo Chemistry and the Chemistry of Natural Products. Longman, 1986; 2.
- Mace ME: Histochemical Localization of Phenols in Healthy and Diseased Banana Roots. *Physiologia Plantarum* 1963; 16: 915-25.
- Lorke D: A new approach to practical acute toxicity testing. *Archive of Toxicology* 1983; 54: 275-87.
- Vuda M, D'Souza R, Upadhya S, Kumar V, Rao N, Kumar V, Rao N, Kumar V, Boillat C and Mungli P: Hepatoprotective and antioxidant activity of aqueous extract of *Hybanthus enneaspermus* against CCl₄-induced liver injury in rats. *Experimental Toxicology and Pathology* 2012; 64: 855-9.
- Reitman S and Frankel S: A Colorimetric Method for the Determination of Serum Glutamic Oxaloacetic and Glutamic Pyruvic Transaminases. *American Journal of Clinical Pathology* 1957; 28: 56-63.
- Kind PRN and King EJ: Estimation of plasma phosphatase by determination of hydrolysed phenol with amino-antipyrine. *Journal of Clinical Pathology* 1954; 7: 322-6.
- Jendrassik L and Grof P: Vereinfachte photometrische Methoden Zur Bestimmung des Blutbilirubins. *Biochem Zeitschrift*. 1938; 297: 81-9.
- Gornall AG, Bardawill CJ and David MM: Determination of Serum Proteins by means of the Biuret Reaction. *Journal of Biological Chemistry* 1949; 117: 751-66.
- Gad SC: Handbook of Pharmaceutical Biotechnology. John Wiley and Sons, Inc, 2007.
- Anusha M, Venkateswarlu M, Prabhakaran V, Taj SS, Kumari BP and Ranganayakulu D: Hepatoprotective activity of aqueous extract of *Portulaca oleracea* in combination with lycopene in rats. *Indian Journal of Pharmacology* 2011; 43: 563-7.
- Horn HJ: Simplified LD₅₀ (or ED₅₀) Calculations. *Biometrics*. 1956; 12: 311-22.
- Mihailovic V, Mihailovic M, Uskokovic A, Arambasic J, Mistic D, Stankovic V, Kitani J, Mladenovic M, Solujic S and Matic S: Hepatoprotective effects of *Gentiana asclepiadea* L. extracts against carbon tetrachloride induced liver injury in rats. *Food Chemical Toxicology* 2013; 52: 83-90.
- Huang B, Ban X, He J, Zeng H, Zhang P and Wang Y: Hepatoprotective and antioxidant effects of the methanolic extract from *Halenia elliptica*. *Journal of Ethnopharmacology* 2010; 131: 276- 81.
- Sureshkumar SV and Mishra SH: Hepatoprotective effect of extracts from *Pergularia daemia* Forsk. *Journal of Ethnopharmacol* 2006; 107: 164-8.
- Aneja S, Vats M, Aggarwal S and Sardana S: Phytochemistry and hepatoprotective activity of aqueous extract of *Amaranthus tricolor* Linn. roots. *Journal of Ayurveda Integrative Medicine* 2013; 4: 211-5.

How to cite this article:

Athokpam R, Bawari M and Choudhury MD: Hepatoprotective activity of aqueous extract of *Pyrus pashia* buch.-ham. Ex d. Don against CCl₄ induced liver damage. *Int J Pharm Sci Res* 2017; 8(10): 4195-00. doi: 10.13040/IJPSR.0975-8232.8(10).4195-00.

All © 2013 are reserved by International Journal of Pharmaceutical Sciences and Research. This Journal licensed under a Creative Commons Attribution-NonCommercial-ShareAlike 3.0 Unported License.

This article can be downloaded to **ANDROID OS** based mobile. Scan QR Code using Code/Bar Scanner from your mobile. (Scanners are available on Google Playstore)