



Received on 29 December 2018; received in revised form, 07 April 2019; accepted, 19 April 2019; published 01 September 2019

TREATMENT EFFECT OF ALCUREMON PREPARATION ON ETHANOL-INDUCED NEUROTRANSMITTERS IMBALANCE AND ALCOHOLIC LIVER DISEASE IN RATS

Bat-Erdene Jargalsaikhan ^{* 1}, Narangerel Ganbaatar ¹, Saranchimeg Borchuluun ¹, Altanchimeg Adilbish ² and Chimedragchaa Chimedtseren ¹

Department of Pharmacology, Institute of Traditional Medicine and Technology ¹, Department of Pathology, Institute of Veterinary Medicine ², Ulaanbaatar, Mongolia.

Keywords:

Alcoholism, Hippocampus, Neuro-mediator, Fatty liver, *Gentiana barbata* Froel, *Carthamus tinctorius* L., *Terminalia chebula* Retz, and *Rosa acicularis* Lindl

Correspondence to Author: Bat-Erdene Jargalsaikhan

Researcher M.D, MSc,
Department of Pharmacology,
Institute of Traditional Medicine and
Technology, 17032, P.O. Box 495/36,
Ulaanbaatar, Mongolia.

E-mail: Baterdene1010@yahoo.com

ABSTRACT: Alcohol use disorders (AUDs) recognized as substantial public health problem. It is grown-up many risk factors influence on alcoholism including social, behavior, an environment, and heredity conditions on the global. Alcuremon preparation was based on medicinal herbs and used for the treatment of alcohol-related disease and alcoholic liver disease in traditional Mongolian medicine. Male Wistar rats were used to induce alcoholic liver disease and chronic ethanol (EtOH) intoxication with neurotransmitter imbalance by oral administration of ethanol (subchronic 30% EtOH 10 ml/kg/day for 14 days and chronic 40% EtOH 7 ml/kg/day for 60 days). Alcuremon 50, 100 and 150 mg/kg were given orally for the same day as ethanol administration days. Some biochemical parameters and liver HE stains were examined in subchronic intoxication with alcoholic liver disease. Chronic ethanol-induced neurotransmitters changes were measured by enzyme-linked immunosorbent assay (ELISA) in brain homogenate of nucleus accumbens (NAc) and ventral tegmental area (VTA). Hippocampus was stained with cresyl violet. Data were expressed as mean \pm SD. The difference between the groups was compared using one-way analysis of variance (ANOVA) followed by the Tukey's post hoc test. Alcoholic liver damages were significantly lower in the EtOH + Alcuremon treated groups compared with the EtOH group. The EtOH + Alcuremon treated groups had a higher neuronal cell in the hippocampal CA1 and CA3 areas, and the level of the neurotransmitters was significantly balanced compared with the EtOH group. Alcuremon preparation has hepatoprotective, neuroprotective and neuromodulator effects on ethanol intoxication in rats, probably due to the presence of polyphenolic compounds.

INTRODUCTION: Alcohol has contributed to more than 200 diseases including injury-related health conditions, alcohol dependence, liver cirrhosis, and cancers.

As shown by the Global status report on alcohol and health 2018, the harmful use of alcohol resulted in some 3 million deaths (5.3%) worldwide and 132.6 (5.1) million disability-adjusted life years (DALY) of all DALY in that year ^{1,2}.

In 2013 from the study of alcohol consumption and epidemiology of alcohol-related disorders in Mongolia, researchers Nasanjargal L and Nasantsengel L reported that 60% of the population in Mongolia uses alcohol. Hence, this investigation shows that alcohol contributes to 8.6% harmful

<p>QUICK RESPONSE CODE</p> 	<p>DOI: 10.13040/IJPSR.0975-8232.10(9).4149-57</p>
<p>The article can be accessed online on www.ijpsr.com</p>	
<p>DOI link: http://dx.doi.org/10.13040/IJPSR.0975-8232.10(9).4149-57</p>	

effects, 9.9% alcohol abuse, and 6.2% alcohol dependence³. Alcohol use disorders (AUDs) is a substantial public health problem. It is grown-up many risk factors influence on alcoholism including social, behavior, an environment, and heredity conditions on the global.

The liver is a primary target for the detrimental effects of alcohol metabolism, which express high levels of alcohol oxidizing enzymes, alcohol dehydrogenase, aldehyde dehydrogenase, and CYP2E1^{4, 5, 6}. Pathological changes in EtOH intoxication model of alcoholic liver disease (ALD) including hepatocyte damages and serum marker enzymes are related to liver function^{7, 8, 9, 10, 11}. Alcohol's effect on the brain neurotransmitter change plays an essential role in AUDs, given EtOH's directly due to many neuropharmacological actions, including its intoxicating, sedative, anxiolytic and addictive properties¹². According to the *in-vivo* and *in-vitro* study, the determined effect of EtOH on neurotransmitter release was changed in the rat's brain region, as well as in prefrontal cortex, NAc, VTA and other. Therefore, brain damage at early changes of EtOH intoxication with hippocampus structure and neural loss was detected^{13, 14, 15}.

Alcuremon preparation derived from medicinal herbs, based on pharmacological research of Mongolian herbal drug Channadselshi has an effect of antioxidant, bile expelling, alcohol reduced consumption and liver protective on acute and chronic alcohol intoxication in rats^{16, 17}. Reactive oxygen species (ROS) and oxidative stress play an important role in the development of ALD¹⁸. Alcuremon contains extract of *Gentiana barbata* Froel., *Carthamus tinctorius* L., *Terminalia chebula* Retz., and *Rosa acicularis* Lindl., these are composed of many chemical compounds, including xanthenes, polyphenols, flavonoids, secoiridoids, rutin, tannins, antioxidant and others. These biologically active compounds had a wide range of pharmacological activities including antioxidant, anticancerogenic, antimutagenic, hepatoprotective, cytoprotective, cardioprotective, neuroprotective, antiviral, antiinflammatory and wound healing¹⁹⁻²⁶.

D Diosmetin is a flavonoid of the alcuremon and, it barely activates TrkB, like brain-derived neurotrophic factor (BDNF), also suppresses

caspase-3 activation in neurons weakly and nonselective²⁷. Flavonoids, luteolin, diosmin, and diosmetin, were found to inhibit activation/phosphorylation of STAT3 induced by IL-6 in cultured neuronal cells²⁸. Modern medication treatment drugs contain one substance, which reduces drinking behavior in AUDs, having a single - functioned target mechanism. It is insufficient for AUDs drug treatment. Therefore, poly compounds of the alcuremon, it probably has systemic treatment action as well as protecting neurons and hepatocytes in alcohol intoxication. The animal model is convenient for alcohol-induced neurotransmitter changes and liver disease. In this study, we investigated the hepatoprotective, neuroprotective and neuromodulator effects of alcuremon preparation on EtOH induced intoxication in rats.

MATERIALS AND METHODS:

Alcuremon Preparation: The study was performed from 2016 to 2017, at the Research Center of Institute of Traditional Medicine and Technology (ITMT). Alcuremon preparation was prepared in the Research Center of ITMT. Briefly, *Gentiana barbata* Froel., *Carthamus tinctorius* L., *Terminalia chebula* Retz., and *Rosa acicularis* Lindl., were collected from the Traditional Medicinal Drug Factory of ITMT. All the herbs were identified by Sc.D. Prof Ganbold E (No.: 2016/11-15). The herbs were dried and pulverized then stored in the dark at the room temperature. These herbs were extracted (3:1) in 70% ethanol by a re-maceration method. Alcuremon preparation contains the extract, limonic acid, and sodium benzoate.

Animals: Male adult Wistar rats (Healthy, 12-14 weeks, 220-250 g) were randomly selected from our animal house. They were raised in the animal house of the Research center, ITMT, Ulaanbaatar. Rats were kept in the laboratory under a constant condition of light/dark (12:12) and temperature (20 ± 2) with animal cage, free access to a standard animal diet and tap water for 7 days before and during the experiment. The experimental protocols were approved by the Ethical Committee of ITMT to minimize animals suffering (No. 02/2015). These guidelines were in according to international principles for the care and use of laboratory animals.

Subchronic EtOH Intoxication and Treatment:

The animals were randomly divided into four groups, each containing 5 rats: (I) water group, which received an oral administration of 0.9% saline 10 ml/kg/day for 14 days; (II) EtOH group, which received an oral administration of 30% EtOH 10 ml/kg/day for 14 days²⁹; (III, IV) EtOH + Alcuremon 50 and EtOH + Alcuremon 100 groups were received an oral administration of 30% EtOH 10 ml/kg/day for 14 days and both groups plus alcuremon preparation 50 and 100 mg/kg/day respectively.

All animals in the experimental groups survived until the end of the experiments. In the 15th day, rats were anesthetized with an injection of ketamine hydrochloride 80-90 mg/kg and then blood was collected by cardiocentesis for biochemical analysis. The rats were immediately euthanized by cervical dislocation after blood collection, and then the liver was harvested for histopathological assessments.

Chronic EtOH Intoxication and Treatment: Rats were randomly divided into five groups, each containing 6 rats: (I) water group, which received an oral administration of 0.9% saline 7 ml/kg/day for 60 days; (II) EtOH group, which received an oral administration of 40% EtOH 7 ml/kg/day for 60 days; (III, IV, V) EtOH + Alcuremon 50, EtOH + Alcuremon 100 and EtOH + Alcuremon 150 groups were received an oral administration of 40% EtOH 7 ml/kg/day for 60 days and all groups plus alcuremon preparation 50, 100 and 150 mg/kg/day respectively. Rats were euthanized by cervical dislocation 3 days after the last EtOH administration.

The brains were rapidly removed and into (4 °C) PBS solution and the room temperature was 4-6 °C at the procedure. Brains NAc were dissected rat brain slicer 13 between 20 and brains VTA were dissected rat brain slicer 37 between 45 by a coronal section. NAc and VTA were measured 100 mg, then each section to 1.0 ml brain homogenization buffer (1×PBS+1mMEDTA-19.3 ml, 5M NaCl-0.6 ml, Triton X100-0.1 ml, PMSF-1.0 ml, PH-7.4) for neurotransmitter analysis. The hippocampus was dissected rat brain slicer 25 between 35 by coronal section for histopathological assessments with cresyl violet stain **Fig 1**.

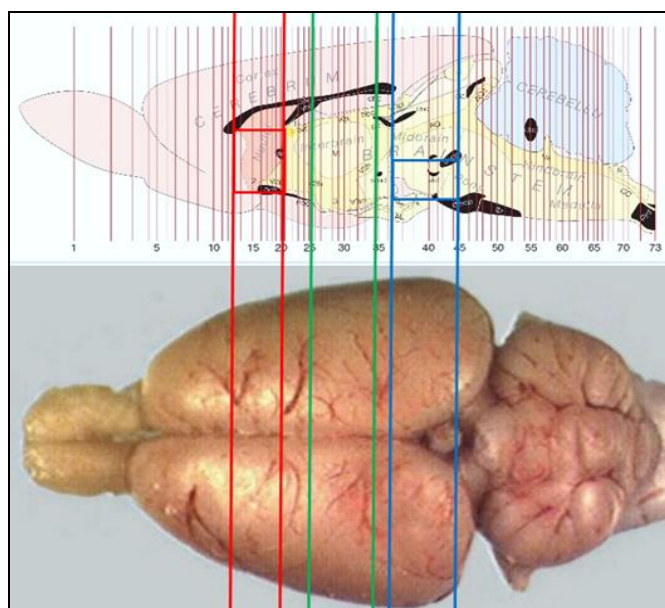


FIG. 1: BRAIN SECTION THAT HAS BEEN ANALYZED. Red: NAc, Blue: VTA, Green: Hippocampus

Brain Homogenization and Neurotransmitter Analysis:

The brain samples were homogenized for 15 sec by an ultrasonic homogenizer (JY88IN, China), then brain homogenates were centrifuged at 14000 rpm for 60 min (room temperature was 4 - 6°C during the procedure). After centrifugation, first supernatants were immediately collected and stored in a -20 °C for neurotransmitter analysis.

Then pellets were vortexed in 1.0 ml brain homogenization buffer before being centrifuged at 14000 rpm for 60 min. After centrifugation, second supernatants were immediately collected and stored in a -20 °C for neuro-receptor analysis,

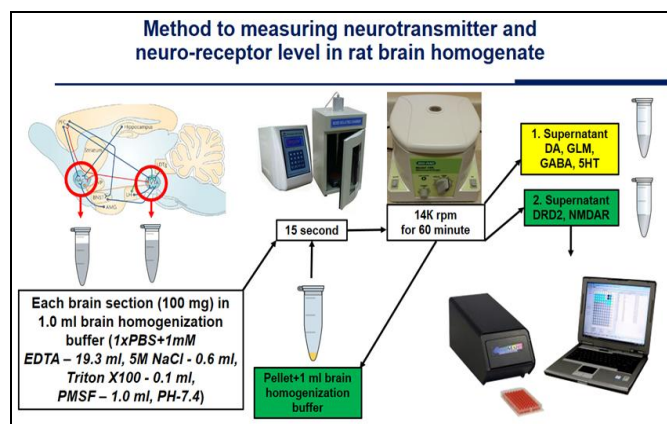


FIG. 2: SCHEMA OF NEUROTRANSMITTER ANALYSIS

Dopamine (DA), glutamate (GLM), serotonin (5HT) and gamma-aminobutyric acid (GABA) were quantified in the collected first supernatants, dopamine receptor D2 (DRD2) and N-Methyl-D-

aspartate receptor (NMDAR) were quantified in the collected second supernatants using rat ELISA kits (Shanghai, MLBio Biotechnology Co) according to the manufacturer's instructions. The absorbance was read at 450 nm using an ELISA microplate reader (ChroMate-4300, USA). The intensity of the color was directly proportional to the concentration in **Fig. 2**.

Biochemical Analysis: Blood was collected and standing at room temperature for 15 min, and the samples were centrifuged at 3000 rpm for 10 min to separate the serum. Subsequently, the serum samples were analyzed by assays for alanine aminotransferase (ALT), aspartate aminotransferase (AST) and alkaline phosphatase (ALP) using a semi-automatic biochemistry analyzer (DURUI DR-7000D).

Histopathology: The samples (the liver and brain hippocampus section) were fixed in 10% formaldehyde and embedded in paraffin. Then 4-6 micrometer sections were taken from the paraffin-embedded blocks by a microtome. Liver sections were deparaffinized and stained with hematoxylin and eosin (HE). Brain hippocampus sections were deparaffinized and stained with cresyl violet. After being stained by HE and cresyl violet, the liver and hippocampus morphology were observed and photographed using an Olympus imaging system.

Statistical Analysis: The data were shown as mean \pm SD. An analysis of variance (ANOVA followed by Tukey's post hoc test) was performed to determine significance using software GraphPad Prism 5.0 and a value of $p < 0.05$ was considered as significant.

RESULTS:

Effect of Alcuremon Preparation on Subchronic Alcohol Intoxication with Alcoholic Liver Disease in Rats: *In-vivo*, biochemical parameters including ALT, AST and ALP levels for all groups at the end of the experiment was shown by **Fig. 3**. Administration of EtOH has considerably increased the levels of serum ALT, AST, and ALP when compared to the water group ($^{\#}p < 0.05$). During the EtOH, the serum biochemical parameters of animals treated with alcuremon 50 mg/kg as well as alcuremon 100 mg/kg significantly ($*p < 0.05$) decreased.

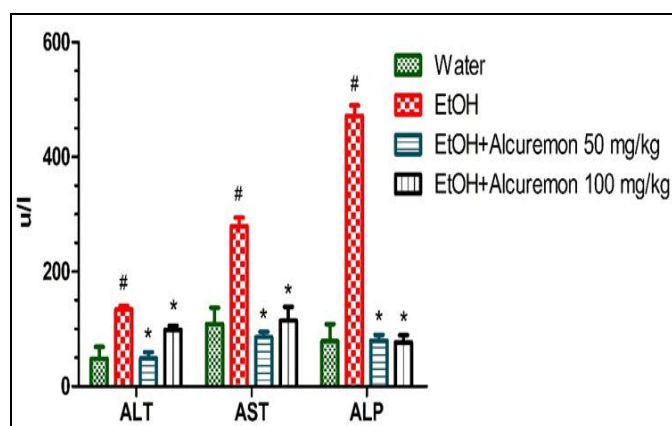


FIG. 3: EFFECT OF THE ALCUREMON PREPARATION ON TOTAL CONTENT OF REDUCED ALT, AST AND ALP LEVELS OF THE SERUM WITH SUBCHRONIC ALCOHOL INTOXICATION. ALT: alanine aminotransferase, AST: aspartate aminotransferase, ALP: alkaline phosphatase, EtOH: ethanol. $^{\#}p < 0.05$ vs. water group, $*p < 0.05$ vs. EtOH group by one-way ANOVA followed by Tukey's post hoc tests (n=5)

In the EtOH group, the hepatocytes present small or medium fatty vacuoles around the nucleus (microvesicular and macrovesicular changes) and abnormal arrangements of the sinusoid. Hepatic steatosis is the accumulation of triglycerides and fatty acids in the liver cells. Accumulating fats and triglycerides has shown that alcoholic liver disease correlates with the increasing level of serum ALT, AST, and ALP. The liver consists of an inter-anastomosing network of hepatocytes arranged in thick cell plates separated by sinusoids and hepatocytes along with vascular channels, forming organized structures which stored structural and functional units in alcuremon treated groups. In other words, histological examination showed no pathological abnormalities in the liver at the EtOH + alcuremon treated groups **Fig. 4**.

Effect of Alcuremon Preparation on Chronic Alcohol Intoxication with Neurotransmitter Imbalance in Rats: The values for brain homogenates (NAc and VTA) dopamine, glutamate, serotonin, gamma-aminobutyric acid, dopamine D2 receptor and N-Methyl-D-aspartate receptor in the EtOH group were significantly imbalanced (Decreased: DA, 5HT and GABA in NAc and VTA; D2DR and NMDAR in VTA. Increased: GLM in NAc and VTA; D2DR and NMDAR in NAc. $^{\#}p < 0.05$) after 60 days of 40% ethanol 7 ml/kg/day oral administration, compared to water group **Table 1** and **2**.

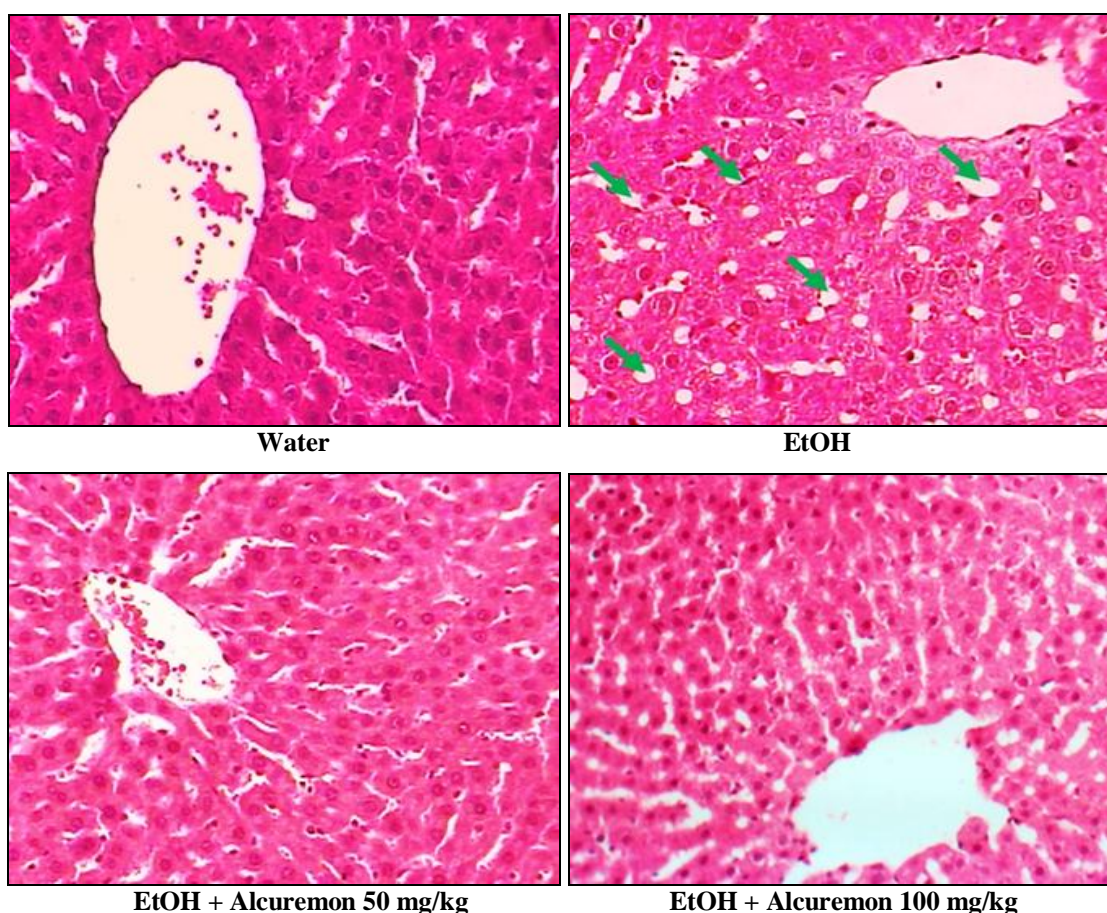


FIG. 4: PHOTOMICROGRAPHS OF HISTOLOGICAL STRUCTURES AND CHANGES IN THE RAT LIVER THAT HEMATOXYLIN-EOSIN (HE) STAINED LIVER SECTION FROM RATS OF EACH GROUP. HE SECTION SHOWS INFLAMMATORY CELL INFILTRATION AND LIPID DEPOSITS (GREEN ARROWS) OF HEPATIC STEATOSIS CAUSED BY ALCOHOL. EtOH: ethanol. Magnification ×200

TABLE 1: EFFECT OF ALCUREMON ON BRAIN NEUROTRANSMITTER AND NEURO-RECEPTOR LEVELS IN RAT'S BRAIN NAC AREA WITH CHRONIC ETHANOL INTOXICATION

Neurotransmitter and neuro receptor	Water	EtOH	EtOH+ Alcaremon 50 mg/kg	EtOH+ Alcaremon 100 mg/kg	EtOH+ Alcaremon 150 mg/kg
Dopamine (pg/l)	3.828±0.235	0.832±0.669 [#]	2.007±0.617*	2.551±0.585*	2.5±0.609*
Glutamate (umol/l)	0.736±0.079	0.942±0.078 [#]	0.704±0.089*	0.710±0.121*	0.686±0.073*
Serotonin(ng/l)	3.028±0.351	2.020±0.10 [#]	2.640±0.245*	2.418±0.427	2.0±0.301 [#]
GABA (umol/l)	2.509±0.10	1.880±0.058 [#]	2.083±0.103 [#]	2.244±0.121*	2.230±0.162*
Dopamine D2DR(ng/l)	3.375±0.366	4.28±0.261 [#]	2.810±0.455*	3.330±0.455*	3.695±0.254
NMDAR(ng/dl)	0.242±0.021	0.352±0.061 [#]	0.208±0.038*	0.238±0.039*	0.283±0.052

Data were represented in the mean ± SD of 6 rats/group. NAc: nucleus accumbens, GABA: gamma-aminobutyric acid, NMDAR: N-Methyl-D-aspartate receptor, D2DR: D2-receptor EtOH: ethanol. [#]p<0.05 vs. water group, *p<0.05 vs. EtOH group by one-way ANOVA followed by Tukey's post hoc tests

TABLE 2: EFFECT OF ALCUREMON ON BRAIN NEUROTRANSMITTER AND NEURO-RECEPTOR LEVELS IN RAT'S BRAIN VTA AREA WITH CHRONIC ETHANOL INTOXICATION

Neurotransmitter and neuro receptor	Water	EtOH	EtOH + Alcaremon 50 mg/kg	EtOH + Alcaremon 100 mg/kg	EtOH + Alcaremon 150 mg/kg
Dopamine (pg/l)	4.345±1.224	1.43±0.227 [#]	1.89±0.630 [#]	3.19±0.489*	2.97±0.421*
Glutamate (umol/l)	0.772±0.171	0.967±0.088 [#]	0.771±0.066*	0.714±0.106*	0.893±0.075
Serotonin (ng/l)	4.055±0.725	1.378±0.33 [#]	2.028±0.672 [#]	1.773±0.541 [#]	1.425±0.184 [#]
GABA (umol/l)	2.273±0.22	1.757±0.092 [#]	1.945±0.201 [#]	2.062±0.120 [#]	1.965±0.203 [#]
Dopamine D2DR(ng/l)	3.718±0.540	2.6±0.496 [#]	2.798±0.764	2.308±0.397 [#]	2.158±0.370 [#]
NMDAR(ng/dl)	0.409±0.079	0.233±0.041 [#]	0.219±0.048 [#]	0.452±0.078*	0.545±0.081*

Data were represented in the mean ± SD of 6 rats/group. VTA: ventral tegmental area, GABA: gamma-aminobutyric acid, NMDAR: N-Methyl-D-aspartate receptor, D2DR: D2-receptor EtOH: ethanol. [#]p<0.05 vs. water group, *p<0.05 vs. EtOH group by one-way ANOVA followed by Tukey's post hoc tests.

Neurotransmitter changes in these molecular systems lead to tolerance and withdrawal when alcohol and aldehyde are removed from the body by ethanol oxidation. During the EtOH, the brain homogenates (NAc and VTA) dopamine, glutamate, serotonin, dopamine D2 receptor and N-Methyl-D-aspartate receptor of animals treated with Alcaremon 50 mg/kg as well as Alcaremon 100 mg/kg significantly balanced, (increased: DA in NAc and VTA; 5HT and GABA in NAc; and NMDAR in VTA. Decreased: GLM in NAc and VTA; D2DR and NMDAR in NAc. # $p < 0.05$) compared to EtOH group in **Table 1** and **2**. Therefore, the oral administration of Alcaremon 150 mg/kg to treated group resulted in significantly balanced of neurotransmitter changes less than low and middle dosing. **Fig. 5** shows that as observed

from the Nissl body staining of neurons, a large number of dense pyramidal cells and granule cells were in the hippocampal CA1 and CA3 regions of water group rats. Also, in the EtOH group rats, there was a massive loss of pyramidal cells and necrosis in CA1 and CA3. Long term alcohol usage inhibits neuronal activity in the CA1 and CA3 areas of the hippocampus, and a portion of the neurons was incomplete. However, the rats treated with alcaremon (50, 100 and 150 mg/kg) the numbers of neuronal cells were significantly higher than the EtOH group. Also, a large number of dense pyramidal cells and granule cells were in the hippocampal CA1 and CA3, and the Nissl bodies filled in the cytoplasm **Fig. 5**. Alcaremon had a neuroprotective effect in hippocampal CA1 and CA3 neurons as compared with the EtOH group.

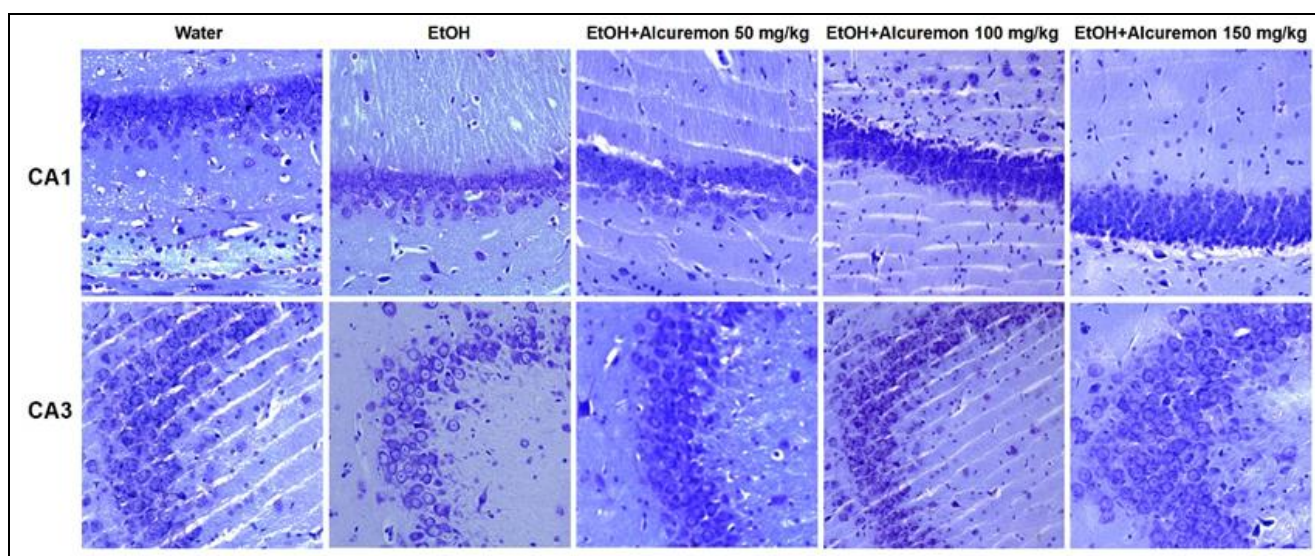


FIG. 5: NISSL STAINING OF NEURONS IN THE CA1 AND CA3 REGIONS OF THE RAT HIPPOCAMPUS OF EACH GROUP. A LARGE NUMBER OF DENSE PYRAMIDAL AND GRANULE CELLS WERE OBSERVED IN THE HIPPOCAMPI OF WATER GROUP RATS AND FILLED NISSL BODIES IN THE CYTOPLASM. CA: *Cornu amonis*, EtOH: ethanol, Magnification $\times 200$.

DISCUSSION: Our results demonstrated that hepatoprotective, neuroprotective and balancing neurotransmitters effect of alcaremon preparation based on Mongolian herbal medicine Channadselshi. This study showed these imbalanced neurotransmitters (Decreased: DA, 5HT and GABA in NAc and VTA; D2DR and NMDAR in VTA. Increased: GLM in NAc and VTA; D2DR and NMDAR in NAc.), liver damage and brain damage, particularly the altered hippocampal CA1 and CA3 neuronal loss associated with ethanol intoxication in rats. Moreover, during EtOH administration, balancing neurotransmitters, reducing serum ALT, AST and ALP, stored structural and functional

units of the liver and protecting hippocampal CA1 and CA3 neurons of animals with treated alcaremon preparation.

The current study shows that acute effects of alcohol including increased dopamine release (associated with reward), increased GABA receptor activity (associated with anxiolytic, sedation, and motor incoordination), and decreased glutamate receptor activity. Chronic alcohol consumption causes neuro-adaptations to oppose the effects of acute alcohol, decreased dopamine release and increased dopamine receptor expression, decreased GABA receptor expression, increased glutamate

release and increased NMDA receptor expression^{30, 31, 32, 33}. Alcohol ingestion is associated with multi-organ systems damage, and the liver is a primary target for the detrimental effects of alcohol metabolism. Modern medication treatment drugs contain one substance, which reduces drinking behavior in AUDs, having a single-functioned target mechanism. Accordingly, it is not enough to fight alcoholism with medications. Also, poly compounds of the alcuremon might have to affect systemic treatment action in alcohol intoxication.

Alcuremon preparation contained ethanol extracts of four medicinal herbs, *Gentiana barbata* Froel., *Carthamus tinctorius* L., *Terminalia chebula* Retz., and *Rosa acicularis* Lindl. These herbs are a wide range of pharmacological activities including antioxidant, anticancerogenic, antimutagenic, hepatoprotective, cytoprotective, cardioprotective, neuroprotective, antiviral, anti-inflammatory, wound healing and others. There are many chemical compounds in alcuremon, and the main biologically active components of these plants are polyphenols, terpenes, anthocyanins, flavonoids, alkaloids, tannin, glycosides etc.^{19, 20, 21, 22, 23, 24, 25, 26}.

Anticholinesterase (AChE) properties of *Terminalia chebula* Retz. has reported in some research^{34, 35}. The review by Amir R *et al.* focuses on *Terminalia chebula* Retz. with a high content of phenolic constituents exhibits strong antioxidant and neuroprotective activities *in-vitro* and *in-vivo*. AChE induces apoptotic and necrotic cell death by inducing membrane depolarization and NMDA receptor activation with consequent Ca^{2+} influx and modulation of the $\alpha 7$ nicotinic acetylcholine receptor in hippocampal cultures. Therefore, AChE has the main role in neurodegeneration and AChE inhibitors could be effective in neuroprotection³⁶.

Gentiana barbata Froel., the herb contains 0.2% alkaloids, 2.3–5.91% xanthenes, flavonoids: 5,7,3'-trihydroxy-4'-methoxyflavone (diosmetin) and others¹⁹. Diosmetin is barely activated tyrosine receptor kinase B (TrkB), weakly and nonselective suppressed caspase-3 activation in neurons²⁷. TrkB-mediated BDNF regulates synaptic structure and strength in hippocampal and other neurons. It may have an effect of balancing neurotransmitters release in neural circuits³⁷.

In another side, dried extract of *Gentiana barbata* Froel. Effectively improves bile secretion, balances metabolism, hepatoprotective, and increased antioxidant system in rats with toxic hepatitis³⁸. Flavonoids, luteolin, diosmin, and diosmetin, were found to inhibit activation/phosphorylation of STAT3 induced by IL-6 in cultured neuronal cells²⁸.

Carthamus tinctorius L., kaempferol decreased hepatocyte cellular necrosis and infiltration belonged to an antioxidant in a CCl_4 rat model of hepatitis³⁹. It can protect neuron *via* inhibiting STAT3 and nuclear factor- κB ⁴⁰. In recent study showed that hydroxysafflor yellow A protects the liver of rats with chronic alcohol intoxication, which increases liver superoxide dismutase (SOD) and glutathione peroxidase (GPx), reduced TGF- $\beta 1$ expression and decreased serum biochemical parameters such as ALT and AST⁴¹.

Rosa acicularis Lindl. Contains sugar, ascorbic acid, carotene, tannins, rutin, astragaline, and hyperoside¹⁹. Liver protective and antioxidant effect of this herb related to chemical compounds such as hyperoside, which effect regulated by antioxidant response elements in L02 liver cells with oxidative damage⁴².

Consequently, neuroprotective, balancing neurotransmitters and hepatoprotective effects of Alcuremon, which are related to chemical compounds of the preparation such as diosmetin, luteolin, gallic acid, kaempferol, hydroxysafflor yellow A, hyperoside and others. However, this study limited the only *in-vivo*, and further investigations are needed to conduct in *in-vitro* experiments and various models of alcohol intoxication.

CONCLUSION: This study demonstrated the hepatoprotective, neuroprotective & neuromodulator effects of alcuremon preparation based on Mongolian herbal medicine Channadselshi in the rat model of ethanol intoxication. Furthermore, the action of balancing neurotransmitters, hepatoprotective and neuroprotective effects were associated with biologically active components of alcuremon. Polyphenolic compounds, gallic acid, diosmetin and others could be responsible for this systemic pharmacological actions.

Further investigations are necessary to check the effects or mechanism of this herbal preparation in various models of alcoholism over any definitive conclusion.

ETHICAL MATTER: The experimental procedures and protocols were approved by the Ethical Committee of the Institute of Traditional Medicine and Technology (No. 02/2015). These guidelines were by the accepted principles for care and use of the laboratory animals.

ACKNOWLEDGEMENT: We thank the colleagues of the Institute of Traditional Medicine and Technology for support during this study.

CONFLICT OF INTEREST: The authors declare that they have no competing interests.

AUTHORS' CONTRIBUTIONS: BJ designed and coordinated the study. BJ and NG carried out the animal experiments, neurotransmitter analysis, biochemical analysis, data analysis and wrote the manuscript. The alcuremon preparation was prepared by SB. AA carried out the histology and microscopic analysis. CC advised the work. All authors read and approved the final manuscript.

REFERENCES:

1. World Health Organization: Global status report on alcohol and health. WHO Press, 2018 Edition 2018.
2. Chen C and Yoon YH: Trends in alcohol-related morbidity among community hospital discharges, United States 2000–2015. NIAAA Surveillance Report 2018; 112: 1-30.
3. Nasanjargal L and Nasantsengel L: Alcohol consumption and epidemiology of alcohol-related disorders in Mongolia. Innovation Medical Journal 2015; 9: 98-101.
4. Ronis MJ, Hennings L and Stewart B: Effects of long-term ethanol administration in a rat total enteral nutrition model of alcoholic liver disease. Am J Physiol Gastrointest Liver Physiol 2010; 300(1): 109-19.
5. Das SK, Dhanya L, Varadhan S, Mukherjee S and Vasudevan DM: Effects of chronic ethanol consumption in blood: A time-dependent study on rat. Indian J Clin Biochem 2009; 24(3): 301-06.
6. Osná NA and Kharbanda KK: Multi-organ alcohol-related damage: Mechanisms and Treatment. Biomolecules 2016; 6(2): 1-5.
7. Han Y, Xu Q, Hu JN, Han XY, Li W and Zhao LC: Maltol, a food flavoring agent, attenuates acute alcohol-induced oxidative damage in mice. Nutrients 2015; 7(1): 682-96.
8. Antushevich AE, Antushevich AE, Grebenyuk AN, Khalyutin DA and Yartsev AA: Experimental modeling of alcohol-induced liver cirrhosis in rats. Bulletin of Experimental Biology and Medicine 2018; 164(3): 404-07.
9. Mani V, Arivalagan S, Islam Siddique A and Namasivayam N: Antihyperlipidemic and antiapoptotic potential of zingerone on alcohol induced hepatotoxicity in experimental rats. Chem Biol Interact 2017; 272: 197-06.

10. Chaphalkar R, Apte KG, Talekar Y, Ojha SK and Nandave M: Antioxidants of *Phyllanthus emblica* L. bark extract provide hepatoprotection against ethanol-induced hepatic damage: a comparison with silymarin. Oxidative Medicine and Cellular Longevity 2017; 2017: 3876040
11. Natarajan SK, Pachunka JM and Mott JL: Role of microRNAs in alcohol-induced multi-organ injury. Biomolecules 2015; 5(4): 3309-38.
12. Most D, Ferguson L, and Harris RA: Molecular basis of alcoholism. Handb Clin Neurol 2014; 125: 89-111.
13. Fliegel S, Brand I, Spanagel R and Noori HR: Ethanol-induced alterations of amino acids measured by *in-vivo* micro-dialysis in rats: a meta-analysis. *In-silico* Pharmacology 2013; 1: 7.
14. Cui C, Noronha A, Morikawa H, Alvarez VA, Stuber GD, Szumlinski KK, Kash TL, Roberto M and Wilcox MV: New insights on neurobiological mechanisms underlying alcohol addiction. Neuropharmacology 2013; 67: 223-32.
15. Wang P, Luo Q and Qiao H: The neuroprotective effects of carvacrol on ethanol-induced hippocampal neurons impairment *via* the antioxidative and antiapoptotic pathways. Oxid Med Cell Longev 2017; 2017: 1-17.
16. Bat-Erdene J, Uugantsetseg M, Alimaa T and Chimedragchaa C: Effect of Channadselshi on voluntary alcoholic Wistar rats. Mongol Med Sci 2015; 171: 54-60.
17. Bat-Erdene J and Chimedragchaa C: Effect of CNS on voluntary alcohol consumption in rats. Journal of Traditional Mongolian Medicine 2017; 8: 47-48
18. García-Ruiz C, José C and Fernández-Checa: Mitochondrial oxidative stress and antioxidants balance in fatty liver disease. Hepatology Communications 2018; 12(2): 1425-39.
19. World Health Organization Western Pacific Region: Medicinal plants in Mongolia. WHO Press. 1st Ed 2013.
20. Ramagiri S and Taliyan R: Neuroprotective effect of hydroxysafflor yellow A against cerebral ischemia-reperfusion injury in rats: putative role of mPTP. Journal of Basic and Clinical Physiology and Pharmacology 2015; 27(1): 1-8.
21. Basha SJ, Reddy VJ and Rani SY: A review on *Terminalia chebula*. International Journal of Pharmacological Research 2017; 7(10): 187-91.
22. Delshad E, Yousefi M, Sasannezhad P, Rakhshandeh H and Ayati Z: Medical uses of *Carthamus tinctorius* L. (Safflower): a comprehensive review from Traditional Medicine to Modern Medicine. Electron Physician 2018; 10(4): 6672-81.
23. Kumar R, Arora R, Agarwal A and Gupta YK: Protective effect of *Terminalia chebula* against seizures, seizure-induced cognitive impairment and oxidative stress in experimental models of seizures in rats. J Ethnopharmacol 2018; 215: 124-31.
24. Shen YC, Juan CW, Lin CS, Chen CC and Chang CL: Neuroprotective effect of *Terminalia chebula* extracts and ellagic acid in pc12 cells. Afr J Tradit Complement Altern Med 2017; 14(4): 22-30.
25. Khan A, Nazar H and Sabir SM: Antioxidant activity and inhibitory effect of some commonly used medicinal plants against lipid peroxidation in mice brain. Afr J Tradit Complement Altern Med 2014; 11(5): 83-90.
26. Choi MK, Kim HG and Han JM: Hepatoprotective Effect of *Terminalia chebula* against t-BHP-induced acute liver injury in C57/BL6 mice. Evid Based Complement Alternat Med 2015; 2015: 1-11.
27. Jang SW: A selective TrkB agonist with potent neurotrophic activities by 7, 8-dihydroxyflavone. PNAS 2010; 107: 2687-92.

28. Tan J, Luo D and Shytle R: Luteolin and diosmin /diosmetin as novel STAT3 inhibitors for treating autism. USF Patents 2014; 137: 1-17.
29. Geidam MA, Chabiri SA and Shettima Y: Effects of Methanolic leaf extract of *Adansonia digitata* on serum lipid levels in normal and ethanol-fed rats. Pakistan Journal of Biological Sciences 2014; 7: 1094-95.
30. Erdozain AM and Callado LF: Neurobiological alterations in alcohol addiction: a review. *Adicción* 2014; 26: 360-70.
31. Fliegel S, Brand I, Spanagel R and Noori HR: Ethanol-induced alterations of amino acids measured by in vivo microdialysis in rats: a meta-analysis. *In-silico Pharmacology* 2013; 1: 7.
32. Tabakoff B and Hoffman PL: The neurobiology of alcohol consumption and alcoholism: An integrative history. *Pharmacol Biochem Behav* 2013; 113: 20-37.
33. Cui C, Noronha A and Morikawa H: New insights on neurobiological mechanisms underlying alcohol addiction. *Neuropharmacology* 2012; 67: 223-32.
34. Sanchetia S and Sanchetia S: 1,2,3,4,6-penta-O-galloyl- β -D-glucose: a cholinesterase inhibitor from *T. chebula*. *South African Journal of Botany* 2010; 76: 285-88.
35. Murray AP, Faraoni MB, Castro MJ, Alza NP and Cavallaro V: Natural AChE inhibitors from plants and their contribution to Alzheimer's disease therapy. *Curr Neuropharmacol* 2013; 11(4): 388-13.
36. Afshari AR, Sadeghnia HR and Mollazadeh H: A review on potential mechanisms of *Terminalia chebula* in Alzheimer's disease. *Adv Pharmacol Sci* 2016; 2016: 1-14.
37. Elmariah SB, Crumling MA, Parsons TD and Balice-Gordon RJ: Postsynaptic TrkB-mediated signaling modulates excitatory and inhibitory neurotransmitter receptor clustering at hippocampal synapses. *J Neurosci* 2004; 24(10): 2380-93.
38. Nikolaev SM, Tsyrenzhapov AV, Sambueva ZG, Nikolaeva GG, Ratnikova GV and Tankhaeva LM: Hepatoprotective effect of granules of the dry extract obtained from *Gentianopsis barbata* (Froel). *Eksp Klin Farmakol* 2001; 64(1): 49-52.
39. Yu W, Tang C and Zhang H: Hepatoprotective effects of kaempferol 3-O-rutinoside and kaempferol 3-O-glucoside from *Carthamus tinctorius* L. on CCl4-induced oxidative liver injury in mice. *Journal of Food and Drug Analysis* 2015; 23: 310-17.
40. Yu L, Chen C, Wang LF, Kuang X, Liu K, Zhang H and Du JR: Neuroprotective effect of kaempferol glycosides against brain injury and neuroinflammation by inhibiting the activation of NF- κ B and STAT3 in transient focal stroke. *PLoS One* 2013; 8(2): e55839.
41. He Y, Liu Q, Li Y, Yang X, Wang W, Li T, Zhang W, Cui Y, Wang C and Lin R: Protective effects of hydroxysafflor yellow A (HSYA) on alcohol-induced liver injury in rats. *J Physiol Biochem* 2015; 7(1): 69-78.
42. Xing HY, Cai YQ, Wang XF, Wang LL, Li P, Wang GY and Chen JH: The cytoprotective effect of hyperoside against oxidative stress is mediated by the Nrf2-ARE signaling pathway through GSK-3 β inactivation. *Plos One* 2015; 10(12): e0145183.

How to cite this article:

Jargalsaikhan BE, Ganbaatar N, Borchuluun S, Adilbish A and Chimedtseren C: Treatment effect of alcuremon preparation on ethanol-induced neurotransmitters imbalance and alcoholic liver disease in rats. *Int J Pharm Sci & Res* 2019; 10(9): 4149-57. doi: 10.13040/IJPSR.0975-8232.10(9).4149-57.

All © 2013 are reserved by International Journal of Pharmaceutical Sciences and Research. This Journal licensed under a Creative Commons Attribution-NonCommercial-ShareAlike 3.0 Unported License.

This article can be downloaded to **Android OS** based mobile. Scan QR Code using Code/Bar Scanner from your mobile. (Scanners are available on Google Play store)