



Received on 07 February 2019; received in revised form, 28 May 2019; accepted, 14 June 2019; published 01 October 2019

COMPARATIVE ACUTE AND SUB-ACUTE TOXICITY STUDY OF HYDRO-ALCOHOLIC EXTRACTS OF *CENTELLA ASIATICA* AND *EVOLVULUS ALSINOIDES* IN SWISS ALBINO MICE

Mukesh Kumar Yadav ^{*1}, Santosh Kumar Singh ², Manish Singh ³, Shashank Shekhar Mishra ⁴, Anurag Kumar Singh ², Jyoti Shankar Tripathi ¹ and Yamini Bhusan Tripathi ⁵

Department of Kayachikitsa ¹, Centre of Experimental Medicine & Surgery ², Department of Pharmacology ³, Department of Vikriti Vigyan ⁴, Department of Medicinal Chemistry ⁵, Institute of Medical Sciences, Banaras Hindu University, Varanasi - 221005, Uttar Pradesh, India.

Keywords:

Centella asiatica, *Evolvulus alsinoides* L., Hydro-alcoholic extracts, Sub-acute, Biochemical, Hematological, Histopathological

Correspondence to Author:

Mukesh Kumar Yadav

Department of Kayachikitsa,
Institute of Medical Sciences, Banaras
Hindu University, Varanasi - 221005,
Uttar Pradesh, India.

E-mail: mukesh.yadav@bhu.ac.in

ABSTRACT: In this study, the *in-vivo* toxicity of *Centella asiatica* & *Evolvulus alsinoides* were evaluated by acute and sub-acute toxicity assays according to the guidelines of OECD 423 & 407 respectively. For LD₅₀ evaluation, a single dose of hydro-alcoholic extracts of both plants was orally administered to Swiss albino mice at doses of 200, 400, 800, 1600 and 2000 mg/kg. Then the animals were observed for 72 h. For acute toxicity evaluation, a single dose of hydro-alcoholic extracts of both plants was orally administered to mice at doses of 300, 600, 1200 and 2000 mg/kg. Then, the animals were observed for 14 days. In the sub-acute study, the extracts were orally administered to mice for 28 days at doses of 300, 600, 1200, and 2000 mg/kg. To assess the toxicological effects, animals were closely observed on general behavior, clinical signs of toxicity, body weight, food, and water intake. At the end of the study, it was performed biochemical and hematological evaluations, as well as histopathological analysis from the following organs: brain, heart, liver, and kidney.

INTRODUCTION: *Centella asiatica* (CA) L. urban belonging to family Apiaceae (Umbelliferae) is a psychoactive medicinal plant being used for centuries in the Ayurvedic system of medicine as a medhya rasayna. It has been reported to possess various pharmacological effects on the central nervous system such as stimulatory-nervine tonic, rejuvenant, sedative, anxiolytic, and intelligence promoting property ^{1,2}.

CA has been reported to contain triterpene derivatives in major amounts and the earliest examples of this compounds present in CA were identified in the late 1940s as “asiatic acid and madecassic acid” along with their heterosides named as “asiaticoside” and “madecassoside” constituting approximately up to 10% of the plant ³. Later on, compounds from various chemical classes have been also isolated, such as flavonoids ⁴, polyacetylenes ⁵, and phenolic acids ⁶.

Evolvulus alsinoides (EA) is an important plant that has been well documented in Ayurveda for its therapeutic values. *Evolvulus alsinoides* (Family: Convolvulaceae) commonly known as Shankhpuspi is found throughout India ascending to 6000ft in the Himalayas. It is well known for its therapeutic

QUICK RESPONSE CODE	DOI: 10.13040/IJPSR.0975-8232.10(10).4694-99
	The article can be accessed online on www.ijpsr.com
DOI link: http://dx.doi.org/10.13040/IJPSR.0975-8232.10(10).4694-99	

effect on brain disorders like insanity, epilepsy, memory enhancement and nervous debility in the Indian Ayurvedic system of medicine. Recent pharmacological studies on leaves and whole plant of EA have indicated its anti-inflammatory, antipyretic and anti-diarrhoeal properties⁷ and immunomodulatory properties⁸. Some *in-vitro* experiments have revealed the antioxidant properties of EA⁹.

MATERIALS AND METHODS:

Plant Material: Whole plant material of *Centella asiatica* was collected from village Ramnapur, Varanasi, Uttar Pradesh, India in October 2015 and authentication was done by Department of Botany, Banaras Hindu University, India and also herbarium of *C. asiatica* (voucher specimen no. Apia/02/2015) and *Evolvulus alsinoides* (voucher specimen no. Convolvul./03/2015) of plants were deposited in the Department of Botany, Banaras Hindu University, India.

Preparation of Extracts: The extraction of both plants was done with Soxhlet method in hydroalcoholic (70: 30 ratio, ethanol: distilled water) solvent at 72-100 °C for 72 h. The Soxhlet extraction has widely been used for extracting valuable bioactive compounds from various natural sources. It is used as a model for the comparison of new extraction alternatives.

Generally, a small amount of dry sample is placed in a thimble. The thimble is then placed in distillation flask which contains the solvent of particular interest. After reaching an overflow level, the solution of the thimble-holder is aspirated by a siphon. Siphon unloads the solution back into the distillation flask. This solution carries extracted solutes into the bulk liquid. The solute remains in the distillation flask and solvent passes back to the solid bed of plant. The process runs repeatedly until the extraction is completed.

Animals: The experimental Swiss albino mice were issued by Animal house of Institute of Medical Sciences, Banaras Hindu University Varanasi, Uttar Pradesh.

Animals were divided into experimental groups, housed in plastic cages and maintained on a 12-h light and 12-h dark cycle. They were given standard food and water *ad libitum*. The Central

Animal Ethical Committee of Banaras Hindu University approved all experimental procedures (CAEC/196).

Preparation of Extract Samples: Hydro-alcoholic extracts of *C. asiatica* (HACA) and *E. alsinoides* (HAEA) were solubilized in distilled water to obtain solutions of 30, 60, 120, and 200 mg/ml. The doses 300, 600, 1200, and 2000 mg/kg were evaluated for further study.

Toxicity Assays: The safety parameters assessed by conducting the acute and sub-acute toxicity study according to the OECD (Organization for Economic Co-operation and Development guideline) guidelines 423 & 407, respectively.

Acute Toxicity Assay: The animals were divided into nine experimental groups of 6 animals each. Group 1 received 10 µl/g of distilled water and served as control. Groups 2 to 5 treated with hydro-alcoholic extract of *C. asiatica* at the doses of 300, 600, 1200 and 2000 mg/kg and groups 6 to 9 were treated with the hydro-alcoholic extract of *E. alsinoides* at doses of 300, 600, 1200 and 2000 mg/kg respectively.

All treatments were administered once by oral gavage. Animals were closely observed for 4 h following administration and once a day for 14 days on general behavior, clinical signs of toxicity, mortality, food, and water intake. Body weight was measured before and after administration on days 4, 7, 10, and 14. At the end of the experiment, animals were anesthetized with ketamine (20 mg/kg i.p.). After the anesthesia has reached depth, the cardiac puncture was performed to collect blood for biochemical and hematological evaluations.

Sub-acute Toxicity Assay: The animals were divided into nine experimental groups of 6 animals each. Group 1 received 10 µl/g of distilled water and served as control. Groups 2 to 5 treated with hydro-alcoholic extract of *C. asiatica* at the doses of 300, 600, 1200 and 2000 mg/kg and groups 6 to 9 were treated with hydro-alcoholic extract of *E. alsinoides* at doses of 300, 600, 1200 and 2000 mg/kg respectively.

All treatments were administered once by oral gavage daily 7 days each week for 28 days. Animals were closely observed for 28 days on

general behavior, clinical signs of toxicity, mortality, food, and water intake. Body weight was measured before and after administration on days 7, 14, 21, and 28. At the end of the experiment, animals were anesthetized with ketamine (20 mg/kg i.p.). After the anesthesia has reached depth, the cardiac puncture was performed to collect blood for biochemical and hematological evaluations.

Hematological Analysis: The hematological evaluation was performed in all surviving animals at the end of the experiment. The complete blood count was performed using an automated hematology analyzer. Hematological evaluations included red blood cell count (RBC), hemoglobin concentration (HGB), platelet count (PLT), hematocrit (HCT), mean corpuscular volume (MCV), mean corpuscular hemoglobin (MCH), mean corpuscular hemoglobin concentration (MCHC) and white blood cell count (WBC).

Blood Serum Biochemistry Analysis: The biochemical evaluation was performed in all surviving animals at the end of the experiment. The collected blood was transferred to tubes without anticoagulant and allowed to stand for 60 min at room temperature and centrifuged at 4000 rpm for 10 min. The serum from each blood sample was recovered and stored in cryogenic tubes at -80 °C deep freezer. Urea, creatinine, serum glutamic oxaloacetic transaminase (SGOT), serum glutamic pyruvic transaminase (SGPT), and alkaline phosphatase were evaluated.

Histopathology: The organs were collected from all surviving animals, washed with saline solution 0.9% (w/v), weight and fixed in 40% formaldehyde solution. Then organs were processed for paraffin embedding. 5 µm thick sections were prepared and stained with hematoxylin and eosin (H & E).

The tissues were analyzed in an optical microscope for their general structure, signs of inflammation, degenerative changes, and necrosis evidence. The images were captured with the microscope Motic B1 series, scanned through micro camera Moticam 480 using the Motic Images Plus 2.0ML Application Suite software.

Statistical Analysis: The relative hematological and biochemical data were expressed as the mean ±

standard error of the mean (SEM). Data were submitted to analysis of variance (one-way ANOVA) followed by Dunnett multiple comparison test. The software GraphPad Prism 6.0 (GraphPad Software, USA) was used for statistical analysis. P values < 0.05 were considered statistically significant.

RESULTS:

Acute Toxicity & Sub-acute Toxicity:

General Signs and Mortality: No signs of toxicity or behavioral changes were observed after the treatment with HAEA and HACA. No deaths were recorded within 72 h after administration of the extracts and the control in mice.

Body Weight, Relative Organ Weight, Food and Water Intake:

Female mice treated with HAEA and HACA at the three evaluated doses showed weight gain throughout the entire experiment duration. The increase was the same in treated and control group animals, and the treatment did not affect relative organs weights, food, and water intake.

Hematological Parameters: Treatment with HAEA and HACA at all doses did not produce any changes on animal (female) hematological parameters, and the result found statistically significant at $P < 0.01$ **Table 1**. Hematological parameters of Swiss mice treated for 28 days with different doses (300, 600, 1200 and 2000 mg/kg) of hydro-alcoholic extracts of *E. alsinoides* (HAEA) and *C. asiatica* (HACA).

Biochemical Parameter: Treatment with HAEA and HACA at the all doses did not produce any statistically significant changes on urea, creatinine, SGOT, SGPT and alkaline phosphatase **Table 2** and the result found statistically significant at $P < 0.01$.

Histopathological Analysis: The oral administration of HAEA and HACA did not produce significant dose-dependent histopathological alterations. At the evaluated doses, it was not observed any tissue damage on the brain, heart, lungs, and liver of female mice. **Fig. 1-4** microscopic histological slides from different organs of Swiss albino mice treated with hydro-alcoholic extracts of *E. alsinoides* & *C. asiatica* i.e. HAEA & HACA, respectively.

TABLE 1: HEMATOLOGICAL PARAMETERS

Groups	Hematological Parameters							
	HGB (g/dL)	RBC (10 ⁶ /μL)	PLT (10 ³ /μL)	HCT (%)	MCV (fL)	MCH (pg)	MCHC (g/dL)	WBC (10 ³ /μL)
Control	13.1 ± 0.45	6.78 ± 0.29	881.97 ± 32.4	40.8 ± 0.86	55.7 ± 0.82	19.2 ± 0.57	31.8 ± 1.00	5.78 ± 0.08
HAEA 300	12.7 ± 0.28	6.24 ± 0.24	936.40 ± 15.7	41.7 ± 0.75	57.4 ± 1.27	20.4 ± 0.51	33.7 ± 0.98	5.89 ± 0.18
HAEA 600	13.2 ± 0.75	7.11 ± 0.69	858.24 ± 17.2	45.9 ± 1.64	56.2 ± 1.21	18.6 ± 0.52	32.5 ± 0.63	5.41 ± 0.61
HAEA 1200	12.9 ± 0.73	6.60 ± 0.43	881.57 ± 49.0	42.8 ± 2.10	55.7 ± 1.51	18.0 ± 0.80	30.7 ± 1.24	5.14 ± 0.58
HAEA 2000	13.3 ± 0.61	7.18 ± 0.60	859.7 ± 38.87	42.2 ± 1.89	56.8 ± 1.75	19.9 ± 1.71	31.7 ± 1.57	5.40 ± 0.30
HACA 300	12.8 ± 0.64	6.57 ± 0.41	834.63 ± 26.0	41.2 ± 1.06	55.5 ± 1.55	18.3 ± 0.80	30.8 ± 1.26	5.68 ± 0.41
HACA 600	12.7 ± 0.28	6.24 ± 0.24	936.41 ± 41.0	41.7 ± 1.06	57.4 ± 1.56	20.4 ± 1.06	33.7 ± 1.61	5.89 ± 0.42
HACA 1200	13.5 ± 0.46	7.25 ± 0.56	892.21 ± 58.9	45.5 ± 1.99	55.8 ± 0.81	18.8 ± 0.78	32.9 ± 0.73	5.27 ± 0.52
HACA 2000	14.1 ± 0.26	7.91 ± 0.33	810.10 ± 17.6	45.2 ± 1.95	56.3 ± 1.63	19.9 ± 1.38	32.7 ± 0.57	5.67 ± 0.11

n =6 Swiss albino mice (females), One-way AVOVA, followed by Dunnett's multiple comparison test. *p<0.05, **p<0.01, ***p<0.001. Hemoglobin concentration (HGB), Red blood cell count (RBC), platelet count (PLT), hematocrit (HCT), mean corpuscular volume (MCV), mean corpuscular hemoglobin (MCH), mean corpuscular hemoglobin concentration (MCHC) and white blood cell count (WBC).

TABLE 2: BIOCHEMICAL PARAMETERS

Groups	Urea	Creatinine	SGOT	SGPT	Alkaline phosphatase
	Normal value= 25-30 mg/dl	Normal value= 0.2-0.9 mg/dl	Normal value= 54-298 mg/dl	Normal value= 17-77 mg/dl	Normal value= 35-96 mg/dl
Normal	27.47 ± 0.94	0.3 ± 0.03	60.64 ± 1.68	49.09 ± 2.07	49.32 ± 3.08
HAEA 300	26.42 ± 0.67	0.5 ± 0.08	66.48 ± 2.42	34.80 ± 2.16	59.16 ± 1.86
HAEA 600	27.12 ± 0.95	0.4 ± 0.08	56.06 ± 1.71	54.59 ± 2.61	49.72 ± 3.78
HAEA 1200	28.36 ± 0.67	0.6 ± 0.05	58.64 ± 2.26	57.65 ± 2.90	50.37 ± 1.28
HAEA 2000	28.22 ± 0.55	0.68 ± 0.13	63.50 ± 2.58	42.03 ± 1.55	53.21 ± 2.99
HACA 300	27.72 ± 1.08	0.4 ± 0.11	57.5 ± 1.20	56.59 ± 2.11	52.73 ± 3.67
HACA 600	28.00 ± 1.23	0.8 ± 0.12	57.20 ± 0.49	51.61 ± 2.59	57.81 ± 3.03
HACA 1200	26.70 ± 1.18	0.8 ± 0.11	61.91 ± 2.75	48.83 ± 1.98	51.08 ± 2.58
HACA 2000	27.57 ± 0.53	0.5 ± 0.08	57.97 ± 1.52	49.01 ± 2.78	52.30 ± 1.88

Blood serum biochemical parameters of swiss albino mice treated with dosage (300, 600, 1200 & 2000 mg/kg) of hydro-alcoholic extracts of *C. asiatica* & *E. alsinoides*. n = 6 swiss albino mice (females), One-way AVOVA followed by Dunnett's multiple comparison test. *p<0.05, **p<0.01, ***p<0.001.

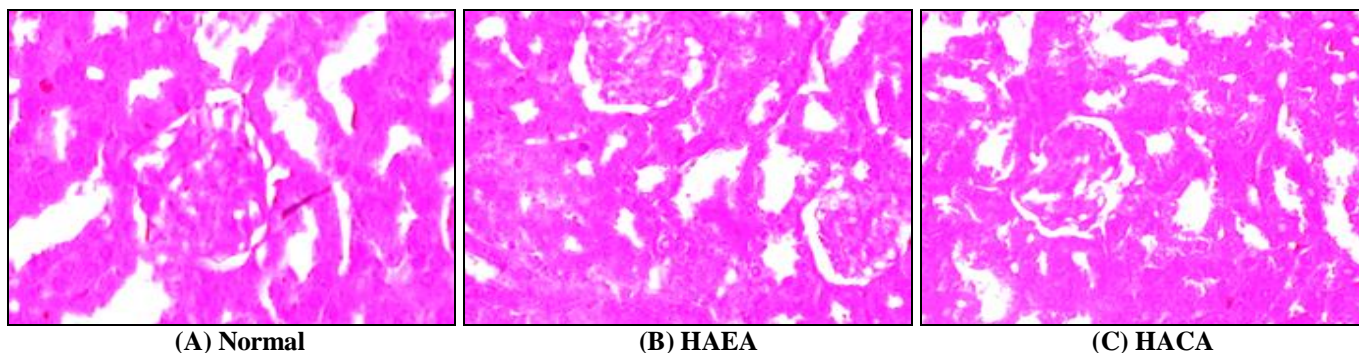


FIG. 1: HISTOPATHOLOGICAL SLIDES OF KIDNEY ORGAN SHOWN NO CHANGES IN SWISS ALBINO MICE TREATED WITH (B) HAEA & (C) HACA EXTRACTS

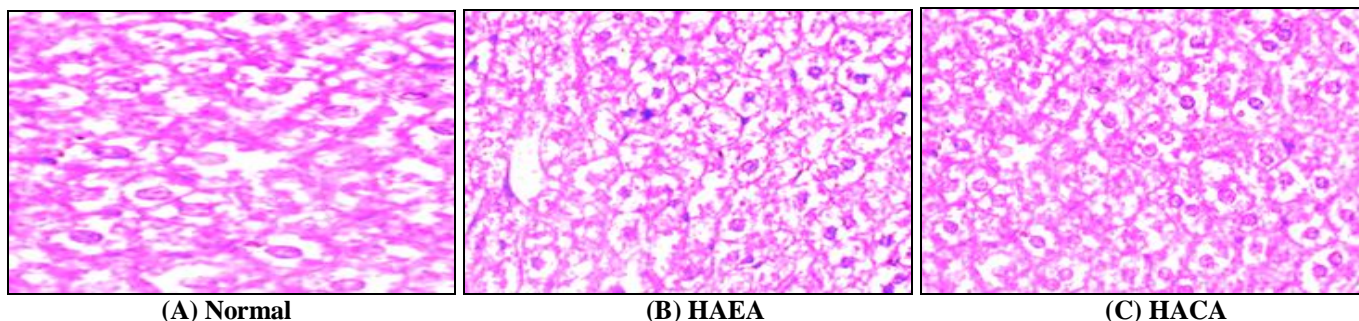


FIG. 2: HISTOPATHOLOGICAL SLIDES OF LIVER ORGAN SHOWN NO CHANGES IN SWISS ALBINO MICE TREATED WITH (B) HAEA & (C) HACA EXTRACTS

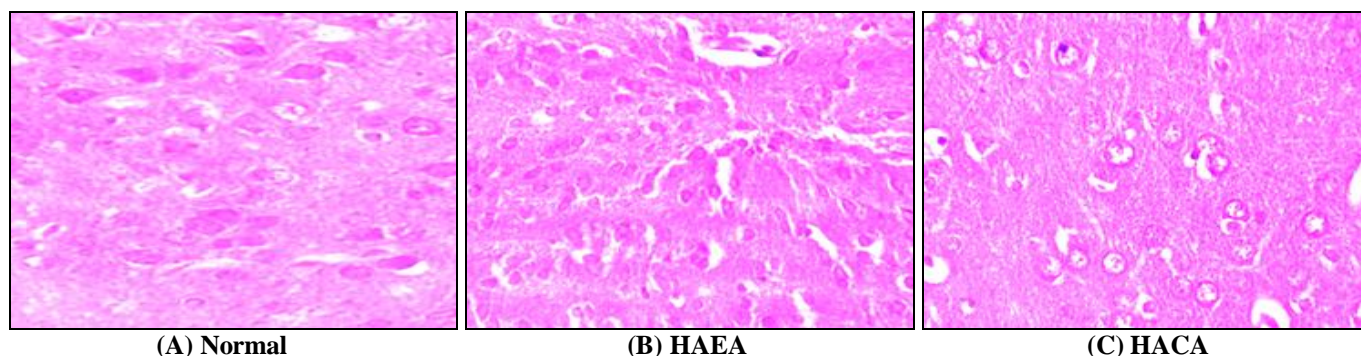


FIG. 3: HISTOPATHOLOGICAL SLIDES OF BRAIN ORGAN SHOWN NO CHANGES IN SWISS ALBINO MICE TREATED WITH (B) HAEA & (C) HACA EXTRACTS

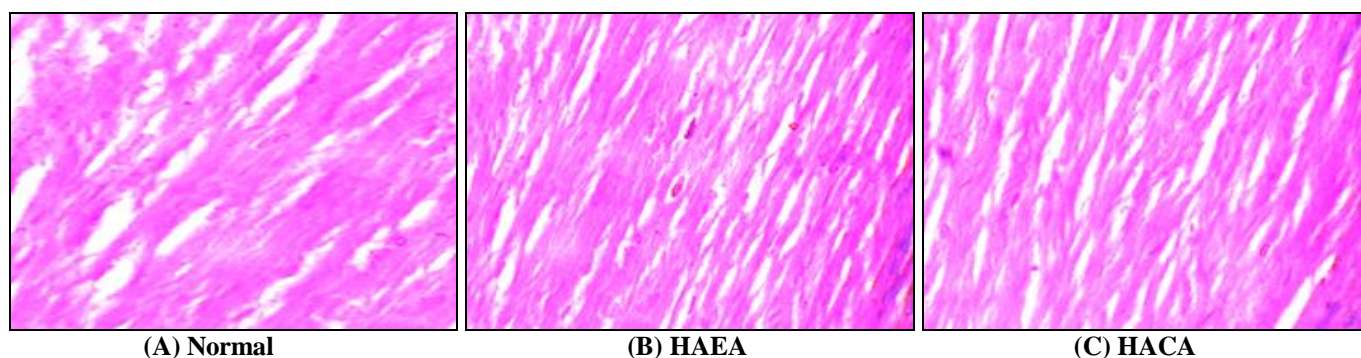


FIG. 4: HISTOPATHOLOGICAL SLIDES OF HEART ORGAN SHOWN NO CHANGES IN SWISS ALBINO MICE TREATED WITH (B) HAEA & (C) HACA EXTRACTS

DISCUSSION: Animal models are widely used to assess the preliminary toxicity because the early identification of side effects is usually predictive of the toxicity in humans and can save time, resources, and efforts ¹⁰.

In this study, several parameters evaluated after the *in-vivo* acute and sub-acute administration of hydro-alcoholic extracts from *E. alsinoides* & *C. asiatica*. In toxicological evaluation, mortality is an important criteria ¹¹, and there was no mortality seen in the both acute and sub-acute evaluation of extracts. For LD₅₀ no death was recorded in 72 h of administration of extracts. In acute toxicity, no death was recorded in 14 days extracts administration and in sub-acute toxicity study also no death recorded for 28 days extract administration. Clinical signs of toxicity were observed after the acute administration and during the sub-acute evaluation for all extract dosage.

It is known that several toxic compounds accumulate in the liver where the detoxification ¹² occurs. Liver damage is usually assessed by the determination of SGOT, SGPT, and alkaline phosphatase. It was not observed any significant alterations in serum levels of these three markers of

liver function after acute and sub-acute administration of *E. alsinoides* and *C. asiatica* extracts, and histopathological analysis of liver did not cause liver damage.

The kidneys receive about 25% of the cardiac blood flow, and any substance that reaches the systemic circulation will reach this organ. So these are considered to be frequent targets of toxicity ¹³. Renal function was evaluated by serum levels of urea, creatinine, and by histological analysis. The histopathological evaluation did not reveal alterations in this organ of any treated groups of sub-acute toxicity. Also, no tissue alterations found in the heart and brain of animals treated with 28 days *E. alsinoides* & *C. asiatica* extracts.

CONCLUSION: In this study, we had evaluated that *E. alsinoides* & *C. asiatica* extracts at different dosages cause no toxicity in signs in acute and sub-acute administration. Also, histopathology of kidney, liver, heart, and brain showed no alterations in tissues morphology. Since, the *E. alsinoides* & *C. asiatica* are already used in Indian traditional medicine as the neuroprotective agent and also found promising effects over inflammatory diseases, wound healing, immunomodulatory

activity and these data on the toxicity profile of *E. alsinoides* & *C. asiatica* will serve as a guide to future studies for these both medicinally important plants.

ACKNOWLEDGEMENT: The authors would like to thank the administrative in-charge Dr. Santosh Kumar Singh, senior scientist “Centre of Experimental Medicine & Surgery” for providing the well-equipped laboratory & animal house to conduct this study, also authors are thankful to the staff members of the CEMS for support in all aspects.

CONFLICT OF INTEREST: The authors declare that there is no conflict of interest.

REFERENCES:

1. Kumar MHV and Gupta YK: Effect of different extracts of *Centella asiatica* on cognition and markers of oxidative stress in rats. *Journal of Ethnopharmacology* 2002; 79(2): 253-60.
2. Pittella F, Dutra RC, Junior DD, Lopes MTP and Barbosa NR: Antioxidant and cytotoxic activities of *Centella asiatica* (L) Urb. *Int J Mol Sci* 2009; 10: 3713-21.
3. Orhan IE: *Centella asiatica* (L.) Urban: From traditional medicine to modern medicine with neuroprotective potential. *Evid Based Compl Altern Med* 2012; 1-8.
4. Bhandari P, Kumar N, Gupta AP, Singh B and Kaul VK: A rapid RP-HPTLC densitometry method for simultaneous determination of major flavonoids in important medicinal plants. *J Sep Sci* 2007; 30: 2092-96.
5. Govindan G, Sambandan TG, Govindan M, Sinskey A, Vanessendelft J, Adenan I and Rha CK: A bioactive polyacetylene compound isolated from *Centella asiatica*. *Planta Med* 2007; 73: 597-99.
6. Subban R, Veerkumar A, Manimaran R, Hashim KM and Balachandran I: Two new isoflavonoids from *Centella asiatica* (Linn.). *J Nat Med* 2008; 62: 369-73.
7. Lakshmi UMD and Reddy MN: Preliminary studies on anti-inflammatory, antipyretic & antidiarrhoeal properties of *Evolvulus alsinoides*. *Turk J Biol* 2011; 35(5): 611-18.
8. Ganju L, Karan D, Chanda S, Srivastava KK, Sawhney RC and Selvamurthy W: Immunomodulatory effects of agents of plant origin. *Biomed-Pharmacother* 2003; 57: 296-00.
9. Auddy B, Ferreira M and Blasina F: Screening of Antioxidant activity of some three Indian medicinal plants traditionally used for the management of neuro-degenerative diseases. *Journal of Ethnopharmacology* 2003; 84: 131-38.
10. Kramer JA, O'Neill E, Phillips ME, Bruce D, Smith T, Albright MM, Bellum S, Gopinatan S, Heydorn WE, Liu X, Nouraldeen A, Payne BJ, Read R, Vogel P, Yu XQ and Wilson AGE. Early toxicology signal generation in the mouse. *Toxicol Pathol* 2010; 38: 452-71.
11. Asare GA, Gyan B, Bugyei K, Adjei S, Mahama R, Addo P, Out-Nyarko L, Wiredu EK and Nyarko A: Toxicity potentials of the nutraceutical *Moringa oleifera* at supra-supplementation levels. *J Ethnopharmacol* 2012; 139: 265-72.
12. Clark EGC and Clark ML: *Veterinary toxicology*. Cassel and Collier Macmillian Publishers, London 1977.
13. Dekant W and Vamvakas S: Biotransformation and membrane transport in nephrotoxicity. *Crit Rev Toxicol* 1996; 26: 309-34.

How to cite this article:

Yadav MK, Singh SK, Singh M, Mishra SS, Singh AK, Tripathi JS and Tripathi YB: Comparative acute and sub-acute toxicity study of hydro-alcoholic extracts of *Centella asiatica* and *Evolvulus alsinoides* in swiss albino mice. *Int J Pharm Sci & Res* 2019; 10(10): 4694-99. doi: 10.13040/IJPSR.0975-8232.10(10).4694-99.

All © 2013 are reserved by International Journal of Pharmaceutical Sciences and Research. This Journal licensed under a Creative Commons Attribution-NonCommercial-ShareAlike 3.0 Unported License.

This article can be downloaded to **Android OS** based mobile. Scan QR Code using Code/Bar Scanner from your mobile. (Scanners are available on Google Play store)