



Received on 11 November, 2011; received in revised form 09 December, 2011; accepted 23 February, 2012

## ANESTHETIC POTENTIAL OF LIGNOCAINE / PRILOCAINE CREAM (EMLA) VERSUS LIGNOCAINE INFILTRATION FOR RADIOFREQUENCY ABLATION OF WARTS

S. Singh\*, R. Singh and J. P. Singh

Department of Pharmacology, Shri Ram Murti Smarak Institute of Medical Sciences, Bareilly- 243202, Uttar Pradesh, India

### ABSTRACT

**Keywords:**

EMLA,  
Lignocaine,  
Radiofrequency ablation,  
VAS score,  
warts

**Correspondence to Author:**

**Dr. Sujata Singh**

Assistant Professor, Department Of  
Pharmacology, SRMS IMS, Bareilly, Uttar  
Pradesh, India

The development of topical anesthetics can serve as a better alternative to infiltration anaesthesia for short dermatosurgical procedures. EMLA cream (eutectic mixture of local anesthetics), a topical local anesthetic cream has been shown to penetrate intact skin and provide analgesia of superficial layers. Very few comparative studies are available and therefore data regarding the efficacy and patient acceptability of EMLA over lignocaine infiltration are limited. So, with this background the present prospective study was planned to compare the efficacy, safety and patient acceptability of topical EMLA cream with lignocaine infiltration in patients undergoing radiofrequency ablation of warts from the intact skin of face and neck. A total of 40 volunteer patients with 10 – 15 warts present on face and neck were divided into two groups (group A and B), 20 patients in each group. Group A received lignocaine infiltration and group B received topical EMLA cream under occlusive dressing. The procedure was executed after 5 min of lignocaine infiltration and 30 min of EMLA application. Pain assessment was done using VAS (visual analogue score). Pain assessment was done both at the time of application and during the procedure. Extent of the pain was also assessed by the patient on a verbal rating. The results of the study show that lignocaine infiltration caused mild to moderate pain except one patient. On the other hand none of the patient experienced any type of pain on application of EMLA cream. The pain assessment during the anesthetics application, lignocaine infiltrated patients revealed significantly higher VAS score in comparison with the EMLA application ( $3.3 \pm 0.865$ ,  $0.0$ ;  $P < 0.001$ ). However, during the surgical procedure, EMLA applied patients experienced significantly higher VAS score in comparison with the lignocaine infiltrated patients ( $P < 0.05$ ). The patient acceptability to the EMLA application was found to be more in comparison with lignocaine. Adverse events were mild and comparable in both the groups. In conclusion EMLA is an efficacious alternative to lignocaine infiltration for radiofrequency ablation of warts and has better patient acceptability.

**INTRODUCTION:** Warts are benign tumors that commonly involve the skin and other epithelial tissues, caused by human papilloma virus infection<sup>1</sup>. Treatment of warts is difficult, though several treatment modalities are available. There is no single treatment that is 100% effective and different types of treatment may be combined<sup>2</sup>. Amongst many, surgical removal is one of the preferred options. In the present scenario, dermatosurgery and cosmetic dermatological procedures are being performed by increasing number of dermatologists.

Most of the dermatosurgeries, including radiofrequency ablation of warts, are performed in an outpatient setting and as day care surgeries, under local infiltration anesthesia. Radiofrequency ablation is a versatile dermatosurgical procedure used for the surgical management skin lesions by using various forms of alternating current at an ultra high frequency<sup>3</sup>.

Pain control associated with invasive procedures of the dermatosurgery and cosmetic dermatological procedures is a major concern. Local infiltration anesthesia in itself is quite feared procedure in dermatosurgery, probably due to pain during needle insertion. Elimination of the needle for local anesthesia would be an immense instigate in dermatosurgery. In this context, the development of topical anesthetics is commendable and has provided a superior alternative for anaesthetizing the intact skin.

EMLA cream is a FDA-approved topical anesthetic comprised of eutectic mixture of 2.5% lignocaine and 2.5% prilocaine that penetrates intact skin and allows topical and transdermal analgesia<sup>4</sup>. Its duration of action and depth of penetration depends upon the application time and dose. Topical application under occlusive dressing augments the analgesic potential of the EMLA cream. A comparable efficacy of EMLA cream to the lignocaine infiltration for removal of genital warts<sup>5</sup> and radial artery cannulation<sup>6</sup> has been demonstrated by the previous workers. Its satisfactory analgesic effect for thermocautery<sup>7</sup> or laser treatment<sup>8</sup> has also been demonstrated. However, comparative studies demonstrating the analgesic potential of topical EMLA cream and lignocaine infiltration for dermatosurgical removal of warts from intact skin are meager.

Thus, considering these facts present study was intended to compare the efficacy, safety and patient acceptability of topical EMLA cream with lignocaine infiltration in patients undergoing radiofrequency ablation of warts from the intact skin of face and neck.

**MATERIALS AND METHODS:** To evaluate the efficacy, safety and patient acceptability of topical EMLA cream with lignocaine infiltration, we performed a prospective observational study in patients undergoing radiofrequency ablation of warts from the face and neck. A total of 40 volunteer patients with 10-15 warts present on face and neck area participated in the study and were randomly enrolled into two groups (group A and B), 20 patients in each group. The patients of group A received lignocaine infiltration, while the patients of group B received topical EMLA cream under occlusive dressing. The radiofrequency ablation of warts was executed after 5 min of lignocaine infiltration and 30 min of EMLA application.

All the patients were apparently healthy except for the warts. None of the patient had received any treatment for wart for last 15 days and were not allergic to the amide-type of local anesthetics. There was no statistically significant difference in the patients of both the groups with respect to sex, age and site of the warts. The dermatosurgical procedure in each patient was completed within 15 min after start of the procedure.

**Assessment of Pain:** Pain associated during lignocaine infiltration and EMLA application was assessed by using a 10 cm visual analogue scale (VAS) with the end points of 0 cm rated as no pain and the points of 10 cm as intolerable pain. Extent of the pain was also assessed by the patient on a verbal rating of no pain, mild (quite tolerable), moderate (not quite tolerable), and severe pain (intolerable). Pain assessment during the radiofrequency ablation procedure was also judged in the similar mode. If surgery was interrupted due to pain, the pain assessment for the initial treatment was made before the administration of additional anesthetic.

**Assessment of Local Reactions:** The patients were asked about any local reaction or any other type of discomfort, before the start of the procedure and concomitantly the adverse events for instance, local

erythema and edema were also assessed by the physician. The reactions were rated as none, slight, moderate or profound. The presence of any other adverse reaction was also noticed.

**Statistical Analysis:** Comparisons between the groups were performed using the ANOVA and Post-Hoc Tukey's tests. The level of statistical significance for all the comparisons made was established at  $P \leq 0.05$ . All data were analyzed by means of the statistical package SPSS 15 (SPSS Sciences, Chicago, USA).

**RESULTS:** In the present study, we found that lignocaine infiltration caused mild to moderate pain except one patient. On the other hand none of the patient experienced any type of pain on application of EMLA cream (**Table 1**). Analgesia produced by EMLA was good and appeared comparable to the lignocaine infiltration.

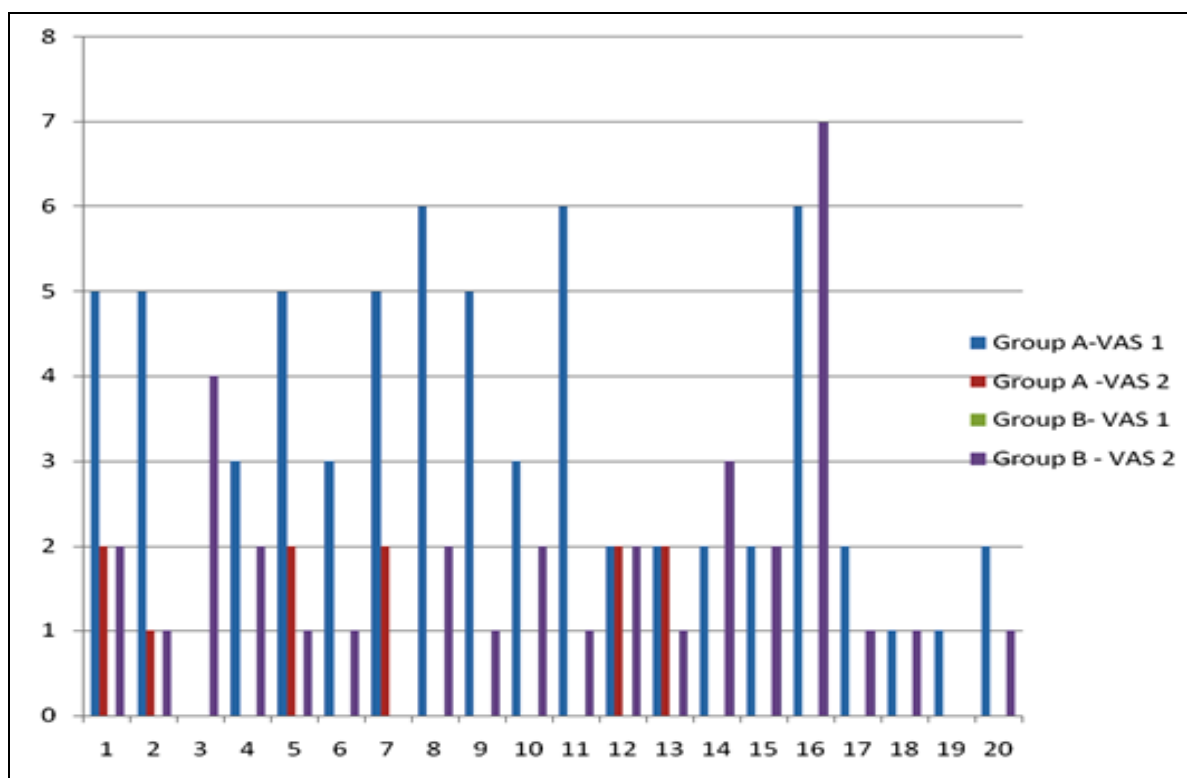
During the dermatosurgical procedure most of the patients of group B (EMLA) experienced mild pain

(75%). Two patients from this group had no pain while another two suffered moderate pains. In one patient the procedure was interrupted due to severe pain. EMLA cream was again applied under occlusive dressing and the same protocol was repeated. On the other hand, in group A (lignocaine infiltration), the procedure was painless in 65% patients and there was mild pain in the rest (Table 1).

The pain assessment (by VAS) during the anesthetics application, lignocaine infiltrated patients had significantly higher VAS score in comparison with the EMLA application ( $3.3 \pm 0.865$ ,  $0.0$ ;  $P < 0.001$ ) (Fig. 1). However, during the surgical procedure, EMLA applied patients demonstrated higher VAS score in comparison with the lignocaine infiltrated patients ( $1.75 \pm 0.517$ ,  $0.55 \pm 0.235$ ;  $P < 0.05$ ) (Fig. 1). It was also observed that the VAS score during lignocaine infiltration was higher than the VAS score during procedure in EMLA group ( $3.3 \pm 0.865$ ,  $1.75 \pm 0.517$ ;  $P < 0.05$ ).

**TABLE 1: VERBAL PAIN ASSESSMENT DURING ANAESTHETIC APPLICATION AND PROCEDURE**

Groups	During Application				During Procedure			
	None	Mild	Moderate	Severe	None	Mild	Moderate	Severe
Group A	1	11	8	0	13	7	0	0
Group B	20	0	0	0	2	15	2	1



**FIG. 1. INDIVIDUAL VAS SCORES (VAS 1- PAIN DURING APPLICATION; VAS 2- PAIN DURING PROCEDURE)**

Therefore the result demonstrates that although, anaesthetic potential of EMLA is less than lignocaine infiltration but still it was observed that the pain caused by procedure with EMLA application is less than the pain caused by lignocaine infiltration. The patient acceptability to the EMLA application was found to be more in comparison with lignocaine infiltration.

Adverse events were mild and comparable in both the groups. Erythema was seen in two patients and another two had burning sensation in EMLA group. Two patients of the lignocaine infiltration group exhibited mild edema.

**DISCUSSION:** EMLA cream has been shown to be effective in anaesthetising intact skin for superficial surgery although the researchers have noted pain when biopsy was taken or deeper tissue was approached but superficial skin incision was painfree<sup>9</sup>. The result of the present study has demonstrated that the EMLA cream has excellent patient's acceptability as well as comparable anesthetic activity to the lignocaine infiltration. The higher acceptability to EMLA cream by the patients might be due to elimination of needle fright during anesthetic application.

We found that the VAS score for pain assessment during lignocaine infiltration was almost comparable to the score of the EMLA group during surgical procedure. Some of the patients of lignocaine infiltration group also revealed pain during surgical procedure. This indicates that the patients of lignocaine infiltration group may have to experience the pain for two times (during infiltration as well as during surgical procedure). This might be another reason behind lower acceptability to lignocaine infiltration.

Previous scientific reports had demonstrated that the onset of analgesia on face skin was less than twenty five min after EMLA application under occlusive dressing<sup>10</sup>. The efficacy of EMLA is due to occlusive dressing which aids diffusion into the skin. EMLA forms a depot in the stratum corneum during occlusion which results in continued and even increase in analgesia 15 - 60 minutes after removal of the medication<sup>11, 12</sup>.

In a previous study it was shown that EMLA is a useful analgesic for laser treatment of portwine stains<sup>13</sup>. In dermatological procedures EMLA was found to be

effective in relieving pain associated with punch biopsies<sup>5</sup>. Our findings are in agreement to these reports.

However, in present study most of the patients have suffered mild pain during the surgical procedure even after 30 min of EMLA application under occlusive dressing. This signifies that a longer application time may reduce the percentage of patients experiencing mild pain during radiofrequency ablation of warts from face and neck skin. After 120 min of the EMLA cream application, more than 3mm in depth for the perception of pressure from needle insertion has been demonstrated by Bjerring and Arendt- Nielsen. Saxena *et al.*<sup>14</sup> have reported that EMLA cream is more effective anesthetic than lignocaine gel for intravenous cannulation and this may be the result of higher concentration of local anesthetics in EMLA cream (5%) as compared to lignocaine gel (2%)<sup>15</sup>.

In present study the lower but comparable anesthetic potential of the EMLA cream to lignocaine may be the result of its lower penetration on intact skin. Moreover we applied EMLA cream for 30 min before start of the surgical procedure, which might have not provided adequate concentration of EMLA for complete anesthetic effect on the intact skin. A longer application period of EMLA cream may enhance its anesthetic activity on intact skin. On the other hand for lignocaine, penetration was not an impediment for anesthetic activity as it was infiltrated.

In conclusion, EMLA is an efficacious, safe and a better alternative to lignocaine infiltration for radiofrequency ablation of warts and has higher patient acceptability. The number of patients in the present study is limited therefore additional, large-scale studies are needed to confirm the anesthetic efficacy of EMLA cream on intact skin.

**ACKNOWLEDGMENT:** The authors are thankful to the volunteer patients who have participated in the study.

#### REFERENCES:

1. Drake LA, Ceilley RI, Cornelison RL, Dobes WL, Dorner W, Goltz RW, *et al.* Guidelines of care for warts: Human papilloma viruses. *J Am Acad Dermatol* 1995; 32: 98-103.
2. V Shivakumar, Rajendra Okade, V Rajkumar. Autoimplantation therapy for multiple warts. *IJDVL* 2009; 75: 593-595.
3. Silonie Sachdeva, Alka Dogra. Radiofrequency ablation in dermatology. *Indian j of dermatology* 2007; 52(3): 134-137.

4. Neal D. Kravitz, DMD, MS. The use of compound topical anesthetics. *Journal of American dental association* 2007; 138: 1335-1339.
5. Gerdien M Berg, Stefan Lillieborg, Ernst Stolz. Lidocaine/prilocaine cream (EMLA) versus infiltration anaesthesia: a comparison of the analgesic efficacy for punch biopsy and electrocoagulation of genital warts in men. *Genitourinary medicine* 1992; 68: 162-165.
6. Joly L Spaulding C, Monchi M, Ali OS, Weber S, Benhamou D. Topical lignocaine- prilocaine cream (EMLA) versus local infiltration anaesthesia for radial artery cannulation . *Anaesth Analg* 1998; 87: 400-402.
7. Ljunghall K, Lillieborg S. Local anaesthesia with a lidocaine/prilocaine cream (EMLA) for cautery of condylomata acuminata on the vulval mucosa. The effect of timing of application of the cream. *Acta Derm Venereol.* 1989; 69(4): 362-365.
8. Rylander E, Sjöberg I, Lillieborg S, Stockman O. Local anesthesia of the genital mucosa with a lidocaine/prilocaine cream (EMLA) for laser treatment of condylomata acuminata: a placebo-controlled study. *Obstet Gynecol.* 1990; 75(2): 302-306.
9. Juhlin L, Evers H & Broberg F. A lidocaine- prilocaine cream for superficial skin surgery and painful leisons. *Acta Dermato Venerologica* (Stockholm). 1980; 60: 544-546.
10. Holmes HS. Choosing a local anesthetic. *Dermatol Clin.* 1994; 12: 817-822.
11. Arendt-Nielsen L, Bjerring P. Laser-induced pain for evaluation of local analgesia. *Anesth Analg.* 1988; 67: 115-123.
12. Evers H, Von Dardel O, Juhlin L, et al. Dermal effects of compositions based on the eutectic mixture of lignocaine and prilocaine (EMLA). *Br J Anaesth.* 1985; 57: 997-1005.
13. Tan OT, Stafford T I. EMLA for treatment of portwine stain in children. *Laser Surg Med* 1992; 12: 543-548.
14. Bierrina P, Arnendt- Nielson L. Depth and Duration of skin analgesia to needle insertion after topical application of EMLA cream. *Br J Anaesth* 1990; 64: 173-177.
15. Saxena KN, Dua CK, Taneja B. A comparative Evaluation of lignocaine gel versus EMLA cream for painfree iv cannulation. *J Anaesth Clin Pharmacol* 2004; 20 (3): 279-282.

\*\*\*\*\*